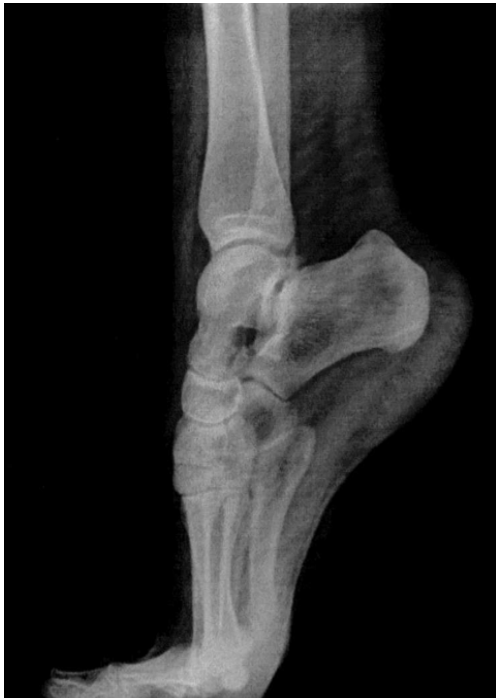



**The Point of Being
“En Pointe”, p60**

Literature Review of Sever’s Disease: Radiographic Diagnosis and Treatment

Heather Leeb, BA and Elizabeth Stickel, BS

4

Reversible Diabetic Neuropathy: A Systematic Approach to Understanding Diabetic Neuropathy and Roads to its Reversibility

Faysal E. Siddiqui, BS

10

The Risk Factors for Stress Fractures: A Systematic Review of Recent Literature

Jacqueline L. Prevete, BS and Tyler J. Silverman, BA

19

Literature Review of Metatarsus Adductus in Children

Anshini Dalal, BS, Ana Pimentel-Tejeda, BS, and Alex Kim, MS

24

Bisphenol A and its Contributions to the Onset of Diabetes Mellitus

Jonathan R. Roy, MS, Cailin N. Rubino, BS, Todd M. Chappell, BA

30

Complications of Ambulating on an Elevated Heel: A Literature Review

Kristin Visco, BS and Keleigh Muxlow, BS

36

Diagnosis and Management of a Navicular-Medial Cuneiform Coalition: A Case Report

Christopher L. Lovell, BA and Adisa Mujkic, BA

39

Off-loading the Diabetic Foot for Ulcer Treatment

JiSun Lee, MS and Poovasit Klinoubol, BS

44

Tenosynovitis of the Lower Extremity: A Systemic Review

Javeria Hussaini, BA, Hanya Almudallal, BA, Jonathan R. Roy, MS, and Gabriel Lopez-Ross, BA

49

Bilateral Tarsal Tunnel Syndrome as a Sequela of Bilateral Clubfoot Surgery: A Case Report

Chioma Odukwe, MS

56

The Point of Being “En Pointe”: Biomechanical Stresses and Injury in Classically Trained Ballet Dancers

Ilya Shnitser, BA and Alicia Attanasio, MS

60

Short-Term Efficacy of Stretching in Conjunction with Other Conservative Treatments for Plantar Fasciitis

Kunal Amin, BS, Mina Hanna, BA, Pooya Lashkari, BA, and Jalpen Patel, BS

68

Investigations in the Use of Grafts for Treatment of the Chronic Diabetic Wound

Angel Colandrea, BS and Tammer Elmarsafi, BS

74

Members of the Editorial Board

NYCPM Podiatric Medical Review 2011-2012

Editor-in-Chief

Adisa Mujkic, BA

Faculty Advisors

Anthony D'Antoni, DC, PhD
Khurram Khan, DPM
Anthony Iorio, DPM

Student Reviewers

Alicia Attanasio, MS
Christopher L. Lovell, BA
Jacqueline L. Prevete, BS
Jonathan R. Roy, MS
Ilya Shnitser, BA

Clinician Reviewers

Nicholas Argerakis, DPM
Anthony D'Antoni, DC, PhD
Kristina Karlic, DPM
Khurram Khan, DPM
Jose Loor, DPM
Laurence Lowy, DPM
Barbara Resseque, DPM
Susan Rice, DPM
Greg Taylor, PT
Thomas Vitale, DPM

Peer Review

The incorporation of peer review into this publication of NYCPM's *Podiatric Medical Review* has been the cornerstone of ensuring that manuscripts were held to their highest standards. Peer review was conducted with the aim of enhancing the quality of each manuscript and gave students the opportunity to engage in the peer review process, which included a review by a third-year student and clinician. Some reviews required additional input from basic scientists. Manuscripts were systematically reviewed for format, content, appropriateness for the scope of the journal, and overall quality.

Authors were given the opportunity to revise their original manuscripts based on reviewer comments and suggestions that were submitted to the Editor-in-Chief. Authors were asked to grade their manuscripts according to CEBM's 2011 *Levels of Evidence*.¹ Upon revision, the Editor-in-Chief assessed all manuscripts for final publication.

1. Jeremy Howick. "The Oxford 2011 Levels of Evidence". Oxford Centre for Evidence-Based Medicine.
<http://www.cebm.net/index.aspx?o=5653>

Podiatric Medical Review 2011-2012



Dear Readers of the NYCPM *Podiatric Medical Review*,

It is with great pleasure that I take this opportunity to congratulate Adisa Mujkic, Class of 2013, Editor-in-Chief of the NYCPM *Podiatric Medical Review*, along with her editorial staff and all those who contributed articles to the *Review*. This publication last appeared in 2005, and it is a tribute to the dedication and hard work of all who were involved in its preparation that it is once again available as a journal that offers student-written literature reviews, case reports, and original research.

The NYCPM *Podiatric Medical Review* affords our students an opportunity to challenge themselves to seek out novel research and explore topics within podiatry that are of particular interest. The laudable goal of the publication is to steer students towards research, and to get students comfortable with approaching and analyzing medical literary works. Furthermore, learning the process of peer-reviewed scientific writing enhances the education at NYCPM and helps to create well-rounded future clinicians.

The NYCPM *Podiatric Medical Review* will reach a wide audience. It is being distributed to podiatric residency programs and to all the other schools of podiatric medicine. The *Review* is a testament to the kind of outstanding work our students are capable of. I again offer my congratulations to all who have been involved in its publication.

Sincerely,

Louis L. Levine
President & CEO
New York College of Podiatric Medicine

Letter from the Editor



Dear Fellow Students and Future Colleagues,

The tale of the revival of NYCPM's *Podiatric Medical Review* begins one year ago when NYCPMSA past president, Jay Bhuta, approached the student body searching for interest in this undertaking. Along with Jackie, Christopher, Ilya, Alicia, and Jonathan, I set out on this venture because of my love for writing and because I view research and the sharing of it as the essence of academia.

I wanted to give students the opportunity to realize the richness of our medical literature and within that richness the vast possibilities for improvement and future research. The incorporation of a structured peer review was to provide a new level of quality and sophistication. I am indebted to all the clinicians and students that took on this task with me, as this was no small feat.

Rallying student interest, holding writing workshops, and conducting peer review has truly been a journey that would not have been possible was it not for the unwavering dedication of my Editorial Board. I am grateful for the guidance of my faculty advisors, Dr. D'Antoni, Dr. Khan, and Dr. Iorio, whose enthusiasm and commitment to research are unparalleled. I would like to thank Linda Chusuei for all of her insight and advice on the many aspects of publishing. A dear thank-you is dedicated to Dr. Laurence Lowy, whose encouragement kept my spirits high and outlook optimistic throughout the windy path of reviving PMR.

Lastly, I would like to thank the authors who chose to tackle the challenge of research with hard work, persistence, and patience. I hope that I have done justice in representing all of your endless efforts. I wish you success as you continue to contribute in such remarkable ways to our profession.

My sincere hope is that this publication continues and serves as a source of encouragement for all interested in the limitless possibilities of research. Congratulations to all of the authors for producing such spectacular manuscripts and congratulations to my Editorial Board for seeing that this year's publication of PMR come to fruition. For the reader, I hope that this publication broadens your knowledge of podiatric medicine and inspires you to continue exploring the breadth of medical discoveries.

Sincerely,

Adisa Mujkic
Editor-in-Chief

Literature Review of Sever's Disease: Radiographic Diagnosis and Treatment

Heather Leeb, BA and Elizabeth Stickel, BS

Abstract

Introduction:

The purpose of this study is to review the current radiographic diagnosis and treatment options for patients with Sever's disease (calcaneal apophysitis).

Study Design:

Qualitative Systematic Review of the Literature

Methods:

The authors searched Ovid and PubMed databases using the keywords 'Sever's disease,' 'calcaneal apophysitis,' and 'apophysitis.' MesH terms were 'calcaneus' and 'heel.' The searches returned 458 results, of which 29 articles were selected for inclusion. The authors reviewed articles published after the most recent literature review on Sever's disease, which was published in 2008. Articles published between June 2008 and December 2011 which address the diagnosis and treatment of Sever's disease were included in the review, while articles not relevant to these topics were excluded.

Results:

The authors found that there are multiple treatment plans available, but no gold standard of care in the diagnosis and treatment of Sever's disease.

Conclusions:

More studies are needed to provide proper data for physicians to best diagnose patients with Sever's disease and avoid misdiagnoses. Preferable studies to be performed include randomized clinical trials and quantitative systematic reviews since the literature does not contain a substantial amount of these formats.

Key Words: Sever's Disease, calcaneal apophysitis

Level of Evidence: 4

Introduction

The purpose of this study is to review the current literature on the radiographic diagnosis and treatment of Sever's disease, a condition first described a century ago.¹ Sever's disease, or calcaneal apophysitis, is an inflammation of the cartilaginous growth center upon which the calcaneal tendon inserts.^{2,3} More specifically, it is a traction epiphysitis^{4,5} characterized by a dull, achy pain located on the posterior and plantar aspects of the heel.^{6,7} Figure 1 depicts the common location of pain associated with Sever's disease. This condition is most commonly classified as an overuse injury in pediatric patients.⁶ It occurs in children during growth at the calcaneal epiphysis, between 5 to 13 years in girls and 7 to 15 years in boys.⁸

There are many potential causes of heel pain, including mechanical, neurologic, arthritic, and traumatic etiologies.⁹ Sever's disease is considered a common cause of heel pain in children. It comprises 2% to 16% of musculoskeletal injuries⁸ and between 16.3% and 22.7% of exertion injuries in children.^{10,11} Correctly identifying the source of the pediatric heel pain as Sever's disease is important for the course of treatment that should be followed.

The etiology of Sever's disease is controversial. It has been suggested that repetitive microtrauma during sporting activities leads to inflammation and pain.⁷ Other theories suggest that Sever's disease may be related to the percentage of body weight supported by the heel in affected patients or the presence of gastrocnemius equinus.^{7,12} There is also a possible correlation with a higher plantar pressure at the heel. Becerro et al's¹² case-control study found that high plantar pressures and gastrocnemius equinus are associated with Sever's disease. However, a case-control study by Scharfbillig et al⁸ suggested that forefoot and rearfoot malalignment are more strongly correlated with Sever's disease than are weight, activity, and limited ankle dorsiflexion. These conflicting findings make diagnosis and treatment more difficult, as physicians must still consider numerous factors as potential etiologies of Sever's disease.

Physicians originally believed that the diagnosis of Sever's disease through radiographic anatomy was not possible. Calcaneal apophysitis is most often diagnosed clinically, and radiographic evaluation is believed to be unnecessary by many physicians.¹³ In early radiologic studies, the increased density of



the apophysis has been emphasized as a characteristic feature of calcaneal apophysitis, but these studies were based on the subjective observations of the investigators.¹⁴ More recent studies using magnetic resonance imaging (MRI) have displayed that one can observe change in the calcaneal apophysis throughout the treatment of Sever's disease.^{3,15} Additionally, MRI has been used in patients whose pain continued after conservative treatment to locate different or additional sources of heel pain.^{3,15}

Once diagnosed, Sever's must be appropriately treated to limit negative consequences. Although Sever's is self-limiting and typically resolves with conservative treatment, recent studies have shown that there are potential negative effects of untreated cases, including avulsion fractures¹⁶ and diminished quality of life.¹⁷ While some physicians are now realizing the importance of treating this condition, they are met with literature expressing conflicting opinions. The proper treatment of Sever's disease has long been a source of debate⁶, for which a wide array of options have been suggested.

Scharfbillig et al's¹⁸ summarization of the numerous proposed treatment options reveals why the management of Sever's may be a rather daunting task for a physician. Even more concerning is that there is no definitive best treatment option, as the majority of evidence published prior to 2008 supporting any particular treatment was opinion-based or retrospective case series.¹⁸ Given the ambiguity in the diagnosis and treatment of Sever's disease, it is necessary to review the most recent literature involving scientific research to hone in on the most useful techniques.

Methods

Two authors conducted independent online database searches of Ovid and PubMed using the keywords 'Sever's disease,' 'calcaneal apophysitis,' and 'apophysitis.' Mesh terms were 'calcaneus' and 'heel.' Language limits were set to English only. The searches returned 458 results, of which 29 articles were selected. The authors reviewed articles published after the most recent literature review on Sever's disease.¹⁸ Results were limited to articles published between June 2008 and December 2011. Articles included and analyzed in this review were related to the radiographic diagnosis and treatment of Sever's disease. Articles excluded were not relevant to the diagnosis and treatment of Sever's disease.

Results

The lack of available clinical evidence in the form of randomized clinical trials makes it impossible to give objective results regarding the treatment and diagnosis of Sever's disease. The majority of information stated in the current literature is a compilation of case studies or case series with researchers giving their opinions on what comprises the best method of diagnosis and treatment.

Discussion

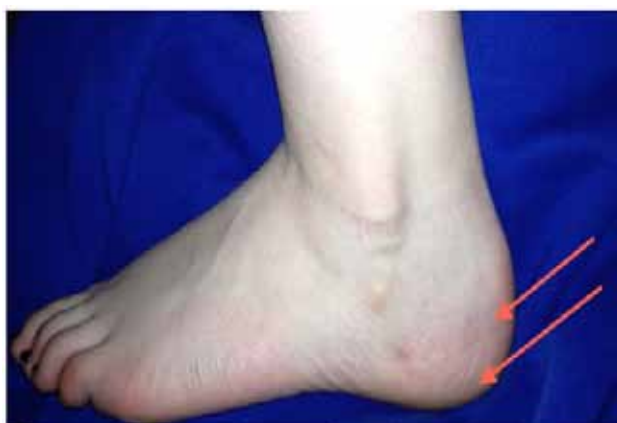

Figure 1. Arrows indicate where pain presents in Sever's disease, on the posterior and plantar heel.

Diagnosis

Calcaneal apophysitis is considered the most common cause of heel pain in children. It is critical to correctly diagnose this condition and rule out others. Individuals susceptible to Sever's disease include boys between the ages of 10 and 12 years, and girls between the ages of 8 and 10 years.¹⁹ Children in this age group that are more susceptible may have the risk factors listed in Table 1. Based on a newer study,⁸ children with forefoot and rearfoot malalignments may also display increased susceptibility. Upon presentation, these children may have a chief complaint of an antalgic gait including limping, tiptoeing, or walking on the outside of the foot.⁶

Traditionally, physicians have used clinical findings to make the diagnosis of Sever's disease. The patient's history and precise location of maximal tenderness are used to differentiate Sever's disease from other posterior heel pain problems.^{18,19, 20, 21} Additionally, non-diagnostic radiographs can be evaluated to verify the diagnosis and rule out other conditions. However, there still exists controversy regarding interpretation and usefulness of radiographs related to Sever's disease. Three recent studies^{13,14,22} attempted to

address the debate over whether or not radiographs can be used as reliable diagnostic tools for identifying Sever's disease.

A recent prospective study¹³ analyzed anteroposterior and lateral weight-bearing foot radiographs of 61 patients diagnosed with calcaneal apophysitis. The radiographs altered the diagnosis of only one patient. The author concluded that because neither sclerosis nor fragmentation of the apophysis could be used to establish the diagnosis of calcaneal apophysitis, using radiographs as the primary diagnostic tool is not useful.

A similar study conducted by Kose et al¹⁴ analyzed the inter-observer and intra-observer reliability of diagnosing Sever's using only radiographs, with increased sclerosis and fragmentation of the calcaneal apophysis as diagnostic criteria. Based upon their findings on inter-observer agreement and intra-observer reproducibility, the authors concluded that assessment of bone density on plain radiography is subjective and thus is an unreliable indicator. It was also noted that fragmentation is a normal variant related to growth. Therefore, neither sclerosis nor fragmentation are validated findings which should be used to diagnose Sever's. Ultimately, this study found that radiographic evidence neither excludes nor supports the diagnosis of Sever's, and as such, radiographic assessment is unnecessary.

While it is not surprising that two studies conducted by the same author came to the same conclusion, a third recent study²² opposes these findings and instead suggests that plain film radiography is in fact important when assessing cases of clinically diagnosed calcaneal apophysitis. This retrospective case study, by Rachel et al,²² found that radiographs altered the diagnosis and management of 5.1% of patients, leading to more aggressive treatment. These results are in contrast to the findings of Kose¹³ that radiographic evidence altered diagnosis in only 1.4% of the patients evaluated. Furthermore, Rachel et al²² suggested that lateral radiographs should be used to assess a diagnosis of Sever's and rule out other conditions, but that additional orthogonal views are unnecessary. The study emphasized that if a diagnosis is made without obtaining radiographs, a lesion requiring more aggressive treatment could be missed. According to Rachel et al,²² routine radiographic evaluation of the calcaneus in children diagnosed with calcaneal apophysitis is common in many pediatric orthopedic practices. Despite the lack of studies on abnormal findings and

concerns about radiation exposure of the patient, these evaluations are conducted to rule out other potential causes of pediatric heel pain, such as stress fractures or bone cysts.

Jung et al²³ provided two case reports in which the patients were treated with a Sever's disease regimen but actually had calcaneal apophyseal fractures. The patients were a 12-year-old female gymnast and a 13-year-old male gymnast. These patients showed no abnormal findings on radiographs, but presented with pain typical of Sever's disease. After resting and icing appeared to solve the problem, they both returned to their activities, only to again develop pain when active. Upon MRI evaluation during the second course of diagnosis, avulsion fracture of the calcaneus was discovered, rather than evidence of Sever's disease. This misdiagnosis using radiographs led to inappropriate treatment regimens.

Arnaiz et al¹⁵ state that while radiographs are non-specific and unnecessary for patients with clinical evidence of apophysitis, MRI is useful in atypical cases or for patients who do not respond to conservative therapy. In apophysitis, MRI findings include a widening of the apophysis. There is also increased signal intensity on T2-weighted images in the apophysis, underlying bone marrow, and adjacent soft tissue. Arnaiz et al recommend conducting MRI evaluation in the axial plane and either the sagittal or coronal plane. Additionally, they suggest using a combination of T1-weighted and T2-weighted sequences.¹⁵

While the use of radiographic evaluation remains controversial, and MRI for calcaneal apophysitis is rare, another mode of diagnosis has been recently investigated by Hazany et al.²⁴ The authors acknowledge limitations of radiographs and suggest the use of bone scans as an alternative diagnostic method for cases of pediatric heel pain in which clinical evaluation and radiography don't provide a clear diagnosis. This method of diagnosis is often used in adults, but rarely has been used in the pediatric population. Analysis of 49 cases of pediatric foot pain of unclear etiology revealed that bone scans were diagnostically useful in 77.6% of cases. The bone scans helped establish new diagnoses and directed the treatment in 63% of cases. Bone scans identified one case of early Sever's disease that had been missed on initial plain radiography.²⁴ This study provides only minimal evidence that bone scans may be useful in diagnosing Sever's disease. Additionally, bone scans may be inferior to other imaging techniques for diagnosing bone pathology around growth plates,²⁴ a key area for

examination in Sever's disease. As such, it remains unclear whether there is any benefit to using bone scans for assessing children with symptoms of Sever's disease.

Table 1. Proposed Risk Factors for Sever's Disease

High activity level

Scharfbillig et al¹⁸

Clemow et al¹⁹

Improper footwear

Clemow et al¹⁹

Running on hard surfaces

Clemow et al¹⁹

Overweight

Sever¹

Scharfbillig et al¹⁸

High plantar heel pressure

Becerro et al¹²

Gastrocnemius equinus

Becerro et al¹²

Scharfbillig et al⁸

Biomechanical deformity

Scharfbillig et al⁸

Micheli and Ireland²⁵

Treatment

Although there is no general consensus on diagnostic protocol aside from clinical evaluation, Sever's disease must be treated when identified. Unsurprisingly, just as opinions on appropriate diagnostic tools vary, so too do opinions on appropriate treatment. Widely accepted as a self-limiting condition,^{19,21,25} symptoms of Sever's resolve upon fusion of the calcaneal apophysis,²¹ which is around 14 in girls and 16 in boys.^{4,6} Before this fusion occurs, however, a patient may experience a reduced quality of life¹⁷ due to pain or avulsion fractures.¹⁶ Thus, it is important to treat Sever's to alleviate pain and prevent complications^{7,21} so that children may return to normal daily activities.

The major course of treatment most recently described in the literature is considered self-management, which includes rest from sports^{7,16,19,20} and avoidance of walking barefoot.⁷ Included in the current conservative treatment guidelines are icing the heel and anti-inflammatory medicine for pain.^{7,16,19} Rehbock⁷ states that icing should be in the area of pain for 10 minutes, 2 to 3 times per day until pain

subsides. Typically, symptoms resolve within 2 weeks to 2 months of initiating conservative treatment.¹⁶

Immobilization of the lower leg and foot with a cast in cases of severe injury and pain has also been indicated.⁷ The exact conditions that are so severe as to require casting are not specifically stated in Rhebock's⁷ article. However, not all physicians agree on when or even if it is necessary to cast. For example, Chiodo and Cook⁶ prefer to use a CAM walker and implement partial weight bearing for 2 weeks. A completely different method is preferred by Toomey,²⁰ who describes the use of silicone heel cups to treat Sever's disease. Toomey advises patients to wear the heel cup for two months on both the affected and non-affected heels to avoid complaints due to leg length inequality. The use of heel lifts and gel heel cups is also suggested by Clemow et al.,¹⁹ while orthotics may be used for flat feet to control foot function.⁷

Recently, a series of studies examined the efficacy of insoles in relieving pain associated with Sever's disease.^{26,27,28} The first study²⁶ demonstrated that two types of insoles, heel pads and heel cups, provide pain relief while allowing boys to maintain their normal activity level. The second study,²⁷ a randomized crossover study, revealed that heel cups were preferred over heel pads by more than 75% of the participants. The third study²⁸ then displayed that the heel cups improved heel pad thickness and reduced heel peak pressure, thereby alleviating pain. Overall, these studies provide more reliable evidence supporting the use of heel cups than have past articles^{19,20} describing personal preferences and clinical experiences.

Once symptoms have resolved, several physicians suggest a stretching protocol.^{6,7} Clemow et al¹⁹ describe the treatment plan as a stretching program with heel lifts. However, Rhebock⁷ states that heel lifts should not be started until the calcaneal apophysitis has fully healed. A current treatment involves stretching and elongation of the gastrocnemius-soleal complex.^{6,29} Chiodo and Cook⁶ recommend stretching 3 to 5 times per day, holding each stretch for 10 seconds. The stretching includes passive dorsiflexion at the ankle using a towel, belt, or band while sitting with the knee extended. Additionally, they suggest calcaneal tendon and calf stretches while leaning against a wall with the heel on the ground.⁶ After symptoms have resolved, the physician must assess whether the use of orthotics and modification of athletic shoe gear is necessary.⁶

While all of these methods have been suggested by individual physicians, our review found only minimal quantitative literature regarding the effectiveness of these treatments, and no comparative studies exist to illuminate which methods work most effectively. The current evidence for treatment of Sever's remains heavily based on opinion and clinical experience.

Conclusion

Clearly, there is still much to be learned regarding the radiographic diagnosis and treatment of Sever's disease. The contrasting findings on radiographic evidence and the limited number of recent studies suggests further investigation is necessary to properly determine the most useful diagnostic tools. Additionally, studies focusing on the use of bone scans specifically for the diagnosis of Sever's will more clearly determine whether this is a valid method that could be used in the future.

It is important that physicians come to a better consensus regarding diagnostic methods, as Sever's disease has been shown to diminish quality of life¹⁷ and potentially cause avulsion fractures.¹⁶ Proper diagnosis and treatment are critical to limiting pain and preventing complications caused by this condition. Yet, there is still no "gold standard" of care, and the current approaches to treatment vary widely and are based primarily on opinion rather than reliable clinical trials. Therefore, further research is justified in the form of randomized clinical trials in order to determine which treatments are most successful at alleviating pain caused by Sever's disease.

Author's Contributions

HL conceived the topic and design of the study, independently performed a literature search, drafted the methods, discussion, and conclusion sections of the narrative review, and participated in adding information to the abstract and introduction. ES performed an independent literature search, participated in the design of the study, drafted the abstract and introduction to the narrative review, and participated in adding additional information to the methods and discussion section. Both authors read and approved the final manuscript.

Statement of Competing Interests

The authors declare that they have no competing interests.

References

1. Sever JW. Apophysitis of the os calcis. *NY State J Med.* 1912;95:1025-1029.
2. Peck DM. Apophyseal injuries in the young athlete. *Am Fam Physician.* 1995;51(8):1891-5,1897-1898.
3. Ogden JA, Ganey TM, Hill JD, Jaakkola JI. Sever's Injury: a stress fracture of the calcaneal metaphysis. *J Pediatr Orthop.* 2004;24(5):488-492.
4. Kvist MH, Heinonen OJ. Calcaneal apophysitis (Sever's disease): A common cause of heel pain in young athletes. *Scand J Med Sci Sports.* 1991;1(4):235-238.
5. Kim CW, Shea K, Chambers HG. Heel pain in children: diagnosis and treatment. *J Am Podiatr Med Assoc.* 1999;89(2):67-74.
6. Chiodo WA, Cook KD. Pediatric Heel Pain. *Clin Podiatr Med Surg.* 2010;21(3):355-67.
7. Rehbock DS. Some of the more common biomechanical and orthopaedic foot conditions that are treated by the podiatrist. *S Afr Pharm J.* 2009;76(3):35-42.
8. Scharfbillig RW, Jones S, Scutter S. Sever's disease: a prospective study of risk factors. *J Am Podiatr Med Assoc.* 2011;101(2):133-45.
9. Thomas JL, Christensen JC, Kravitz SR, et al. The diagnosis and treatment of heel pain: a clinical practice guideline revision 2010. *J Foot Ankle Surg.* 2010;49(3)(suppl 3):S1-19.
10. Orava, S, Puranen J. Exertion injuries in adolescent athletes. *Br J Sports Med.* 1978;12(1):4-10.
11. Orava, S, Virtanen K. Osteochondroses in athletes. *Br J Sports Med.* 1982;16(3):161-8.
12. Becerro de Bengoa Vallejo R, Losa Iglesias ME, Rodriguez Sanz D, et al. Plantar pressures in children with and without sever's disease. *J Am Podiatr Med Assoc.* 2011;101(1):17-24.
13. Kose O. Do we really need radiographic assessment for the diagnosis of non-specific heel pain (calcaneal apophysitis) in children? *Skeletal Radiol.* 2010;39(4):359-361.
14. Kose O, Celiktas M, Yigit S, Kisin B. Can we make a diagnosis with radiographic examination alone in calcaneal apophysitis (Sever's disease)? *J Pediatr Orthop B.* 2010;19(5):396-398.
15. Arnaiz J, Piedra T, de Lucas EM, et al. Imaging findings of lower limb apophysitis. *AJR.* 2011;196(3):W316-25.
16. Lee KT, Young KW, Park YU, et al. Neglected Sever's disease as a cause of calcaneal apophyseal avulsion fracture: case report. *Foot Ankle Int.* 2010;31(8):725-8.
17. Scharfbillig RW, Jones S, Scutter S. Sever's disease – does it effect quality of life? *The Foot.* 2009;19(1):36-43.
18. Scharfbillig RW, Jones S, Scutter SD. Sever's disease: what does the literature really tell us? *J Am Podiatr Med Assoc.* 2008;98(3):212-223.
19. Clemow C, Pope B, Woodall HE. Tools to speed your heel pain diagnosis: Quickly zero in on a diagnosis by using our handy "photo guide" and reference table. *J Fam Pract.* 2008;57(11):714-721.
20. Toomey EP. Plantar Heel Pain. *Foot Ankle Clin.* 2009; 14(2):229-45.
21. Hendrix CL. Calcaneal Apophysitis (Sever Disease). *Clin Podiatr Med Surg.* 2005; 22(1):55-62.
22. Rachel J, Williams JB, Sawyer JR, et al. Is Radiographic evaluation necessary in children with a clinical diagnosis of calcaneal apophysitis (Sever disease)? *J Pediatr Orthop.* 2011;31(5):548-550.
23. Jung ST, Cho SB, Kim MS, et al. Calcaneal Apophyseal fractures in young athletes: a case report. *J Pediatr Orthop B.* 2008;17(1):11-14.
24. Hazany SJ, Bader SR, Hazany D, et al. Use of radioisotope bone scans in children with obscure foot pain. *J Pediatr Orthop B.* 2011;20(4): 252-256.
25. Micheli LJ, Ireland ML. Prevention and management of calcaneal apophysitis in children: an overuse syndrome. *J Pediatr Orthop.* 1987;7(1):34-8.

26. Perhamre S, Janson S, Norlin R, Klässbo M. Sever's injury: treatment with insoles provides effective pain relief. *Scand J Med Sci Sports*. 2011;21(6):819-23.
27. Perhamre S, Lundin F, Norlin R, Klässbo M. Sever's injury; treat it with a heel cup: a randomized, crossover study with two insole alternatives. *Scand J Med Sci Sports*. 2011;21(6):e42-7.
28. Perhamre S, Lundin F, Klässbo M, Norlin R. A heel cup improves the function of the heel pad in Sever's injury: effects on heel pad thickness, peak pressure and pain [published online ahead of print March 16 2011]. *Scand J Med Sci Sports*. <http://onlinelibrary.wiley.com/doi/10.1111/j.1600-0838.2010.01266.x/full>. Accessed January 27, 2012.
29. Tu P, Bytowski JR. Diagnosis of heel pain. *Am Fam Physician*. 2011;84(8):909-16.

Thank you *NYCPM Alumni Association* for your kind support of NYCPM's *Podiatric Medical Review* and for your continuing dedication to the student body.

Reversible Diabetic Neuropathy: A Systematic Approach To Understanding Diabetic Neuropathy and Roads to its Reversibility

Faysal E Siddiqui, BS

Abstract

Introduction:

Peripheral neuropathy has been one of the most debilitating complications manifested by patients suffering from diabetes mellitus. For the past couple of decades, a substantial amount of research has been geared towards finding a cure for diabetic neuropathy. In this pursuit, several biochemical factors have surfaced which may hold potential in reversing diabetic peripheral neuropathy. The objective of this paper is to explore therapeutic options for neuropathic patients and to investigate whether it is possible to reverse diabetic neuropathy. This paper will review the epidemiology, etiology, therapeutic approaches, and current research on diabetic peripheral neuropathy.

Study design:

Qualitative Systematic Review of the Literature

Methods:

PubMed, Google Scholar and the Cochrane Library were searched for articles related to diabetes, peripheral neuropathy and its reversibility. Inclusion criteria: English language articles, demonstration of direct reversal of diabetic neuropathy; Exclusion criteria: neuropathy of etiological origin of diseases other than diabetes; insignificant reversal of neuropathy. Based on the inclusion and exclusion criteria, forty-eight articles were chosen for review. Ten of the forty-eight articles were retained for an in-depth review. These ten articles contained a balanced mix of articles based on basic and clinical research.

Results:

Five biochemical molecules were found to be significantly beneficial in reversing diabetic neuropathy both in laboratory and in some cases, in human clinical trials. Vascular endothelial growth factor, nitric oxide synthase, HMG-CoA reductase inhibitors, Insulin-like growth factor and zinc-finger transcription factor were investigated in detail for the purposes of this particular review.

Conclusions:

Biomedical research has come to find several plausible and effective ways to reverse diabetic neuropathy. More research is necessary to understand the overall long-term systemic effect of these biochemical molecules on the body as a whole, specifically in diabetic patients as they suffer from multiple co-morbidities.

Keywords: Diabetes mellitus, Diabetic neuropathy, HMG-CoA reductase inhibitor, Insulin-like growth factor, Nitric oxide synthase, Reversible diabetic neuropathy, Vascular endothelial growth factor, Zinc-finger transcription factor

Level of Evidence: 4

Introduction

Background

Diabetes is a systemic illness, which involves many organs. It is essentially a failure of the body's ability to regulate blood sugar and can be divided into two types. Type I diabetes is usually diagnosed in children and young adults, and was previously known as juvenile diabetes⁸⁹. In type 1 diabetes, the body does not produce insulin⁸⁹. In type 2 diabetes, either the body does not produce enough insulin or the cells are resistant to insulin⁹⁰. Both types could potentially pose serious risk to vital organs, however type II diabetes tend to cause more harm as it can go undetected for many years and is generally much harder to control. Uncontrolled diabetes mellitus can lead to poor wound healing, kidney damage, peripheral nerve damage (diabetic neuropathy) and retinal damage.

Diabetic patients make up a large percentage of podiatric patients. Whether diabetic neuropathy is reversible or not is the question many of us, current and future podiatrists have contemplated at least once or twice in our practice and training. Diabetic neuropathy is a type of nerve damage that can occur if one has diabetes⁹¹. High blood sugar can injure nerve fibers throughout a patient's body, but diabetic neuropathy most often damages nerves in a patient's legs and feet⁹¹. Type II diabetes mellitus frequently leads to complications involving vascular and neuronal pathways ultimately resulting in lower limb ischemia and peripheral neuropathies. Patients chronically suffering from these complications, frequently face debilitating ulcers and amputations.

One of the major contributions to neuropathic changes in diabetic patients is the lack of

sufficient nutrient-rich blood supply to the damaged nerves. Research has been done exploring ways to reverse diabetic neuropathy by enhancing direct neuronal regeneration as well as enhancing blood supply to the affected nerves. In this paper we will explore several different modalities, which may play a critical role in reversing diabetic neuropathy. Among these factors are nitric oxide synthase, vascular endothelial growth factor, HMG-CoA reductase inhibitors, insulin-like growth factor, and a newly engineered zinc finger-transcription factor. All of these factors have demonstrated effective reversal of diabetic peripheral neuropathy, in some cases almost close to healthy levels.

Peripheral neuropathy is one of the major complications of diabetes that can lead to significant morbidity¹. Sensory abnormalities predominate², leading to a failure to detect minor trauma of the lower extremities, ultimately contributing to skin ulcerations. The notion that such ulcerations may lead to lower extremity amputation³ is borne out by the fact that the rate of lower limb amputation is 15 times higher in diabetic than in non-diabetic patients⁴. Indeed, some reports indicate that 20% of all hospital admissions among diabetic patients in the United States are for foot problems⁵.

As reported in the Diabetes Control and Complications Trial⁶, the incidence of new clinically detected neuropathy per patient-year was as high as 7.0%. Even with intensive therapy, including insulin and more effective oral agents, the incidence of neuropathy has increased to as much as 16%⁷ of the 17 million diabetic patients in the United States alone¹. The pathogenic mechanisms of diabetic neuropathy that have been considered include the following: degeneration of proteins critical to neural function by non-enzymatic glycosylation⁸, altered neural polyol metabolism^{9,10}, reduction of neurotrophic factors^{2,11}, and microvascular disease with impaired blood flow^{10,12,13}. Ischemia in diabetic nerves^{14,15} has also been considered in the pathogenesis of diabetic complications.

Extensive studies have been done in the last two decades trying to demystify diabetes mellitus and its rather common neuropathic complications. The major pathological feature is a dying-back axonopathy that involves both unmyelinated and myelinated axons. Distal axonopathy, or "dying-back axonopathy", is the result of some metabolic or toxic derangement of neurons. Daily wear-and-tear on the nervous system requires ability for nerve regeneration. The poor nerve regeneration associated with diabetes may explain the loss of synapses, dying-back axonopathy and loss of neurons⁵².

There is reduced conduction velocity in about 90% of patients, even though progression to clinically significant disease is experienced by a much lower fraction of diabetic patients⁵².

The most prevalent form of this complication is a symmetrical sensory neuropathy. Burning unremitting pain, such that a patient cannot bear even the weight of a bed sheet, is sometimes encountered. Inability to perceive pain and touch as well as impaired proprioceptors result in an increased tendency for injuries⁵². In conjunction with poor wound healing and increased susceptibility to gangrene, approximately 100,000 limb amputations are performed on diabetic patients each year^{16,17}.

In this paper, we will review several modalities being tested in the lab and patient trials that may contribute to bringing therapeutic relief to diabetic neuropathic patients. We will explore their mechanisms of actions, benefits and possible precautions and side effects. Among the more commonly tested biochemical molecules are VEGF (vascular endothelial growth factor) and its gene transfer, insulin-like growth factor, nitric oxide synthase, HMG-CoA reductase inhibitors and zinc-finger transcription factors.

FIGURE 1

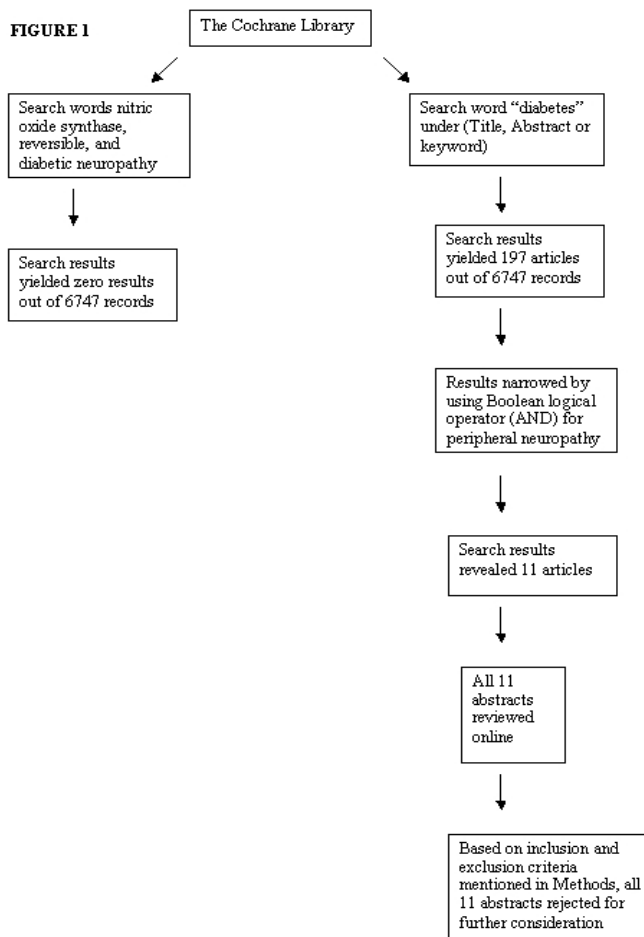


FIGURE 2

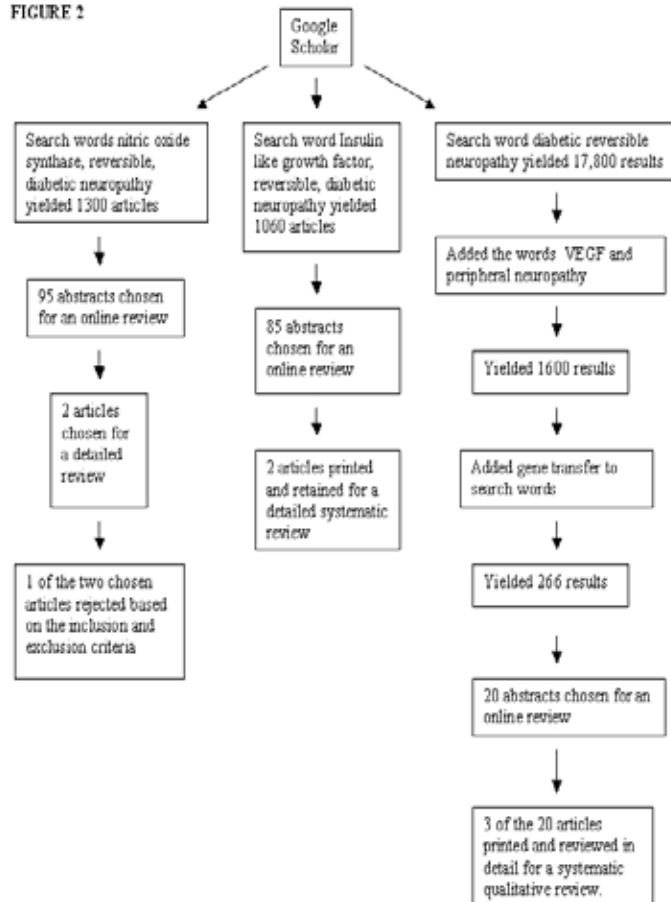
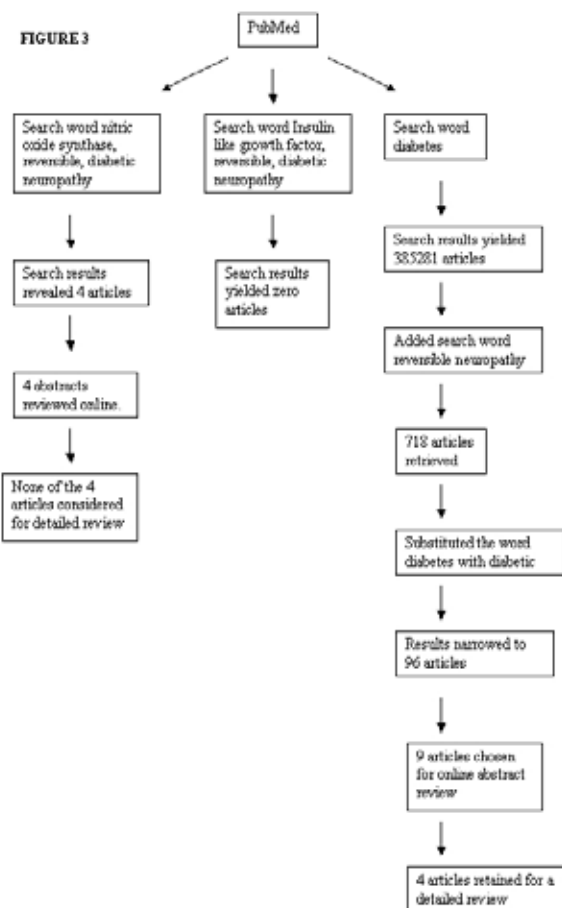


FIGURE 3



Methods

A systematic literature search was carried out accessing PubMed, Google Scholar, and the Cochrane library. The articles ranged mainly from 1966 to the most current publications. The search phrases “diabetes”, “neuropathy”, “diabetic complications”, “reversible neuropathy” and “peripheral neuropathy” were utilized to yield the greatest sensitivity while accessing articles. Criteria for inclusion included research demonstrating direct work towards possibly improving diabetic neuropathy. Additionally, exclusion criteria included neuropathy of an etiology other than diabetes or research demonstrating failed attempts in reversing neuropathy.

Search methods used through the Cochrane Library, Google Scholar and PubMed are listed in figures 1, 2, and 3 respectively. Effectiveness, toxicity, side effects, and human vs. animal trial information of the five-biochemical molecules being reviewed is summarized in Table 1.

Discussion

Vascular Endothelial Growth Factor and its Gene Transfer

Experimental diabetic neuropathy results from destruction of the vasa nervorum and can be reversed by administration of VEGF^{18,19}, an endothelial cell mitogen that has been previously shown to promote angiogenesis in a variety of animal models^{20,21,22,23} and more recently, in human subjects^{24,25,26,27}.

Studies in rats show that within 12 weeks of the onset of diabetes, induced by streptozotocin (50 mg/kg), rats developed a severe peripheral neuropathy²⁸. In the nerves of diabetic rats, the total number of vasa nervorum was markedly reduced, resulting in an irregular distribution pattern and areas of non-vascularized nerve tissue²⁹. Cross sections from these nerves disclosed a significant reduction in the number of vasa nervorum compared with that of nerves from normal control animals²⁹.

Intramuscular gene transfer of naked DNA encoding the angiogenic growth factor VEGF-1 or VEGF-2 led to resolution of clinical signs of peripheral neuropathy and of vasculopathy,

demonstrating full restoration to normal levels of motor nerve conduction velocity (MCV) and sensory nerve conduction velocity (SCV) within 4 weeks after gene transfer. This improvement persisted for up to 10 weeks after gene transfer.

Gene transfer to non-diabetic control animals had no effects on functional nerve parameters. Saline-injected diabetic rats showed a further deterioration in neuropathy²⁹. In diabetic rats with VEGF gene transfer, peripheral nerve vascularity remained well preserved. Moreover, diabetic rats undergoing VEGF gene transfer showed enhanced perfusion, compared with that of the diabetic saline-injected rats²⁹.

Intramuscular injection of a plasmid coding for VEGF prevents the development of diabetic neuropathy in rodents and rabbits³⁰. However, VEGF has substantial effects on tumor angiogenesis³¹ that may enhance tumor formation and tumor growth if the peptide is administered systemically³². For that reason, local release of VEGF in peripheral nerve may be required in order to use this treatment safely in diabetic neuropathy³³.

HSV-mediated gene transfer of VEGF to the dorsal root ganglia provides for local release of neurotrophic substances that may act in an autocrine or paracrine manner to protect peripheral sensory neurons from axonal degeneration³³. Despite substantial evidence in animal models demonstrating that neurotrophic factors are beneficial in the treatment or prevention of peripheral neuropathy, the treatment of human neuropathies has been limited, in part because of the short half-life of these peptide factors and the side effects engendered by systemic administration³³.

To investigate whether VEGF gene transfer could interfere with glucose metabolism in the study animals, glucose levels were monitored in blood and 24-hour urine samples. VEGF-1 and VEGF-2 gene transfer had no effects on either blood or urine glucose levels in non-diabetic or diabetic animals²⁹. Furthermore, because VEGF may have potential adverse effects on diabetic nephropathy³⁴, renal function was monitored in non-diabetic and diabetic rats.

Although renal functional parameters were consistent with the development of nephropathy in diabetic animals, VEGF gene transfer did not cause deterioration in pre-existing disease, as indicated by similar renal functional parameters and kidney/body weight ratios in both VEGF-transfected and saline injected control groups²⁹.

There are currently no therapeutic options for patients with diabetic neuropathy. It is intriguing to note that neurological and neurophysiological findings in a prospective study of 24 patients

undergoing phVEGF165 gene transfer for critical limb ischemia disclosed clinical improvement and statistically significant improvement in electrophysiological measurements performed in four of the six diabetic patients who completed the study³⁵.

HMG-CoA Reductase Inhibitors and their Effect on Nitric Oxide Synthase and VEGF

Studies have documented that vascular endothelial growth factor (VEGF) gene transfer successfully modifies neuropathy by restoring microcirculation in vasa nervorum^{29,36}. In addition, HMG-CoA reductase inhibitors, or "statins," can exert an angiogenic effect in ischemic tissues^{37,38,39}. The disordered peripheral nerve physiology resulting from experimental diabetes is associated with marked destruction of the vasa nervorum of the sciatic nerve. A new HMG-CoA reductase inhibitor, rosuvastatin has proven to successfully restore these vasa nervorum¹.

The overall restoration of the number and cross-sectional area of vasa nervorum in db/db mice to a pattern similar to that of non-diabetic mice was observed after rosuvastatin administration¹. The coincidence of restoration of vasa nervorum accompanied by functional nerve recovery has now been documented in diabetic animal models with the use of three distinct angiogenic agents, VEGF²⁹, sonic hedgehog³⁶, and most recently rosuvastatin¹. The recovery of vasa nervorum was mainly associated with recovery of nNOS/NO (neuronal nitric oxide synthase/ nitric oxide) production to match levels in non-diabetics¹.

Co-administration of rosuvastatin and a nNOS specific inhibitor, TRIM, partially reversed the effect of rosuvastatin¹. Weis et al have reported that cerivastatin increases endothelial VEGF release and modulates VEGF receptor-2 expression in endothelial cells. Rosuvastatin directly up regulates nNOS/NO in Schwann cells via the PI3K/Akt signaling pathway¹. Neuronal nitric oxide synthase has been shown to play a role as a neuroprotective factor^{41,42} and as a nitric oxide producer¹.

Controlling VEGF through Zinc-Finger Transcription Factors

Preliminary results from clinical studies indicate improvement in the signs and symptoms of sensory neuropathy in diabetic patients after intramuscular injection of a plasmid DNA encoding VEGF165-A⁴³.

Zinc Finger Protein –Transcription Factors (ZFP-TF) can be designed to control the engineered ZFP-TF designed to up-regulate the

expression of the endogenous VEGF-A gene. It is capable of activating the expression of VEGF-A mRNA and protein, both in cultured rat cells and in differentiated human skeletal myocytes⁴⁴.

Gene transfer with a plasmid DNA encoding the VEGF-A165 isoform improved nerve conduction velocities in several in-vivo studies^{45,46}. Moreover, in an open-label, dose-escalation trial of the same plasmid DNA encoding the VEGF-A165 isoform, four of six patients enrolled who had diabetes showed an improvement in neuropathy in the treated limb⁴³.

Beyond protection, VEGF-A has also been shown to promote neuronal growth on cultures of adult mouse dorsal root ganglion and superior cervical ganglion explants^{47,48}. In addition, VEGF-A has shown both protective and potent growth factor activity for Schwann cells^{47,49}, which provide myelination and support functions to neurons, suggesting an additional potential mechanism for the beneficial effects of VEGF-A action in-vivo⁴⁴. It is remarkable that this positive effect was observed 28 days after a single intramuscular treatment with plasmid DNA encoding VZ_434⁴⁴.

This result is perhaps even more surprising given the short (<7 days) duration of transgene expression observed⁴⁴. Work in an ALS amyotrophic lateral sclerosis mouse model showed that VEGF-A, not the potent angiogenic factor PLGF (placental growth factor), prevented motor neuron degradation⁵⁰.

Current findings indicate a neuroprotective effect for the VEGF-A-activating ZFP-TF (VZ_434) both in-vitro and in animal models of diabetes in-vivo and thus suggest that this engineered transcription factor could represent a novel therapeutic modality for the potential treatment of diabetic neuropathy⁴⁴.

Collectively, these studies have provided support for the development of therapies for peripheral neuropathy based on VEGF165-A as well as other VEGF gene family members. Human gene therapy clinical trials testing this concept have either been proposed or are underway⁵¹.

Insulin-Like Growth Factor

Loss of IGF, insulin-like growth factor activity produces neurological disorders that mimic the disturbances of diabetic neuropathy⁵². Studies, using age-matched patient groups, found that IGF-I level is significantly reduced by 40% to 50% in type I and type II diabetes^{53,54,55}. IGFBP-1 (IGF-binding protein-1) circulating levels in these patients are elevated, which sequester and reduce the activity of IGF⁵⁶.

Diabetic patients with neuropathy have lower serum IGF-I levels versus diabetic patients without neuropathy or non-diabetic patients^{57,58}. Reduced numbers of IGF-I receptors are found on red blood cells of diabetic patients^{57,59}. It is critical to recognize that there is an age-dependent decline of IGF in humans in the later decades of life⁶⁰. This may explain the age-dependence of clinical neuropathy⁶¹ and the increased incidence of neuropathy after the fourth decade of life.

Blocking of IGF activity in normal, non-diabetic animals produces neuropathy with characteristics similar to that observed in diabetes. For example, anti-IGF antibodies can block sensory and motor nerve regeneration in normal rats^{62,62,64}. Neuron loss is observed in both the peripheral and central nervous systems in rats treated with an anti-IGF antiserum⁶⁵ and in IGF-I-null mice⁶⁶.

Conduction velocity and axonal diameters are reduced in diabetic patients and in IGF-I-knockout mice^{67,68}. IGF-I administration can reverse the low motor and sensory nerve conduction velocity in these mice. IGF increases α -tubulin, β -tubulin, 68-kDa neurofilament, and 170-kDa neurofilament gene expression^{67,88}. These neurofilaments regulate axonal diameters, which are reduced in diabetes. Tubulins provide tracks on which axonal transport is heavily dependent upon. These are also disturbed in diabetes. The metabolic needs are the greatest for the longest axons, which may underlie the length-dependent axonopathy in diabetes⁵².

IGF-I gene expression is profoundly reduced in the liver, adrenal glands, and spinal cords of streptozotocin (STZ)-diabetic rats, a model of type I diabetes⁷⁰. IGF-II gene expression is reduced in diabetic rat brain⁷¹. The significant decrease in poly(A)+RNA content per milligram brain tissue⁷¹ may be related to the progressive cerebral atrophy in the brains of diabetic patients⁷².

IGF-I and IGF-II mRNA content is reduced in sciatic nerves early after the induction of diabetes⁷³, mostly in Schwann cells⁷⁴. IGF-I mRNA and its receptor mRNA levels are reduced in the spinal cord, superior cervical ganglia^{75,76}, and dorsal root ganglia⁷⁷. Rats quickly develop neuropathy because of a profound loss of neurotrophic activity involving insulin, IGF-I, and IGF-II.

IGF levels are reduced in the pre-diabetic state prior to hyperglycemia, and reduced further as a consequence of aging. It is instructive that IGF-I and IGF-II gene expression are increased in cultured hepatocytes directly in response to

insulin^{78,79}. Infusion of either IGF-I or IGF-II arrested the progression of hyperalgesia⁸⁰. IGFs normally regulate nerve regeneration^{62,63,64}. The IGF theory⁸¹ predicts that replacement IGF therapy should prevent impaired nerve regeneration in diabetic patients.

Additional studies now reveal that systemic infusion of IGF-I or IGF-II can prevent or reverse impaired nerve regeneration^{80,81,82}. This treatment reverses neuroaxonal dystrophy by 86% in the superior mesenteric ganglion and ileal mesenteric nerves in rats that have been diabetic for 6 months⁸³. IGF-I mRNA levels are reduced in the gut mucosa with poor healing of gastric lesions in diabetic rats⁸⁴.

Recent studies show that IGFs can cross the blood-CNS barrier. In a pioneer study, 8 minutes after injection of 125I-IGF-I or 125I-IGF-II into the carotid artery, radioactivity was detected in brain parenchyma by auto-radiography of brain slices⁸⁵.

Quantitative ultra structural studies demonstrated a five to six fold increase in the frequency of neuroaxonal dystrophy in the (No Rx group) untreated group of diabetic rats in comparison to age-matched controls⁸³. Treatment of diabetics with a 2-month course of IGF-I resulted in a 86% decrease in the frequency of neuroaxonal dystrophy compared to No Rx diabetics and an 80% decrease compared to the Pre-Rx group of diabetics⁸³.

The observation that levels of serum IGF-I and IGF-II also decrease with aging in human subjects⁸⁶ suggests a possible common shared mechanism in aging and diabetes resulting in

sympathetic neuroaxonal dystrophy. It has been proposed that IGF-I supports the normal peripheral nervous system and is diminished in diabetics with a superimposed additional age-related decrease in IGF-II, resulting in the apparent age-dependency of some forms of diabetic neuropathy⁸⁷.

Conclusion

Insulin-like growth factor, vascular endothelial growth factor, and nitric oxide synthase have all been repeatedly researched in the labs and have consistently produced similar promising results.

VEGF-I or VEGF-II leads to resolution of clinical signs of peripheral neuropathy and of vascular pathology. It reverses and fully restores the motor nerve conduction (MCV) and sensory nerve conduction velocity (SCV) back to normal levels in as little as four weeks after VEGF-gene transfer. Rats that underwent VEGF-gene transfer showed enhanced perfusion compared to those receiving saline injections.

VEGF directly prevents the development of diabetic neuropathy in rodents and rabbits and it protects peripheral sensory neurons from axonal degeneration. Dr. Simovic's work in 1999 reports significant improvement in electrophysiological measurements when assessing neurological and neurophysiological findings. This was a prospective study of 24 diabetic patients with peripheral neuropathy undergoing phVEGF gene transfer.

Despite such great performance, VEGF has substantial tumor angiogenesis effects. Local

Biochemical Molecule	Neuropathy improved	Toxicity	Side effects	Human or animal trials
a) VEGF	Yes	Systemic None Local	Tumorigenic, Nephropathy None	Animals, Limited human trials
b) Insulin-like Growth factor	Yes	None	None	Humans and animals
c) HMG-CoA Reductase inhibitors	Yes	None reported	None	Animals
d) Nitric oxide synthase	Yes	None	None	Animals
e) Zinc finger transcription factor	Yes	None	None	Animals, Limited human trials

Table 1: Comparison of an overall performance of the reviewed biochemical molecules in lab and clinical trials.
a) VEGF showed the most effective reversibility of neuropathy, however, it had the greatest side effects if administered systemically. b) Insulin-like growth factor by far had the greatest benefit yield over all in both humans and animals without any significant side effects. c) HMG-CoA reductase inhibitor and e) Zinc-finger transcription factor are not yet as extensively studied in humans. d) Nitric oxide synthase demonstrated neuron repair as well as neuroprotective effects.

release of VEGF in peripheral nerve is required in order to use this treatment safely in diabetic neuropathy. Treatment with VEGF has been limited due to its short half-life and the tumorigenic side effects when administered systemically.

HMG-CoA reductase inhibitors also known as "statins", exert angiogenic effects in ischemic tissues. Rosuvastatin administration demonstrates overall restoration of the number and cross sectional area of vasa nervorum in diabetic mice to that of non-diabetic mice. The recovery of vasa nervorum was mainly due to the recovery of HMG-CoA mediated upregulation of nitric oxide synthase and nitric oxide to non-diabetic levels.

Corvastatin increases endothelial VEGF release and upregulates neuronal nitric oxide synthase and nitric oxide in Schwann cells. This up-regulation plays a critical role in neuroprotection as well as nerve regrowth.

Zinc finger protein-transcription factor (ZFP-TF) holds the capacity to unlock the genetic expression of any desired gene at hand. VZ_434 is an engineered ZFP-TF designed to modulate the expression of endogenous VEGF-A gene. VEGF-A expression promotes Schwann cell growth, myelination, and protection. These neuroprotective activities were observed 28 days after a single intramuscular treatment with plasmid DNA encoding VZ_434.

Research in amyotrophic lateral sclerosis "ALS mouse-model" showed that VEGF-A prevented motor neuron degradation.

Insulin-like growth factor-1 (IGF-1) normally regulates nerve regeneration and supports the normal health of the peripheral nervous system. IGF-1 level is significantly reduced by 40% - 50% in type I and type II diabetic patients. Conduction velocity and axonal diameter are also reduced in diabetic patients as well as IGF-1 knock-out mice. IGF-1 administration reverses the low conduction velocity in both motor and sensory neurons.

IGF-1 administration also up-regulates gene expression of alpha and beta tubulins, 68 kDa neurofilament, and 170 kDa neurofilament. These four neurofilaments regulate axonal diameter.

IGF-1 therapy holds potential in preventing damage and impaired nerve regeneration in diabetic patients. IGF-1 therapy has demonstrated 86% reversal of the neuroaxonal dystrophy in diabetic rats.

The recent therapeutic breakthroughs in reversing or preventing diabetic neuropathy have had limited patient exposure and most of the data is dependent on findings in animal

models. More clinical research is necessary in a prospective design to reveal long-term side effects, if any that may exist. At the pace science and discovery is moving, it is safe to say that it will not be too long before these determinations are made and one or more of the aforementioned biochemical factors are applied successfully in clinical settings as a regular means of therapy.

Statement of Competing Interest

I declare that I have no significant competing financial, professional or personal interests that might have influenced the performance or presentation of the work described in this manuscript.

References

1. Masaaki L, Hiromi N, Kengo FK, et al. Neuronal nitric oxide synthase mediates statin induced restoration of vasa nervorum and reversal of diabetic neuropathy. *Circulation*. 2005; 112: 93-102.
2. Tomlinson DR, Fernyhough P, Diemel LT. Role of neurotrophins in diabetic neuropathy and treatment with nerve growth factors. *Diabetes*. 1997;46(suppl 2): S43-S49.
3. Parkhouse N, LeQuesne PM. Impaired neurogenic vascular response in patients with diabetes and neuropathic foot lesions. *N. Engl. J. Med*. 1988. 318:1306-1309.
4. Veves A, Akbari CM, Primavera J, et al. Endothelial dysfunction and the expression of endothelial nitric oxide synthase in diabetic neuropathy, vascular disease, and foot ulceration. *Diabetes*. 1998. 47:457-463.
5. Reiber GE, Smith DG, Carter J, Fotieo G, et al. A comparison of diabetic foot ulcer patients managed in VHA and non-VHA settings. *J Rehabil Res Dev*. 2001;38: 309-317.
6. The Diabetes Control and Complications Trial Research Group. The effect of intensive treatment of diabetes on the development and progression of long-term complications in insulin-dependent diabetes mellitus. *N. Engl. J. Med*. 1993;329:977-988.
7. The Diabetes Control and Complications Trial Research Group. The effect of intensive treatment of diabetes on the development and progression of long-term complications in insulin-dependent diabetes mellitus. *N. Engl. J. Med*. 1993;329:977-986.
8. Cullum NA, Mahon J, Stringer K, et al. Glycation of rat sciatic nerve tubulin in experimental diabetes mellitus. *Diabetologia*. 1991;34: 387-389.
9. Greene DA, Lattimer SA, Sima AA. Sorbitol, phosphoinositides, and sodium-potassium-ATPase in the pathogenesis of diabetic complications. *N. Engl. J. Med*. 1987;316:599-606.
10. Cameron NE, Cotter MA, Low PA. Nerve blood flow in early experimental diabetes in rats: relation to conduction deficits. *Am. J. Physiol*. 1991;261:E1-E8.
11. Apfel SC, Arezzo JC, Brownlee M, et al. Nerve growth factor administration protects against experimental diabetic sensory neuropathy. *Brain Res*. 1994;634:7-12.
12. Tuck RR, Schmelzer JD, Low PA. Endoneurial blood flow and oxygen tension in the sciatic nerves of rats with experimental diabetic neuropathy. *Brain*. 1984;107:935-950.
13. Tesfaye S, Harris N, Jakubowski JJ, et al. Impaired blood flow and arterio-venous shunting in human diabetic neuropathy: A novel technique of nerve photography and fluorescein angiography. *Diabetologia*. 1993;36:1266-1274.
14. Dyck PJ. Hypoxic neuropathy: Does hypoxia play a role
15. Stevens EJ, Carrington AL, Tomlinson DR. Nerve

- ischaemia in diabetic rats: time-course of development, effect of insulin treatment plus comparison of streptozotocin and BB models. *Diabetologia*. 1994;37:43–48.
16. Bild DE, Selby JV, Sincock P, et al. Lower-extremity amputations in people with diabetes. *Epidemiology and prevention*. *Diabetes Care*. 1989;12, 24–31.
17. Litzelman DK, Slemenda CW, Langefeld CD, et al. Reduction of lower extremity clinical abnormalities in patients with non-insulin-dependent diabetes mellitus. *Ann Intern Med*. 1993; 119:36–41.
18. Leung DW, Cachianes G, Kuang WJ, et al. Vascular endothelial growth factor is a secreted angiogenic mitogen. *Science*. 1989. 246:1306–1309.
19. Dvorak HF, Brown LF, Detmar M, et al. Vascular permeability factor/vascular endothelial growth factor, microvascular hyperpermeability, and angiogenesis. *Am J Pathol*. 1995. 146:1029–1039.
20. Rivard A, Silver M, Chen D, et al. Rescue of diabetes related impairment of angiogenesis by intramuscular gene therapy with adeno-VEGF. *Am J Pathol*. 1999;154:355–364.
21. Tsurumi Y, Takeshita S, Chen D, et al. Direct intramuscular gene transfer of naked DNA encoding vascular endothelial growth factor augments collateral development and tissue perfusion. *Circulation*. 1996; 94:3281–3290.
22. Rivard A, Fabre JE, Silver M, et al. Age-dependent impairment of angiogenesis. *Circulation*. 1999;99:111–120.
23. Murohara T, Asahara T, Silver M, et al. Nitric oxide synthase modulates angiogenesis in response to tissue ischemia. *J Clin Invest*. 1998; 101:2567–2578.
24. Baumgartner I, Pieczek A, Manor O, et al. Constitutive expression of phVEGF165 following intramuscular gene transfer promotes collateral vessel development in patients with critical limb ischemia. *Circulation*. 1998;97:1114–1123.
25. Isner JM, Baumgartner I, Rauh G, et al. Treatment of thromboangiitis obliterans (Buerger's disease) by intramuscular gene transfer of vascular endothelial growth factor: preliminary clinical results. *J Vasc Surg*. 1998;28:964–975.
26. Isner JM, Pieczek A, Schainfeld R, et al. Clinical evidence of angiogenesis following arterial gene transfer of phVEGF165 in patients with ischemic limb. *Lancet*. 1996;348:370–374.
27. Losordo DW, Vale RP, Symes JF, et al. Gene therapy for myocardial angiogenesis: initial clinical results with direct myocardial injection of phVEGF165 as sole therapy for myocardial ischemia. *Circulation*. 1998; 98:2800–2804.
28. Apfel SC, Arezzo JC, Brownlee M, et al. Nerve growth factor administration protects against experimental diabetic sensory neuropathy. *Brain Res*. 1994. 634:7–12.
29. Schratzberger P, Dirk HW, Kilian R, et al. Reversal of experimental diabetic neuropathy by VEGF gene transfer. *The journal of Clinical Investigation*. 2001. 107:1083–1092.
30. Schratzberger P, Schratzberger G, Silver M, et al. Favorable effect of VEGF gene transfer on ischemic peripheral neuropathy. *Nat Med*. 2000; 6: 405–413.
31. Antonetti DA, Barber AJ, Hollinger LA, et al. Vascular endothelial growth factor induces rapid phosphorylation of tight junction proteins occludin and zonula occluden 1. A potential mechanism for vascular permeability in diabetic retinopathy and tumors. *J Biol Chem*. 1999; 274:23463–23467.
32. Castro-Rivera E, Ran S, Thorpe P, et al. Semaphorin 3B (SEMA3B) induces apoptosis in lung and breast cancer, whereas VEGF165 antagonizes this effect. *Proc Natl Acad Sci USA*. 2004;101: 11432–11437.
33. Chattopadhyay, M, Krisky D, Wolfe D, et al. HSV-mediated gene transfer of vascular endothelial growth factor to dorsal root ganglia prevents diabetic neuropathy. *Gene Ther*. 2005 September; 12(18); 1377–1384.
34. Duh E, Aillo LP. Vascular endothelial growth factor and diabetes: the agonist versus antagonist paradox. *Diabetes*. 1999; 48:1899–1906.
35. Simovic D, Ropper AH, Isner JM, et al. Improvement in ischemic limb neuropathy after vegf gene transfer. *Circulation*. 1999;18:1-770. (Abstr.)
36. Kusano K, Allendoerfer KL, Munger W, et al. Sonic hedgehog induces arteriogenesis in diabetic vasa nervorum and restores function in diabetic neuropathy. *Arterioscler Thromb Vasc Biol*. 2004;24:2102–2107.
37. Kureishi Y, Luo Z, Shiojima I. The HMG-CoA reductase inhibitor simvastatin activates the protein kinase Akt and promotes angiogenesis in normocholesterolemic animals. *Nat Med*. 2000;6:1004–1010.
38. Llevadot J, Murasawa S, Kureishi Y, et al. HMG-CoA reductase inhibitor mobilizes bone marrow-derived endothelial progenitor cells. *J Clin Invest*. 2001;108:399–405.
39. Dimmeler S, Aicher A, Vasa M., et al. HMG-CoA-reductase inhibitors (statins) increase endothelial progenitor cells via the P13 kinase/Akt pathway. *J Clin Invest*. 2001;108:391–397.
40. Weis M, Heeschen C, Glassford AJ, et al. Statins have biphasic effects on angiogenesis. *Circulation*. 2002;105:739–745.
41. Thippeswamy T, Jain RK, Mumtaz N. Inhibition of neuronal nitric oxide synthase results in neurodegenerative changes in the axotomized dorsal root ganglion neurons: evidence for a neuroprotective role of nitric oxide in vivo. *Neurosci Res*. 2001;40:37–44.
42. Keilhoff G, Fansa H, Wolf G. Nitric oxide synthase, an essential factor in peripheral nerve regeneration. *Cell Mol Biol (Noisy-le-grand)*. 2003;49:885–897.
43. Simovic D, Isner JM, Ropper AH, et al. Improvement in chronic ischemic neuropathy after intramuscular phVEGF165 gene transfer in patients with critical limb ischemia. *Arch Neurol*. 2001;58:761–768.
44. Price AS, Dent C, Duran-J B, et al. Gene Transfer of an engineered transcription factor promoting expression of VEGF-A protects against experimental diabetic neuropathy. *Diabetes*. 2006;55: 1847-1854,
45. Schratzberger P, Walter DH, Rittig K, et al. Reversal of experimental diabetic neuropathy by VEGF gene transfer. *J Clin Invest*. 2001;107: 1083–1092.
46. Schratzberger P, Schratzberger G, Silver M, et al. Favorable effect of VEGF gene transfer on ischemic peripheral neuropathy. *Nat Med*. 2000; 6:405–413.
47. Sondell M, Lundborg G, Kanje M. Vascular endothelial growth factor has neurotrophic activity and stimulates axonal outgrowth, enhancing cell survival and Schwann cell proliferation in the peripheral nervous system. *J Neurosci*. 1999;19:5731–5740.
48. Sondell M, Sundler F, Kanje M. Vascular endothelial growth factor is a neurotrophic factor which stimulates axonal outgrowth through the flk-1 receptor. *Eur J Neurosci*. 2000; 12:4243–4254.
49. Sondell M, Lundborg G, Kanje M. Vascular endothelial growth factor stimulates Schwann cell invasion and neovascularization of acellular nerve grafts. *Brain Res*. 1999;846:219–228.
50. Lambrechts D, Storkebaum E, Morimoto M, et al. VEGF is a modifier of amyotrophic lateral sclerosis in mice and humans and protects motoneurons against ischemic death. *Nat Genet*. 2003;34:383–394.
51. Isner JM, Ropper A, Hirst K. VEGF gene transfer for diabetic neuropathy. *Human Gene Ther*. 2001;12:1593–1594.
52. Douglas NI, Sean BL. Insulin-like growth factor replacement therapy for diabetic neuropathy: Experimental Basis. *Experimental Diabetic Res*. 2003; 4:257-269.
53. Tan K, Baxter RC. Serum insulin-like growth factor I levels in adult diabetic patients: The effect of age. *J Clin EndocrinolMetab*. 1986;63, 651–655.
54. Arner P, Sjoberg S, Gjotterberg M, et al. Circulating insulin-like growth factor I in type 1 (insulin-dependent)

- diabetic patients with retinopathy. *Diabetologia*. 1989;32, 753–758.
55. Ekman B, Nystrom F, Arnqvist HJ. Circulating IGF1 concentrations are low and not correlated to glycaemic control in adults with type 1 diabetes. *Eur J Endocrinol*. 2000;143, 505–510.
56. Crosby SR, Tsigos C, Anderton CD, et al. Elevated plasma insulin-like growth factor binding protein-1 levels in type 1 (insulin-dependent) diabetic patients with peripheral neuropathy. *Diabetologia*. 1992;35, 868–872.
57. Migdalis IN, Kalogeropoulou K, Kalantzis L, et al. Insulin-like growth factor-I and IGF-I receptors in diabetic patients with neuropathy. *DiabeticMed*. 1995;12, 823–827.
58. Guo H, Yang Y, Geng Z, et al. The changes of insulin-like growth factor-1 in diabetic patients with neuropathy. *Chin Med J*. 1999;112, 76–79.
59. Haruta T, Kobayashi M, Takata Y, et al. Insulin-like growth factor I receptors on erythrocytes in NIDDM. *Diabetes Res Clin Pract*. 1989; 6, 95–101.
60. Hall K, Sara VR. Somatomedin (IGF) levels in childhood, adolescence and adult life. *Clic Endocrinol Metab*. 1984;13, 91–112.
61. Pirart J. Diabetes mellitus and its degenerative complications: a prospective study of 4,400 patients observed. *Diabetes Care*. 1978;1,168–188.
62. Kanje M, Skottner A, Sjoberg J, et al. Insulinlike growth factor I (IGF-I) stimulates regeneration of the rat sciatic nerve. *Brain Res*. 1989; 486, 396–398.
63. Near SL, Whalen LR, Miller JA, et al. Insulinlike growth factor II stimulates motor nerve regeneration in rats. *Proc Natl Acad Sci U. S. A*. 1992;89,11716–11720.
64. Glazner GW, Lupien S, Miller JA, et al. Insulinlike growth factor-II increases the rate of sciatic nerve regeneration in rats. *Neuroscience*. 1993;54, 791–797.
65. Pu S-F, Zhuang H-X, Marsh DJ, et al. Insulinlike growth factor-II increases and IGF is required for postnatal rat spinal motoneuron survival following sciatic nerve axotomy. *J Neurosci Res* 1999;55, 9–16.
66. Beck K, Powell B-L, Widmer H, et al. IGF1 gene disruption results in reduced brain size, CNS hypomyelination, and loss of hippocampal granule and striatal parvalbumin-containing neurons. *Neuron*. 1995;14, 717–730.
67. Rabinovsky ED, Kattash MM, Shenaq SM, et al. The role of IGF-I in peripheral nerve regeneration: Studies in IGF-I transgenic mice. *Soc Neurosci Abstract*. 1996;22:1960.
68. Mill JF, Chao MV, Ishii DN. Insulin, insulinlike growth factor-II and nerve growth factor effects on tubulin mRNA levels and neurite formation. *Proc Natl Acad Sci. U. S. A*. 1985;82,7126–7130.
69. Wang C, Li Y, Wible B, et al. Neurofilament mRNA and tubulin mRNA content in human neuroblastoma SH-SY5Y cells during neurite outgrowth directed by insulin and insulin-like growth factors. *Mol Brain Res*. 1992; 13, 289–300.
70. Ishii DN, Guertin D, and Whalen LR. Reduced insulin-like growth factor-I mRNA content in liver, adrenal glands and spinal cord of diabetic rats. *Diabetologia*. 1994;37, 1073–1081.
71. Wuarin L, Namdev R, Burns JG, et al. Brain insulin-like growth factor-II mRNA content is reduced in insulin-dependent and non-insulin-dependent diabetes mellitus. *J Neurochem*. 1996;67, 742–751.
72. Araki Y, Nomura M, Tanaka H, et al. MRI of the brain in diabetes mellitus. *Neuroradiology*. 1994;36, 101–103.
73. Wuarin L, Guertin, DM, Ishii DN. Early reduction in insulin-like growth factor gene expression in diabetic nerve. *Exp Neurol*.1994;130, 104–114.
74. Pu S-F, Zhuang H-X, Ishii DN. Differential spatiotemporal expression of the insulin-like growth factor genes in regenerating sciatic nerve. *Mol Brain Res*. 1995;34, 18–28.
75. Bitar MS, Pilcher CWT, Khan I, et al. Diabetes-induced suppression of IGF-I and its receptor mRNA levels in rat superior cervical ganglia. *Diabetes Res Clin Pract*. 1997;38,73–80.
76. Bitar MS, Pilcher CW. Attenuation of IGF-1 antinociceptive action and a reduction in spinal cord gene expression of its receptor in experimental diabetes. *Pain*. 1998;75, 69–74.
77. Craner MJ, Klein JP, Black JA, et al. Preferential expression of IGF-I in small DRG neurons and downregulation following injury. *Neuroreport*. 2002;13, 1649–1652.
78. Phillips LS, Goldstein S, and Pao CI. Nutrition and somatomedin. XXVI. Molecular regulation of IGF-I by insulin in cultured rat hepatocytes. *Diabetes*. 1991;40, 1525–1530.
79. Goya L, de la Puente A, Ramos S, et al. Regulation of IGF1 and -II by insulin in primary cultures of fetal rat hepatocytes. *Endocrinology*. 2001;142, 5089–5096.
80. Zhuang H-X, Snyder CK, Pu S-F, et al. Insulinlike growth factors reverse or arrest diabetic neuropathy: Effects on hyperalgesia and impaired nerve regeneration in rats. *Exp Neurol*. 1996;140, 198–205.
81. Ishii DN, and Lupien S. Insulin-like growth factors protect against diabetic neuropathy: Effects on sensory nerve regeneration in rats. *J Neurosci Res*. 1995; 40, 138–144.
82. Zhuang H-X, Wuarin L, Fei Z-J, et al. Insulinlike growth factor (IGF) gene expression is reduced in neural tissues and liver from rats with non-insulin-dependent diabetes mellitus, and IGF treatment ameliorates diabetic neuropathy. *J Pharmacol Exp Ther*. 1997;283, 366–374.
83. Schmidt RE, Dorsey DA, Beaudet LN, et al. Insulin-like growth factor I reverses experimental diabetic autonomic neuropathy. *Am. J. Pathol*. 1999;155, 1651–1660.
84. Korolkiewicz RP, Jujita A, Seto K, et al. Polaprezinc exerts a salutary effect on impaired healing of acute gastric lesions in diabetic rats. *Digest Dis Sci*. 2000;45, 1200–1209.
85. Reinhardt RR, and Bondy CA. Insulin-like growth factors cross the blood-brain barrier. *Endocrinology*. 1994; 135, 1753–1761.
86. Tan K, Baxter RC. Serum insulin-like growth factor I levels in adult diabetic patients: the effect of age. *J Clin Endocrinol Metab*. 1986;63:651–655
87. Ishii DN. Implication of insulin-like growth factors in the pathogenesis of diabetic neuropathy. *Brain Res Rev*. 1995;20:47–67.
88. GaoW-Q, Shinsky N, Ingle G, et al. IGF-I deficient mice show reduced peripheral nerve conduction velocities and decreased axonal diameters and respond to exogenous IGF-I treatment. *J Neurobiol*. 1999;39,142–152.
89. American Diabetes Association Website. Available at: <http://www.diabetes.org/diabetes-basics/type-1/?loc=DropDownDB-type1> . Accessed February 9, 2012.
90. American Diabetes Association Website. Available at: <http://www.diabetes.org/diabetes-basics/type-2/?loc=DropDownDB-type2> . Accessed February 9, 2012.
91. Mayo Clinic Website. Available at: <http://www.mayoclinic.com/health/diabetic-neuropathy/DS01045> . Accessed February 10, 2012

The Risk Factors for Stress Fractures - A Systematic Review of Recent Literature

Jacqueline L. Prevete, BS and Tyler J. Silverman, BA*

Abstract

Introduction:

This systematic review assesses the major risk factors for stress fractures in the bones of the lower extremity.

Study Design:

Qualitative Systematic Review of the Literature

Methods:

A literature search was conducted using Science Direct database, which yielded 204 results and six articles that met our criteria. Our PubMed Central search produced three results, all of which also appeared in the Science Direct results. The American Journal of Sports Medicine search yielded seven results of which four met our criteria. Our inclusion criteria were all retrospective, prospective, cohort studies, and case reports of stress fractures in both athletes and military recruits of both genders. We also included articles relating to impact forces. Our exclusion criteria were those articles which were expert opinion, not directly related to stress fractures in the lower extremity in humans, and those that were generalized to the lower extremity with no specific mention of metatarsal stress fractures.

Results:

The only consistently significant variable identified as a risk factor for stress fractures was amenorrhea. The variables that were consistently insignificant for stress fracture risk throughout the studies they were included in were weight, BMI, and use of oral contraceptives.

Conclusions:

Our conclusions as a result of this systematic review demonstrate that amenorrhea should be considered a direct risk factor for stress fractures in the lower extremity.

Key Words: stress fractures, metatarsals, risk factors, runners

Level of evidence: 4

*DPM, Class of 2012

Introduction

Stress fractures are a type of overuse injury that affects athletes, military recruits, and other individuals who engage in high impact physical activity. A stress fracture can result after the skeletal system is exposed to micro-trauma due to repetitive loading. If the trauma occurs faster or more frequently than the body can repair itself, a small crack in the bony matrix, otherwise known as a stress fracture, can result¹. Identifying the risk factors for stress fractures may lead to preventative measures to keep people active longer. Because this type of overuse injury may require a longer recovery time than a soft tissue injury, it can be particularly devastating to athletes and other individuals who suffer from them.

One of the dangers of not treating stress fractures properly is the development into total fractures of larger magnitude. One Boston marathoner even developed a comminuted fracture of the femur after running with a stress fracture in the femoral shaft². This article reviews current literature on risk factors that increase one's susceptibility to stress fractures in the lower extremity. While there have been studies that have looked at various risk factors for stress fractures individually, this systematic review

examines multiple different potential risk factors for stress fractures, using pooled data from multiple sources to provide insight for the scientific community.

Methods

The databases used to search for literature on this topic included the American Journal of Sports Medicine, Science Direct, and PubMed Central. Our inclusion criteria were all retrospective, prospective, cohort studies, and case reports of stress fractures in both athletes and military recruits of both genders. We also included articles relating to impact forces. The searches for Science Direct and PubMed Central were limited to the English language and the search terms "stress fractures, risk factors, metatarsals, and runners" were used in each database from 2001 to present. The American Journal of Sports Medicine was searched from 1991 to present with the search terms "risk factors and stress fractures." The Science Direct database search yielded 204 results of which six articles met our criteria. Our PubMed Central search produced three results, all of which also appeared in the Science Direct results. The American Journal of Sports Medicine search yielded seven results of which four articles met



our criteria. Of all results yielded a total of 10 articles were included in this literature review³⁻¹². The titles and abstracts of the articles were reviewed and those which were expert opinion, not directly related to stress fractures in the lower extremity in humans, and those that were generalized to the lower extremity with no specific mentioning of metatarsal stress fractures were eliminated.

Results

First, we will discuss the variables addressed in two or more studies. Many of the variables were a significant risk factor in one study and insignificant in others. The only risk factor that was constantly identified as significant was amenorrhea^{3,9}. The variables always identified as having no significant risk were decreased weight^{7,9,10}, BMI^{6,9,10}, and use of oral contraceptives^{3,9}.

The only variable addressed in a double-blinded randomized controlled study was the prophylactic treatment of risedronate. This study showed no significant effect of prophylactic risedronate on stress fracture risk⁷. Of note, this study had a large dropout rate.

Since many of the studies did not directly compare the same variables, we then grouped the risk factors to make better comparisons between studies. We categorized the risk factors into: height and bone length, pre-study fitness, training during study, footwear and training surface, demographics, start of menarche, history of amenorrhea, nutrition, bone density, range of motion, biomechanical, and oral contraception and hormones^{table 1}. We did not include high frequency of sweating within our categories as it was only addressed in one study⁹. There was no one significant risk factor that was constant throughout all the studies^{table 1}.

Discussion

This review shows that more studies are needed on stress fracture risk factors. There are many conflicting study findings that need to be resolved. However, the current literature provides some insight into the risk of stress fractures.

Amenorrhea has been shown to be a risk factor for stress fractures^{3,9}. However, many of the nutritional variables studied showed conflicting results. Many of the studies looked at nutritional risk factors for stress fractures. Amenorrhea may also be due to lifestyle, medications, developmental, and structural problems. Amenorrhea is not limited to just hormonal or nutritional imbalances. The studies showed no conclusive evidence that any of the

sex hormone levels or receptor genotypes had a significant influence on the risk of stress fractures. The lack of hormonal influence is further illustrated by no significant stress fracture risk alteration associated with oral contraceptive use. It is unclear what the underlying cause(s) of amenorrhea was/were in these subjects, and until that is fully understood, the etiology related to stress fracture risk is unknown.

Weight, BMI, and the use of oral contraceptives were not linked to increased risk of stress fractures^{3,6,7,9,10}. Weight and BMI can be influenced by fat, muscle, and bone structure. In addition, weight and BMI can change with fitness level, which was also a variable in several of the studies included. The interaction of weight, BMI, and fitness may have confounded some of the study results due to their close relationships.

A few studies examined bone mineral density and content of various bones (including those of the upper extremity)^{3,6,11}. The measurements that were associated with no significant risk of stress fractures were increased total bone mineral content and increased lumbar spine bone mineral density, both of which were studied only in females³. Increased femoral neck bone mineral content was studied only in males¹¹ and was also not significantly associated with increased stress fracture risk. Interestingly, lower limb bone mineral density, femur bone mineral density, tibia/fibula bone mineral density, and foot bone mineral density in males and females had no significant association with increased risk of lower extremity stress fractures³. Perhaps either the lumbar spine and femoral neck association is a type I error, or the lack of association with the lower extremity bones is a type II error. More research will have to be done to study the possible association or lack of association.

There is conflicting evidence on fitness level. Fitness level was assessed in different ways (previous athletic activity, ability to run at a certain pace, etc.) in various studies^{3,7,9,10,11}. In the studies done on military recruits, the influence of previous fitness could be due to the different activities people participated in prior to the military. For example, a runner or an individual who played a high impact activity sport prior to enlisting would have been accustomed to the impact associated with military training and may have had the base training to withstand the stresses. A swimmer, who is not used to the high force impact, may have put oneself at a higher risk for a stress fracture. In this review, none of the studies on runners included previous fitness level as one of their variables, so it was

difficult to compare the influence of this variable on military recruits and runners.

Different footwear did not correlate with increased risk of stress fractures³. In military recruits, footwear is often standard boots. Runners often choose their own footwear based on a variety of factors (looks, fit, comfort, shoe design). Looking at shoe type (or lack of shoes) and stress fracture incidence is an important future study.

We reviewed three articles on impact forces and plantar loading^{4,8,12}. It is important to note that the relationship between impact forces and stress fractures is still controversial, but we included these cases in this review. We classified these articles separately because they stated that the increased impact may be associated with the increased risk of stress fractures and were not considered direct risk factors. These articles all associated increased forces in certain areas of the foot with increased risk for stress fractures in those areas.

Nagel et al, who examined loading after running a marathon, found increased loading in the lateral forefoot⁸. This is interesting because runners typically suffer from stress fractures of the lateral metatarsals (metatarsals 2-5) and not the first ray. It is possible to make additional theoretical connections when looking at the data by Chuckpaiwong et al on arch height and plantar loading⁴. People with a high arch have increased lateral loading while those with a low arch have increased medial loading. This increased lateral loading may make them susceptible to lateral column metatarsal stress fractures and therefore increase their risk.

Williams et al studied arch structure and injury pattern in runners and concluded that high arched runners are more susceptible to bony injuries, lateral injuries, and ankle injuries while low arched runners were more susceptible to knee injuries, soft tissue injuries, and medial injuries¹². This is consistent with the other studies we included on plantar loading variables because high arched runners were theorized to suffer from lateral column metatarsal stress fractures due to the increased plantar pressure.

Most of the studies we reviewed did not correlate biomechanics with an increased risk for stress fractures. The only structural measurement that was associated with an increased risk of stress fractures was limb length discrepancy and this risk factor was only examined in one study in females³. Bennell et al's study showed that stress fractures occurred with equal frequency regarding limb length discrepancies but also made the point that these fractures do tend to occur more in the dominant

limb, which could possibly be due to greater usage of that limb³. External hip rotation⁷, different foot types (high and low arch)³, and the angle between the shaft and neck of the femur⁶ did not indicate significant increased risks for stress fractures, but they too were only examined in one study each.

It should be noted that all of the biomechanical factors except limb length discrepancy in females listed in table 1 were not significantly associated with increased stress fracture risk^{3,6}. This contradicts the biomechanical aspect of foot type studied in the three plantar loading articles^{4,8,12}. Although we found it applicable to include articles relating plantar pressure to lateral column loading, the direct relationship between plantar loading and stress fracture risks has not been established.

While our search terms included metatarsal stress fractures, we decided to include studies that discussed stress fractures of the entire lower extremity. We rationalized this because there were limited papers solely focused on the metatarsals, and the studies that did focus on the bones of the whole lower extremity had similar variables to those few studies focused on the bones of the foot. While we found numerous studies focused on the bones of the foot, they were not directly applicable as risk factors for stress fractures.

Some of the weaknesses of this literature review include limited database searching, inconsistent search terms, and inconsistent timeframes. We used these different search terms and timeframes because when we searched the American Journal of Sports Medicine, the results of a very narrow search within a smaller timeframe were significantly limited and not applicable. By broadening the search terms and timeframe of publication, we were able to find additional relevant studies. Many of the studies performed multiple statistical tests. This increases the risk of a Type I error. Therefore, some of the significant risk factors may have occurred by chance.

One potential problem with this review is the difficulty comparing runners and military recruits because military recruits with improved baseline fitness trained with military recruits of lesser baseline fitness. Runners, on the other hand, often train with people of equal fitness level. This is important because the decreased risk possibly associated with previous fitness level may be hidden in runners, who are often compared to people with an equal level of fitness. In addition, runners with a higher level of fitness often run longer and faster than less fit

runners; this may offset the potentially decreased stress fracture risk associated with improved fitness. It would be more significant to compare runners and their fitness level prior to assessing their risk factors for stress fractures to

see what impact this has, and then compare these results to military recruits. Unfortunately, we were unable to find any directly applicable literature that implemented these studies.

Group	Risk Factors Included	Number of Studies in which it was Significant	Number of Studies in which it was Non-Significant
Height and bone length 7	Height, tibial length, femur length	1 (MF+)	2 (MF-) 1 (F-)
Pre-study fitness 2,5,7,9,10,11	Timed running fitness level at start, running frequency prior to study, mileage prior to study; calf girth; participation in premenarchal training (females)	1 (MF+) 1 (F+) 1 (M+)	2 (MF-) 1 (F-)
Training during study 2,6,9	Weekly training hours, running distance, training mode		3 (MF-)
Footwear and training surface 2	Footwear, surface		2 (MF-)
Demographics 5,9,11	Age, gender, race/ethnicity		3 (MF-)
Start of Menarche 2	Age of menarche, delayed menarche, later age of menarche, years since menarche	2 (F+)	2 (F-)
History of Amenorrhea 2,6,9	Amenorrhea, Secondary amenorrhea, lower menstrual index, history of amenorrhea	3 (F+)	2 (F-)
Nutrition 6,7,9,10,11	Lower fat intake; current daily intake of proteins, carbohydrates, alcohol, caffeine, fiber, sodium, phosphorus; scores on EAT-40 test; higher 25OHD; calcium intake; serum 25OHD; urinary NTX-1; serum TRACP 5b; serum PINP; serum TOC; serum COC; BMI; higher calcium intake in relationship to total energy intake; regular daily calcium intake; higher serum PTH; decreased weight; risedronate	2 (F+) 1 (M+)	8 (MF-) 2 (F-) 11 (M-)
Bone density 2,5,6,11	Mean bone mineral density (BMD); total bone mineral content (BMC); upper limb BMD; thoracic spine BMD; lumbar spine BMD; lower limb BMD; femur BMD; tibia/fibula BMD; foot BMD; lumbar spine BMC; lumbar spine scan area; femoral neck BMC; femoral neck scan area; femoral neck BMD; trochanter BMC; trochanter BMD; total hip BMC; total hip BMD; broadband ultrasound attenuation; speed of sound calcaneus; decreased tibial width in medial lateral axis	2 (F+) 2 (M+)	4 (MF-) 2 (F-) 15 (M-)
Range of motion 5,6	Sit and reach; increased ROM; increased hip internal and external rotation; calf flexibility; range of ankle dorsiflexion	2 (MF+)	3 (MF-)
Biomechanical 2,6,7,12	Foot type; limb length discrepancy; angle between shaft and neck of femur; balance; reaction time	1 (F+)	4 (MF-)
Oral contraception and hormones 2,9,11	Contraceptives; Serum free testosterone; serum testosterone; serum estradiol; serum free estradiol; serum sex hormone binding globulin; genotype xbal; Pvull; number of CAG repeats of androgen receptor gene		2 (F-) 8 (M-)

Table 1: The measured variables from each study are grouped and listed. The number of studies in which they are a significant risk factor or not a significant risk factor are listed.

(MF-) indicates an insignificant finding for both genders

(MF+) indicates a significant finding for both genders

Conclusion

As a result of this review, the most consistently significant risk factor for stress fractures was amenorrhea. The factors associated with no significant risk for stress fractures are BMI, weight, and the use of oral contraceptives. This literature review provided us with amenorrhea as one variable that should definitely be taken into account when assessing a physically active individual's risk. However, we do not know the etiology or mechanism by which this variable increases one's risk for a stress fracture. This literature review demonstrates that new variables should be studied when assessing an individual's risk because any other variables that showed positive significance as a risk factor showed mixed results across the studies reviewed.

Author's Contributions

Both TS and JP conducted separate literature searches to obtain articles that met the review's criteria. TS created the data table that classified the variables as significant or non-significant for males or females. JP and TS jointly wrote the rest of the paper and contributed their ideas to the discussion section. Both authors read and approved the final manuscript.

Statement of Competing Interests

The authors of this systematic review declare that they have no competing interests.

References

1. Edwards BW, Gillette JC, Thomas JM, Derrick TR. Internal femoral forces and moments during running: Implications for stress fracture development. *Clinical Biomechanics*. 2008; 23: 1269–1278.
2. Farkas TA, Zane RD. Comminuted Femur Fracture Secondary to Stress During the Boston Marathon. *The Journal of Emergency Medicine*. 2006;31(No. 1): 79-82.
3. Bennell KL, Malcolm SA, Thomas SA, et al. Risk Factors for Stress Fractures in Track and Field Athletes – a Twelve Month Prospective Study. *The American Journal of Sports Medicine*. 1996;24(No. 6): 810-817.
4. Chuckpaiwong B, Nunley JA, Mall NA, Queen RM. The Effect of Foot Type on In-Shoe Plantar Pressure During Walking and Running. *Gait & Posture*. 2008;28: 405-411.
5. Giladi M, Milgrom C, Simkin A, Danon Y. Stress Fractures – Identifiable Risk Factors. *The American Journal of Sports Medicine*. 1991;19(No. 6): 647-652.
6. Korpelainen R, Orava S, Karpakka J, Siira P, Hulkko A. Risk Factors for Recurrent Stress Fractures in Athletes. *The American Journal of Sports Medicine*. 2001;29: 304-310.
7. Milgrom C, Finestone A, Novack V, et al. The Effect of Prophylactic Treatment with Risedronate on Stress Fracture Incidence Among Infantry Recruits. *Bone*. 2004;35: 418-424.
8. Nagel A, Fernholz F, Kibele C, Rosenbaum D. Long Distance Running Increases Plantar Pressures Beneath the Metatarsal Heads – A Barefoot Walking Investigation of 200 Marathon Runners. *Gait & Posture*. 2008;27: 152-155.
9. Shaffer RA, Rauh MJ, Brodine SK, Trone DW, Macera CA. Predictors of Stress Fracture Susceptibility in Young Female Recruits. *The American Journal of Sports Medicine*. 2006;34(No. 1): 108-115.
10. Sormaala MJ, Niva MH, Kiuru MJ, Mattila VM, Pihlajamaki HK. Bone Stress Injuries of the Talus in Military Recruits. *Bone*. 2006;39: 199-204.
11. Valimaki VV, Alfthan H, Lehmuskallio E, et al. Risk Factors for Clinical Stress Fractures in Male Military Recruits: A Prospective Cohort Study. *Bone*. 2005;37: 267-273.
12. Williams DS, McClay IS, Hamill J. Arch Structure and Injury Pattern in Runners. *Clinical Biomechanics*. 2001;16: 341-347.

Literature Review of Metatarsus Adductus in Children

Anshini Dalal, BS, Ana Pimentel-Tejeda, BS, and Alex Kim, MS

Abstract

Introduction:

The purpose of the study is to evaluate various ways in which metatarsus adductus is assessed and treated in children of different ages.

Study design:

Qualitative Systematic Review of the Literature

Methods:

An English language literature search was conducted using PubMed, Google Scholar and bibliographic review of textbook and review articles. The study involving metatarsus adductus in adult foot was excluded as our review focused on this condition in children. Review articles older than year 2001 were excluded as they presented old data. Exceptions were made for a 1998 publication of guidelines for assessment of podopediatric conditions¹¹, which was the most recent literature for that particular area, and articles referenced in Chapter 28 from the Comprehensive Textbook of Foot Surgery. Inclusion criteria included searching for published papers with metatarsus adductus diagnosis and treatment in early age group populations.

Results:

Ultimately, we obtained 10 articles from PubMed and Google Scholar that specifically addressed the purpose of the study. Chapter 28 from the Comprehensive Textbook of Foot Surgery was also used as a reference.

Conclusions:

Metatarsus adductus is a foot deformity that if recognized early can be treated for desirable results. With different methods available traditional methods are still preferred in both clinical and radiologic assessments. Treatment depends on the age and severity of the deformity. Mild and flexible forms are treated with serial casting immobilization. More severe metatarsal deviations need surgical intervention. If the deformity is not treated at an early age, it can affect the individual's management of daily activities. Further research is required to establish a more reliable form of assessment.

Key Words: metatarsus adductus, pediatrics, treatment, diagnosis

Level of Evidence: 4

Introduction

Metatarsus adductus is a foot deformity that if recognized early can be treated for desirable clinical outcomes.^{1,2,3} Metatarsus adductus (MTA) is one of the most common foot deformities, reported in one to two cases per 1,000 live births⁵. Metatarsus adductus is a transverse plane deformity in which the metatarsus is in an adducted position relative to the longitudinal axis of the lesser tarsus⁴. If left untreated or undertreated metatarsus adductus can lead to the formation of a skewfoot deformity. This can have very significant symptoms and has less chance of being successfully treated by non-operative means⁶. The term "skewfoot" has been commonly misrepresented leading to some confusion about the deformity itself. The term skewfoot was framed by McCormick and Blount in 1949 as another way of representing metatarsus adductus. Skewfoot is mostly reported in the literature simply as forefoot adduction and heel valgus⁷.

There are many theories that exist on the origin of metatarsus adductus. These may be

classified as "packaging defects" or "manufacturing defects". It is possible to have same clinical appearance from either of the defects⁸. Packaging defects refers to the intrauterine pressure in the womb before birth. Because metatarsus adductus is present at birth in most cases but is not observed in preterm infants, the intrauterine position has been suggested to play a significant role in the development of the deformity⁹. Manufacturing defect refers to a genetic association. This idea is supported by an increasing appearance of metatarsus adductus among siblings. However the inheritance pattern is still not clear. Multigenic inheritance with variable penetrance is likely to play a role⁸.

Muscle imbalance may also be involved in the development of metatarsus adductus. Some suggested anatomic causes are exaggerated plantar insertion of the tibialis anterior tendon, contraction of posterior tibialis tendon and abnormal insertion of abductor hallucis. Metatarsus adductus can be present in six different forms: simple metatarsus adduction, metatarsus adducto varus, metatarsus primus adductus, complex metatarsus adductus, a



component of talipes equinovarus, and cavoadducto varus.

Methods

An English language literature search was conducted using PubMed and Google Scholar using keywords “metatarsus adductus”, “pediatrics”, “children”, and “treatment”. Review articles on the topic “metatarsus adductus” and “skewfoot” were searched limited to year 2001 – 2011. Initial search on PubMed with keywords ‘metatarsus adductus’ resulted in 181 articles total. Other keywords added are ‘treatment’ and ‘children’, which resulted in 65 articles in total. Only the articles dated 2001 and above were considered for the review, with the exception of one relevant article published in 1998 by Connors et. al. This narrowed it down to 10 articles. Search on Google Scholar consisted of keywords “metatarsus adductus”, “pediatrics”, “treatment”, and “diagnosis” which resulted in 466 articles. Only the articles that specifically addressed the purpose of the study were selected. Bibliographic review of Comprehensive Textbook of Foot Surgery, vol. 1, chap. 28, pp. 915-940 was also used.

Results

By doing a literature search, we found articles that presented various diagnostic methods for the assessment of metatarsus adductus, including clinical exams and radiological exams specific for the pediatric population. The gold standard for treatment was found in McGlamry, Williams & Wilkins’ Comprehensive Textbook of Foot and Ankle Surgery, volume 1. Newer articles found through PubMed and Google Scholar presented other, more effective treatment options.

Discussion

Metatarsus adductus in children is often diagnosed clinically. The treatment options, which include non-invasive and surgical procedures, depend on the severity of the metatarsal deviation. On inspection of a child with metatarsus adductus, the toes angle abruptly toward the midline, creating a C-shaped lateral foot border with a prominent styloid process of the fifth metatarsal⁵. A splay can appear between the great and second toes. Skin examination frequently reveals a deep skin cleft at the medial midfoot¹⁰. Diagnosis can be based on two clinical tests and one radiological test.

Diagnosis

Diagnosis done through clinical examination is typically performed using the V-Finger test

and Bleck’s Method. The V-finger test is the first clinical exam done to detect metatarsus adductus. The heel of the foot is placed between the index and middle fingers (the V). Judging by the position of the foot relative to the middle finger, the degree of deviation of the lateral aspect of the foot can be evaluated. The greater the gap between the evaluator’s middle finger and the styloid process of the foot, the more severe the metatarsus adductus is¹¹. If the foot is manually correctable without force it is considered a mild deformity. If the deformity is only correctable with force, it is classified as moderate. A severe case is not manually reducible⁸.

The Heel- Bisector angle (Bleck’s Method) is typically the second clinical exam performed to assess metatarsus adductus. A longitudinal line bisects the heel and is extended distally. Normally, this line should extend through the second interdigital space. Connors et al. affirm that if the heel bisector extends through the third digit, it is considered mild. If the Heel bisector extends through the third interspace and the fourth toe, it is considered moderate. If the heel bisector is lateral to the fourth digit, it is severe¹¹. To make the diagnosis more clear, further examination is done with radiological assessment.

Radiological Assessment

Hutchinson⁷ agrees with previous authors who claim that radiographs are not essential to evaluate metatarsus adductus but may help to confirm the presence of complex deformities or the presence of rearfoot compensation. These authors claim that the age and flexibility of the deformity are better prognostic factors than radiographic findings, particularly because in toddlers and infants, this assessment may not be accurate due to lack of ossification⁷. However, Dawoodi and Perera¹² suggest that if metatarsus adductus is suspected and treatment is sought, radiological assessment is necessary, especially if surgical correction is being considered.

Upon taking a radiograph, there are several different angles measured, first of all, to differentiate metatarsus adductus from metatarsus primus varus, and secondly, to quantify the severity of the metatarsus adductus deformity¹². This quantification of severity is not a standard measurement because there have been several different authors that have proposed numerous different metatarsus adductus angles.

We are only aware of one publication by Dawoodi and Perera in March 2011¹² that

evaluates the various methods used to assess metatarsus adductus in an isolated manner from any other foot deformity, in an attempt to critically appraise the reliability of each angle measurement. Based on the literature reviewed, we noticed that most guidelines suggest practitioners rely mainly on the traditional metatarsus adductus angle (Figure 1) to assess metatarsus adductus.

As stated by Sgarlato from the California College of Podiatric Medicine in 1971, cited in the Radiological assessment of metatarsus adductus review¹², the metatarsus adductus angle is traditionally defined as the angle between the longitudinal axis of the metatarsus (this is usually represented by the axis of the second metatarsal) and the longitudinal axis of the lesser tarsus (navicular, cuboid and cuneiform bones). The longitudinal axis of the lesser tarsus is defined as a line perpendicular to the transverse axis of the lesser tarsus, a line connecting the midpoint of two lines defining the lateral and medial borders of the midfoot. The medial line extends between the medial extremes of the talonavicular and the first tarsometatarsal joint. The lateral line extends between the lateral extremes of the calcaneocuboid and the 5th metatarsal-cuboid joints¹².

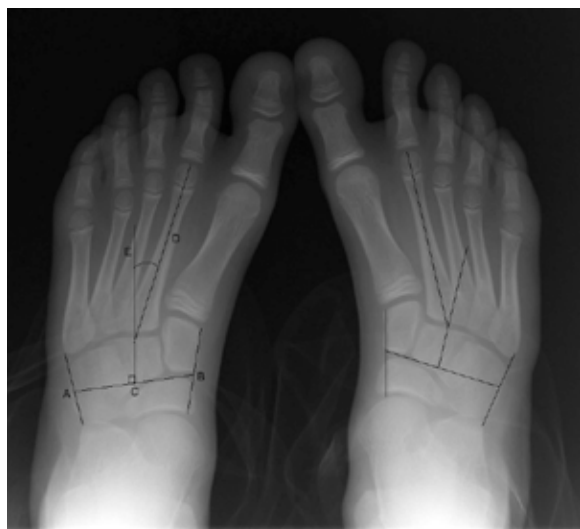

Figure 1. Metarsus Adductus in a Child

A) Traditional metatarsus adductus angle using the 4th metatarso-cuboid joint as a reference. The line is drawn from the most lateral point of the calcaneocuboid joint and the most lateral point of the fifth metatarso-cuboid joint. **B)** Traditional metatarsus adductus angle using the 5th metatarso-cuboid joint as a reference. The line is drawn from the most distal medial point of the first cuneiform and the most medial point of the talonavicular joint.

An example of this traditional metatarsus adductus angle measurement can be seen in figure 1. In 1992, Ganley and Ganley were particularly notable for addressing the problem of using just the traditional metatarsal adductus angle to measure foot deformities in pediatrics due to the lack of fully ossified lesser tarsal and metatarsal bones⁸ and suggested that the calcaneus be used as a reference point, since its primary ossification center is already complete by birth. Moreover, they stated that the talus is the foot structure that has the most constant relationship with the leg in terms of rotation and alignment⁸. For this reason, Ganley and Ganley preferred the talocalcaneal angle of divergence, known as the Kite's angle (shown in figure 2), as a site to start measuring any foot abnormalities, starting with the hindfoot. The angle is between the longitudinal axis of the talus and a line that is parallel to the lateral border of the calcaneus. If this angle is between 20-25 degrees, rearfoot deformities can be ruled out and further angle assessments can be used to determine the degree of metatarsus adductus⁸. In 1998, several faculty members from the Department of Pediatrics at the New York College of Podiatric Medicine and the Foot Clinics of New York outlined the use of just the traditional metatarsus adductus angle and Kite's angle as a way of radiographically assessing metatarsus adductus¹¹.

There are several other angles that have been studied by other authors to assess the metatarsal deviation, such as the talo-first metatarsal angle and the calcaneal-fifth metatarsal angle. Some authors also suggest that assessment of hip and knee range of motion should be a standard part of the examination, as torsional abnormalities need to be considered in patients with metatarsus adductus. Many of the alternative assessments, in the attempt to be more accurate in measurement, are thought to be far too cumbersome to use in assessment¹². Several are also associated with measurements used to assess other foot deformities, and thus are not useful to diagnose solely metatarsus adductus. These angles are succinctly outlined in Table 1¹² of Dawoodi and Perera's Radiological assessment of metatarsus adductus. There have not been enough studies to critically appraise the reliability of the methods currently used nor the methods suggested by a minority of authors to assess metatarsus adductus¹². Although this may suggest that the radiological assessment of the deformity is weak and not as reliable as desired, it is still included as a standard part of the assessment. This is done to

get an estimate of the deviation of the forefoot in children with incompletely ossified foot bones.

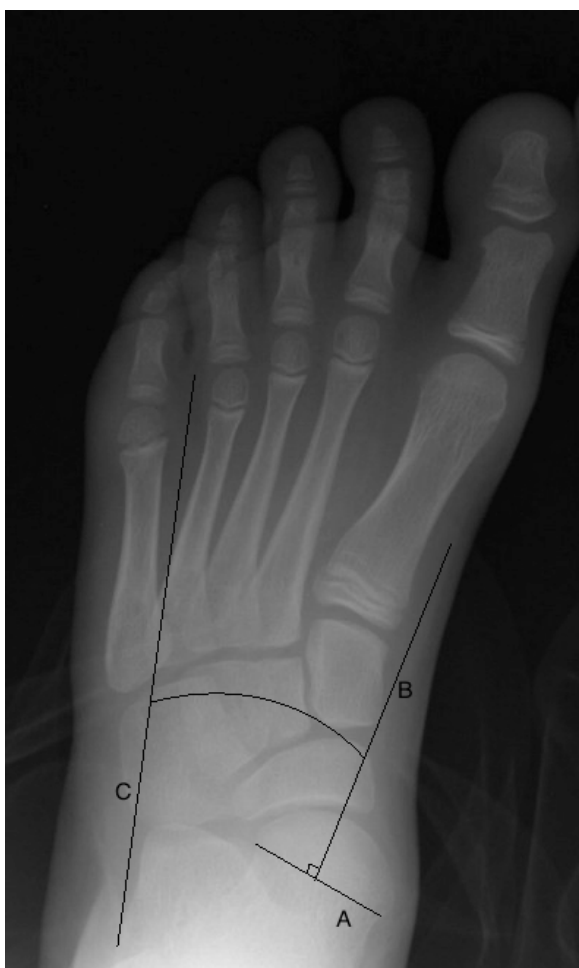

Figure 2. Kite's Angle

Line A transverses the neck of the talus and is perpendicular to B, the longitudinal axis of the talus. Line C is parallel to the lateral border of the calcaneus. If hindfoot deformities are ruled out, Kite's Angle helps determine degrees of metatarsal deformities.

Treatments: Non-surgical and Surgical Correction

Agnew mentioned, "In the absence of a reliable prognostic indicator or test, the decision whether to treat and how to treat a patient with metatarsus adductus remains more of an art than a science"⁸. There are numerous treatments proposed based on a patients' age and severity of deformity⁷. Also, there are many articles that emphasize the importance of early treatment⁷. Early on, manipulation tends to be done before any other treatment. However, this has recently been discouraged because there is possibility that this could induce a new deformity

in the developing infant foot⁸. Serial casting, splinting and shoe therapy have been considered conservative therapy options for children.

Serial casting is a common method of treatment for infants from birth to nine months old⁸. There are two popular types of casting commonly used, extra-fast-setting plaster and fiberglass tape. Physicians prefer plaster because it is more precisely moldable and easily removed by family¹³.

The use of splints has been recommended for use after cast correction for retention of the corrected position⁸. They are also suggested for use before considering surgical correction. The Wheaton Brace is a removable, plastic version of a stretch cast that is now commonly used¹⁴.

Shoe therapy has fallen out of favor as therapeutic treatment because casting and splinting are more effective. Moreover, shoe therapy has been shown to actually induce rearfoot pronation, since the shoe is not able to control the rearfoot while it corrects the forefoot¹⁵.

The aforementioned treatments are considered to be conservative. Failure of these therapies in children older than 2 years of age may indicate the need for surgery¹⁶. There are two different types of surgical therapies considered. One is soft tissue release, targeted for early age corrections. Other types of surgical corrections are osseous procedures typically recommended for older children, adolescents, and adults⁸.

Soft tissue release procedures are most effective when done anytime between birth and about 6 years of age. Generally, surgeons do either an abductor hallucis or tarsometatarsal release⁸. Abductor hallucis release can be done in one of three ways: sectioning, lengthening, or removing the tendon. The preferred method is sectioning because it has been reported to yield the best results¹⁷⁻¹⁸. Thompson and Simmons mentioned that after abductor hallucis release, the metatarsus adductus is corrected, however, if the patient also had a hallux varus deformity, it may persist until roughly age 12 when it spontaneously resolves¹⁹. It has been noted that the persistence of this hallux deformity is often due to weight bearing⁸.

There are two different types of osseous surgical procedures, metatarsal osteotomies and tarsal osteotomies, which are done if soft tissue release would not be sufficient to correct the deformity⁸. Metatarsal osteotomies are recommended for patients older than six years old. There are different technical approaches that have been suggested by many doctors over

the years. In 1966, Steytler and Van der Walt described a now popular oblique V-shaped osteotomy that is done at the bases of each metatarsal with the apex of the "V" angled toward the rearfoot²¹. This procedure has been modified today to include wire and screw fixation⁸. There had been concerns about this procedure because there had been cases of under- and over-correction. Therefore more recently, in 1981 Lepird described a transverse plane osteotomy of the second through fourth metatarsal bases²².

Tarsal osteotomies are preferred by many surgeons if a tarsal deformity is also present²³. Ganley and Ganley suggested that for patients older than seven years old a cuboid and medial cuneiform osteotomy be done²⁴.

Ganley and Ganley mentioned the advantages and disadvantages for metatarsal osteotomies versus tarsal osteotomies. They suggested that tarsal osteotomies are best because these procedure avoid the first metatarsal physis, the tarsal area has greater blood supply for bone healing, and cuneiform deformities are easier to correct because of the broad contact area. The potential disadvantages for tarsal osteotomies are that there is a risk of severing the tibialis anterior tendon that lies in the vicinity²⁴.

In all surgical corrections of metatarsus adductus, casting is done post-operatively to ensure proper realignment in both tarsal and metatarsal osteotomies⁸.

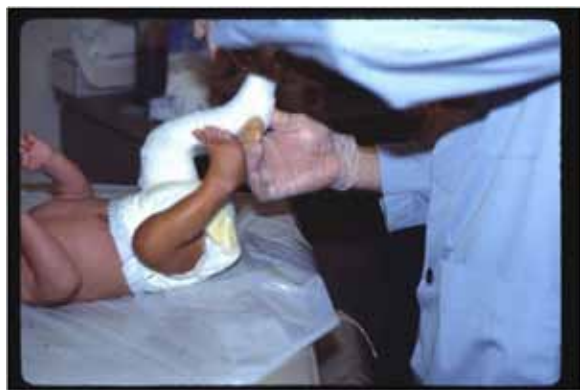

Figure 3. Non-surgical corrective therapy using plaster cast in an infant.

Conclusion

Metatarsus adductus is a foot deformity that, if diagnosed early, can be corrected. Early detection and treatment can result in favorable long-term outcomes. Diagnosis is usually done by clinical and radiological assessment. Clinical assessment is done by using the V-Finger test and the Bleck's method of using a heel bisector. The standard radiological assessment commonly done uses the traditional metatarsus adductus angle, however, the accuracy of this assessment is controversial because of the lack of ossification in young children's lesser tarsal bones. There have been many other methods suggested by several authors, but these methods are said to be either too cumbersome or not significantly better at measuring the deformity than the traditional metatarsus adductus angle. Therefore it seems that further research is required to establish a more reliable form of assessment that could better account for the lack of ossification while using proper angles to measure the deviation.

Mild and flexible forms of metatarsus adductus are commonly treated with serial cast immobilization and wearing of the Wheaton Brace. Failure of these conservative therapies may indicate the need for surgical intervention. Soft tissue release procedures are the most effective if done before the age of six⁸. If the soft tissue release is not sufficient, osseous procedures such as metatarsal osteotomies and tarsal osteotomies are done⁸. If the deformity is not treated it can affect the individual with his or her daily activities.

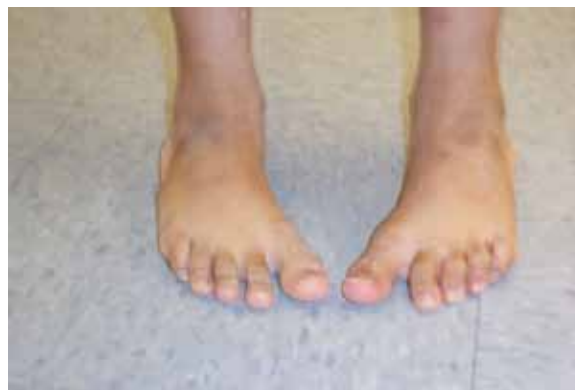

Figure 4. Bilateral Metatarsus Adductus

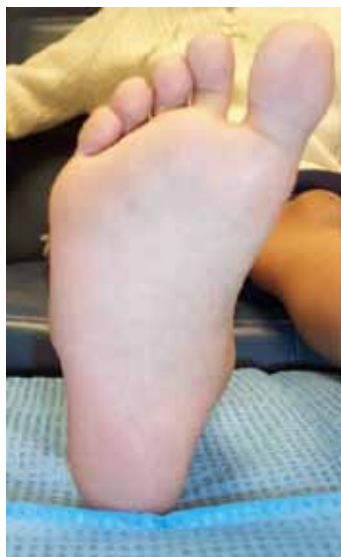

Figure 5. Prominent styloid process of the 5th metatarsal bone is evident on observation.

Acknowledgements

The authors extend their thanks to the following faculty members from the New York College of Podiatric Medicine: Dr. Logan and Dr. Resseque for contributing pictures to this study and Dr. Dykyl for help in radiologic assessment.

Authors' Contribution

AD, AP, and AK conceived the design of the study and drafted the manuscript. AP conceived the design of the study and drafted the manuscript. All authors read and approved the final manuscript.

Statement of Competing interests

The authors disclose that there are no competing interests. There are no financial or personal relationships with other people or organizations that could inappropriately influence the production of this paper.

References

1. Farsetti P, Weinstein SL, Ponseti IV. The long-term functional and radiographic outcomes of untreated and non-operatively treated metatarsus adductus. *J Bone Joint Surg Am* 1994;76(2):257-65.
2. Ponsetti IV, Becker JR. Congenital metatarsus adductus: the results of treatment. *J Bone Joint Surg Am* 1996;48:702.
3. LaPorta G, Sokoloff H. Metatarsus adductus: a two-year follow up of 22 cases. *Hershey update* 1980;1.
4. Harley BD, Fritzhand AJ, Little JM, et al. Abductory midfoot osteotomy procedure for metatarsus adductus. *J Foot Ankle Surg* 1995;34(2):153-62

6. Dietz FR. Intoeing—fact, fiction and opinion. *Am Fam Physician* 1994;50:1249-59, 1262-4.
7. Wan SC. Metatarsus adductus and skewfoot deformity. *Clin Podiatr Med Surg* 2006;23(1):23-40.
8. Byron Hutchinson, DPM, FACFAS. Pediatric Metatarsus Adductus and Skewfoot Deformity. *Clin Podiatr Med Surg* 2010;27(1):93-104
9. Yu, G. V., Wallace, G. F. Metatarsus adductus, Ch. 28. In: E. D. McGlamry, Williams & Wilkins, eds *Comprehensive Textbook of Foot Surgery*, vol. 1, Baltimore, 2001 : 915-940
10. K. Katz, N. Naor and P. Merlob, et al. Rotational deformities of the tibia and foot in preterm infants. *J Pediatr Orthop* ,1990; 10
11. Gore, A. I., & Spencer, J. P. The newborn foot. *American Family Physician*, 2004, 69: 865-872.
12. Connors JF, Wernick E, Lowy LJ, Falcone J, Volpe RG. Guidelines for evaluation and management of five common podopediatric conditions. *J Am Podiatr Med Assoc* 1998; 88:206-22.
13. Dawoodi AIS, Perera A. Radiological assessment of metarsus adductus. *Foot Ankle Surg* (2011), doi: 10.1016/j.fas.2011.03.002
14. Bowker P, Powell ES. A clinical evaluation of plater of Paris and eight synthetic fracture splinting materials. *Injury* 1992;23:13-20
15. Scherl SA. Common Lower Extremity Problems in Children, *Pediatrics in Review* 2004; 25:52
16. Tachdjian MO. *Pediatric orthopedics*, vol 2. Philadelphia: WB Saunders, 1972:1323.
17. Yu GV, Johng B, Freireich R. Surgical management of metatarsus adductus deformity. *Clin Podiatr Med Surg* 1987;4:207-232.
18. Lowe LW, Hannon MA. Residual adduction of the forefoot in treated congenital clubfoot. *J Bone Joint Surg Br* 1973;55:809-813.
19. Thomson SA. Hallux varus and metatarsus varus: a five year study (1954-1958). *Clin Orthop* 1960;16:109-118.
20. Thomson GH, Simons GW. Congenital talipes equino varus (clubfeet) and metatarsus adductus. In: Drennan JC, ed. *The child's foot and ankle*. New York: Raven Press, 1992.
21. Heyman CH, Herndon CH, Strong JM. Mobilization of the tarsometatarsal and intermetatarsal joints for correction of resistant adduction of the forepart of the foot in congenital clubfoot or congenital metatarsus varus. *J Bone Joint Surg Am* 1958;40:299-310.
22. Steyler JCS, Van Der Walt IB. Correction of resistant adduction of the forefoot in congenital club-foot and congenital metatarsus varus by metatarsal osteotomy. *Br J Surg* 1966;53:558-560.
23. Yu GV, Wallace GF. Metatarsus adductus. In: McGlamry ED, ed. *Comprehensive textbook of foot surgery*, vol 1. Baltimore: Williams and Wilkins, 1987:324-353.
24. Fowler SB, Brooks AL, Parrish TF. The cavovarus foot. *J Bone Joint Surg Am* 1958;41:757.
25. Ganley JV, Ganley TJ. Metatarsus adductus deformity, In: McGlamry ED, Banks AS, Downey MS, eds. *Comprehensive textbook of foot surgery*, 2nd ed. Baltimore: William and Wilkins, 1992:829-852.
26. Root ML, Orien WP, Weed JH. *Normal and abnormal foot function of the foot*. Los Angeles, CA: Clinical Biomechanics Corporation; 1977.

Bisphenol A and its Contribution to the Onset of Diabetes Mellitus

Jonathan R. Roy, MS, Cailin N. Rubino, BS, Todd M. Chappell, BA

Abstract

Introduction:

Diabetes mellitus (DM) is an incurable disease plaguing the world with an ever-increasing prevalence. The xenobiotic bisphenol A (BPA), a synthetic estrogen, has been shown to be a strong contributing factor to the onset of DM in epidemiological studies as well as those using murine models. DM increases the likelihood and development of many of the morbidities diagnosed and treated in podiatric practice. Thus, environmental factors such as BPA are appropriate to consider when discussing risk factors for DM. Prevention of such exposures should be taken into consideration to reduce this risk.

Study Design:

Qualitative Systematic Review of the Literature

Methods:

Two PubMed advanced literature searches were performed on the inclusionary terms "Diabetes" and "Bisphenol A AND Diabetes", respectively. Articles were then screened by abstract review based on relevance to the inclusionary criteria of PAD, insulin, diabetic costs, prevalence (primary search), and Bisphenol A (secondary search). Two website resources, American Diabetes Association (ADA) and Center for Disease Control (CDC), were used based on the same inclusionary criteria. A total of 14 sources were incorporated into the study.

Results:

Bisphenol A was found in many foods, plastics, and many other commonly encountered environmental objects at levels that affect pancreatic beta cell function. BPA was found to mimic 17 β - estradiol on beta cell estrogen receptor- α , thereby causing overstimulation of the secretory cells. This causes hyperinsulinemia, as well as exhaustion and apoptosis of beta cells leading to diabetes mellitus. BPA has been shown to leak out of containers and be present at biologically active levels in 63 of 105 different tested food sources.

Conclusions:

The current literature used in this systematic review confirms a strong correlation between BPA and the onset of diabetes mellitus. Ethical restrictions do not allow human trials but we believe these studies draw parallels and correlations that are strong enough to necessitate a higher regard for this ubiquitous environmental contaminant.

Key Words: diabetes, bisphenol A AND diabetes

Level of Evidence: 4

Introduction

Diabetes Mellitus (DM) has become a major public health concern throughout the world and is rapidly increasing in prevalence. The World Health Organization (WHO) estimates that over 180 million people in the world have diabetes⁽¹⁾. This number is expected to climb to over 300 million by the year 2030⁽²⁾. Type 2 diabetes mellitus (T2DM) contributes significantly to morbidity through various complications including peripheral neuropathy, angiopathy, poor wound healing, and diabetic foot ulceration, which can lead to lower extremity amputation or death⁽³⁾. Type 2 diabetes mellitus alone is responsible for 2.9 million deaths per year⁽¹⁾. Some causes of DM include the destruction of pancreatic beta cells by an autoimmune mechanism as in type 1 diabetes, genetic predisposition and lifestyle as in type 2 diabetes, and the hormones of pregnancy which lead to

insulin resistance in the mother as in gestational diabetes⁽¹⁰⁾.

Diabetes Mellitus develops as a result of pancreatic insufficiency in making enough insulin to maintain normal glucose metabolism. Major characteristics include reduced pancreatic beta cell function and insulin resistance by peripheral tissues, which decreases glucose uptake. Hyper-secretion of insulin ensues in order to maintain glucose homeostasis. Beta cell compensation for insulin resistance often fails due to mitochondrial dysfunction and/or endoplasmic reticulum stress, which leads to apoptosis and ultimately T2DM⁽²⁾.

Environmental contaminants and xenobiotics need to be seriously considered for their contribution to the etiology of DM. It has been shown in various studies that bisphenol A (BPA) has a direct correlation to the onset of DM. Bisphenol A is one of the chemicals produced in

the highest volumes worldwide with 7 billion pounds produced annually, and 100 tons released into the atmosphere^(4,5). It is a chemical monomer found in polycarbonate plastic containers and epoxy resin linings of aluminum cans. It is also found in food, drinks, air, dust, and soil. BPA is a synthetic environmental estrogen, which imitates the endogenous hormone 17 β -estradiol(E2)⁽¹⁾. Both E2 and environmental BPA interact with estrogen receptor- α (ER α) existing on pancreatic beta cells whose main functions are biosynthesis and release of insulin⁽⁶⁾. If ER α is over-stimulated by 17 β -estradiol or BPA, the result will be excessive insulin signaling and hyperinsulinemia⁽⁶⁾. Secretion of insulin from beta cells requires folding, exportation, and processing of the insulin by the endoplasmic reticulum; excessive stimulation would impair beta cell function and increase beta cell death⁽²⁾. The purpose of this review article is to determine the effects that various levels of BPA had on pancreatic beta cell function, ultimately leading to the onset of diabetes mellitus. Moreover, it is to add BPA exposure to the many known factors which increase one's risk of developing diabetes mellitus that are often overlooked by clinicians

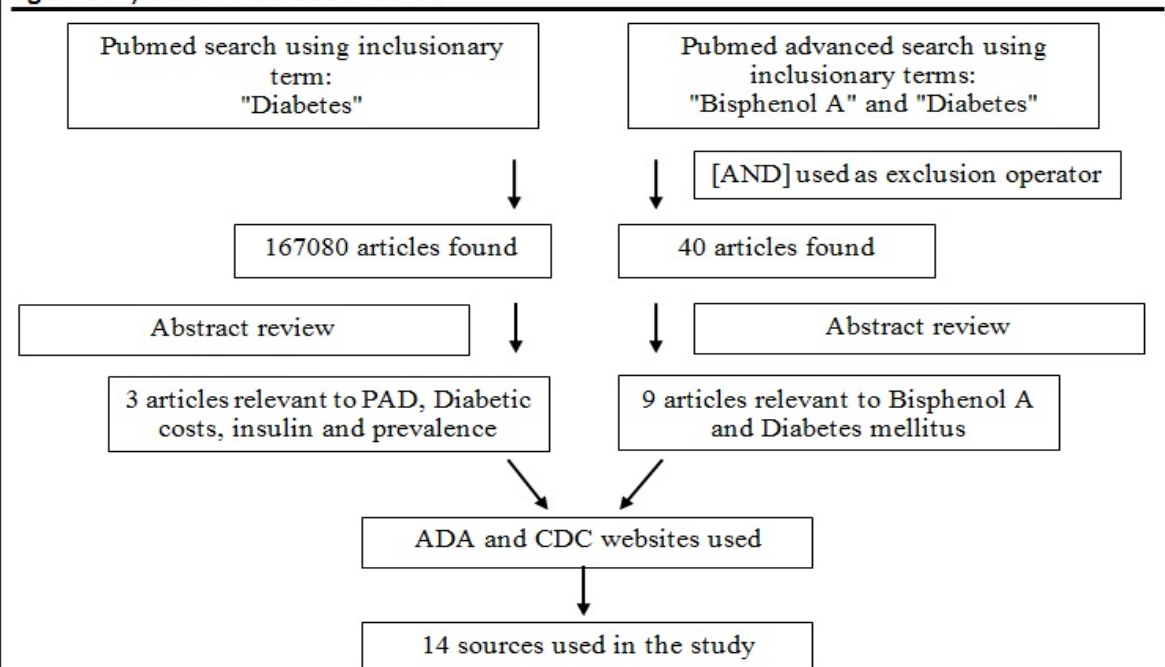
and misunderstood in the scientific community.

Methods

An advanced search was performed on the PubMed database using the inclusionary criteria terms "Bisphenol A" and "Diabetes". The exclusionary operator [AND] was used to limit the results to articles related to both keywords. Forty articles met the search criteria, of which all abstracts were reviewed. Nine articles were selected based on relevance to bisphenol A and factors linked to diabetes mellitus. A second search was performed on the PubMed database with the inclusion search term "Diabetes". 167080 articles were found in the search.

Articles were reviewed and selected based on the inclusion criteria of peripheral arterial disease, diabetic costs, and prevalence of disease. The exclusion criteria were articles that did not correlate bisphenol A to diabetes in the preliminary search. General information regarding diabetes mellitus was obtained from The American Diabetes Association website and the Centers for Disease Control and Prevention website. A total of 14 sources were incorporated into this study (Fig. 1).

Figure 1: Systematic Literature Search



Two PubMed advanced literature searches were performed on the inclusionary terms "Diabetes" and "Bisphenol A AND Diabetes", respectively. Articles were then screened by abstract review based on relevance to the inclusionary criteria of PAD, insulin, diabetic costs and prevalence (primary search) and Bisphenol A (secondary search). Two website resources, American Diabetes Association (ADA) and Center for Disease Control (CDC) were used based on the same inclusionary criteria. A total of 14 sources were incorporated into the study

Results

Schechter et al. performed a study on the amount of BPA that was found in 105 different food products intended for use by humans, cats, and dogs which includes canned foods, plastic wrapped foods, fresh meat, and fresh fish. BPA levels were measured which demonstrated the ubiquitousness of BPA by detecting levels in U.S. foods. BPA was found in 63 of the 105 foods sampled in this study, which included fresh vegetables such as green beans, various canned soups, chili, meat, fish, juice, grains, fruit, vegetables, infant formula, and animal food⁽⁵⁾. Similarly, the study by Groff reviewed several animal and human studies conducted on BPA and several health effects that were seen, suggesting possible links to heart disease and T2DM⁽⁴⁾. Groff likewise reported the ubiquitousness of BPA. It was found to be in canned food, soda, liquid infant formula, intravenous tubing, medical equipment, toys, pacifier shields, sales receipts, lottery tickets, recycled paper products, plastic containers, power plugs, indoor and outdoor air, dust, thermal paper, dental sealants, and drinking water. This study concluded that increased temperature, increased acidity, and damaged surfaces such as scratches increase BPA migration from containers. Groff concluded that BPA, as studied in animals, has laid a foundation for the hypothesis that it also has a variety of endocrine effects in humans which has been supported by numerous cross sectional studies⁽⁴⁾.

The review article by Nadal et al. focused on various studies of BPA and its functions that trigger an effect based on high or low concentrations of estrogen. The study focused on BPA's mode of action, its effect on ER- α leading to an increase in insulin biosynthesis, insulin resistance, beta cell exhaustion and development of T2DM⁽⁶⁾. Nadal et al. declared that the estrogen receptors used in blood glucose homeostasis that are altered by BPA are key to the understanding of the development of T2DM as well as recognizing the two main causes of beta cell failure in T2DM as overeating and lack of exercise⁽⁶⁾.

Ropero et al. conducted a review of studies done on beta cells in vitro and on mice in vivo. One study analyzed BPA effects on insulin releasing beta cells and glucagon releasing alpha cells within freshly isolated islets of Langerhans, while the other study, done in vivo, analyzed single BPA injections and its effects on plasma insulin and glycemia⁽¹⁾. Ropero et al. extrapolated from previous studies that determined the necessary content of BPA in

human serum to affect alpha and beta cells to be 0.9–8.8 nm. It was also found that a concentration of only 1 nm BPA is able to produce sufficient effect in beta cells to induce a hyperinsulinemic state and eventual insulin resistance by imitating the endogenous hormone 17 β -estradiol on the estrogen receptor alpha on pancreatic beta cells⁽¹⁾.

Makaji et al. performed a study on beta TC-6 mouse cell line function to determine the effect of BPA on insulin release. The study by Makaji et al. indicated that BPA directly affects beta cell function via ER stress due to chronic overstimulation of secretory cells leading to an up-regulation of chaperone proteins (HSP70, GRP78, and GRP94).

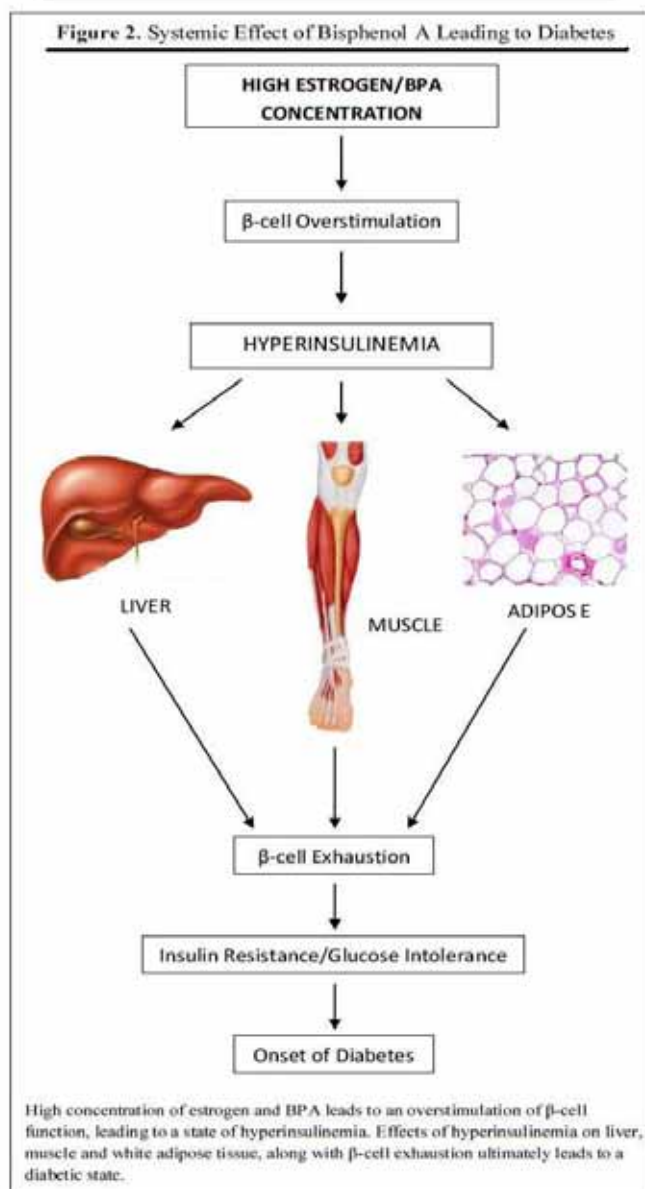
Alonso-Magdalena et al. performed an experiment on Swiss albino OF1 male mice. Estrogen (E₂) and BPA were injected intraperitoneally. Blood glucose and plasma insulin release were analyzed using glucose tolerance tests and fluorescent immunocytochemistry of the beta cells⁽⁸⁾. They demonstrated that merely four days of treatment with BPA induced an increase in beta cell insulin content (hyperinsulinemia) and altered glucose tolerance tests. They confirmed that BPA leads to a down-regulation of glucose transporters inducing insulin resistance secondarily to chronic hyperinsulinemia^(2,8).

Ryan et al. conducted a mouse study using CD-1 mice. All animals were kept in controlled environments. One group was given a control diet and two other groups were fed DES and BPA, respectively. This study determined whether or not prenatal exposure to BPA led to a predisposition to obesity or glucose intolerance. It indicated that accelerated growth was present early in life but concluded that this increase did not continue into later life and did not affect glucose tolerance⁽⁷⁾.

There was only one relevant article that pertained to human subjects, rather than mice. The review article by Meeker compiled epidemiological studies conducted using existing data of human male exposure to polychlorinated biphenyls (PCBs), pesticides, phthalates, BPA, and polybrominated diphenyl ethers (PBDEs) and their effects on human male health⁽⁹⁾. With respect to the findings related to BPA, there was an analysis that revealed that urinary concentrations of BPA were associated with increased risk of diabetes, cardiovascular diagnoses, and abnormal liver enzymes. Because these results indicate that BPA is associated with adverse health effects in humans, there is a definite need for more epidemiological research.

Discussion

Based on the studies reviewed, it is evident that bisphenol A plays a critical role as a viable risk factor for the onset of diabetes mellitus. It was demonstrated that BPA directly affects beta cell function through stress on the endoplasmic reticulum due to chronic overstimulation of secretory cells. BPA was shown to be a 17β -estradiol mimicker and elicit the same effects as endogenous estrogen¹. Bisphenol A was shown to be an important contributor that has been linked to the onset of DM in human populations by mimicking estrogenic signaling on the pancreatic beta cells. The resultant effect is consistent with the majority of reports in the literature in which BPA results in hyperinsulinemia, ultimately leading to the onset of diabetes mellitus (Fig 2).



The Makaji study results pertaining to the 50 fold increase in insulin secretion, increase in heat shock protein (HSP70), and down regulation of chaperone proteins (GRP78 and GRP94) indicate that chronically over-stimulated secretory cells will cause proteins to enter the endoplasmic reticulum more rapidly and be folded at an increased rate. This over-stimulation, which was caused by BPA, adds stress to the endoplasmic reticulum and the cell in general, which is seen by the increase in the heat shock protein HSP70. The severity of the stress is indicated by the 24 and 48-hour decrease of the other named chaperone proteins (GRP78 and GRP94), which indicates that the over-stimulated cells underwent apoptosis. The apoptosis of the secretory pancreatic beta cells has been shown to be a direct cause of DM⁽²⁾. Therefore, the estrogenic effects of BPA in causing apoptosis of secretory pancreatic beta cells is not only indicated as a potential risk factor for DM, but also as a direct influence to the onset of DM.

Additionally, BPA was shown to lead to a down-regulation of glucose transporters which induced insulin resistance secondary to chronic hyperinsulinemia. Nadal et al. indicated that BPA is a factor exacerbating and accelerating the development of DM by in vivo studies of BPA treated healthy adult male mice at environmentally relevant doses. This is also strong evidence that BPA should be considered a danger in terms of acquiring DM⁽⁶⁾.

Dr. Groff warned against the exposure to BPA but also indicated that there is not sufficient evidence to justify drastic changes in lifestyle until further research comes to a more definitive conclusion⁽⁴⁾. Schechter et al. indicated that further study should be directed at identifying the major sources of BPA in foods and their packaging⁽⁵⁾. Furthermore, the human epidemiological studies reviewed by Meeker showed an association between BPA concentrations and increased risk for diabetes, cardiovascular diagnoses, and abnormal liver enzymes.

Overall, these studies demonstrate the need for more research in order to strengthen the relationship between exposure to BPA and DM, as well as other adverse health outcomes. The lack of human studies is a limitation, which prevents significant animal data to make regulatory changes with BPA and the environment. Without it, a strong case against BPA cannot be made against human health hazards. Investigation of other potential pathways which lead to increasing levels of exposure to BPA can direct improvements in the

way U.S. food is processed, packaged, and to whom it is administered.

While there has been solid evidence of the relationship between BPA and DM in mice, further investigation, such as longitudinal studies, should be carried out that explore the relationship in humans due to the fact that BPA is ubiquitous in our environment and that the incidence and prevalence of DM is rapidly increasing worldwide. DM has numerous secondary problems associated with it, which are diagnosed by clinicians. However, few scientists and clinicians take environmental pollutants such as BPA into consideration when identifying risk factors for the development of DM in their patients. The lack of clinical and animal research, along with contradicting results has made the clear knowledge of BPA difficult to reach the general public. Understanding the mechanistic pathways of causation toward DM is crucial, as is considering any and all contributors to this disease that can potentially be avoided. BPA should therefore be taken into consideration when focusing on causative agents of DM and communities should be informed of all possible adverse effects from exposure.

Conclusions

DM is the seventh leading cause of death in the United States⁽¹¹⁾. Needless to say, it has a profound effect on the overall health of the human body. Over time, DM has the potential to create neurological, cardiovascular, renal, metabolic, ophthalmic, and peripheral vascular complications. The risk of diabetic patients to experience complications associated with peripheral arterial disease (PAD) is increased four-fold when compared to the non-diabetic population and has a direct impact on the health of the lower extremity⁽¹²⁾. PAD is the complication that is most costly associated with DM, carrying the economic burden of this debilitating disease and its complications up to 2.3 times higher than expenditures that would be incurred by the same patient in the absence of diabetes⁽¹³⁾. Although the cost alone is alarming, more importantly, these complications place the diabetic patient with twice the risk of death than that of people of similar age but without DM⁽¹¹⁾.

The studies highlighted in this review point to the ever increasing evidence of the adverse affects of BPA and specifically of its influence on the evolution towards the development of DM. It was noted by Beaser et al. that the estimated prevalence of DM in 2025 will represent a 72% increase in the prevalence of DM when compared to 2003⁽¹⁴⁾. This alarming rise in the

prevalence of DM coupled with the toll of the disease and its complications should cause a change in the way we view those factors, which contribute to the onset of the disease. Based on our findings, we conclude that there is substantial evidence linking bisphenol A as a contributing factor to the onset of DM. It is evident that our environment plays a crucial role. Although there are limitations to experimental studies available in humans, the current evidence should not be disregarded as epidemiological studies have shown parallel results. As we work to understand the many mechanisms, which lead to the onset of DM, it is important that we recognize and eliminate those factors, which show a strong association so that we can begin to slow the trend of increasing prevalence. Therefore bisphenol A should be taken into consideration when relating risk factors to the onset of diabetes mellitus and should be of concern to medical professionals and the general public.

Authors' Contributions

JR conceived the design of the study, performed the PubMed advanced search and evaluation of abstracts, designed figures, and drafted the manuscript. CR participated in the design of the study, participated in the PubMed advanced search and evaluation of abstracts, and helped draft the manuscript. TC participated in the design of the study and helped draft the manuscript. All authors read and approved the final manuscript.

Statement of Competing Interests

We (JR, CR, and TC) declare that we have no competing interests in relation to this manuscript.

References

1. Ropero AB, Alonso-Magdalena P, Garcia-Garcia E, Ripoll C, Fuentes E, Nadal A. Bisphenol-A disruption of the endocrine pancreas and blood glucose homeostasis. *Int J Androl.* 2008;31(2):194-200.
2. Makaji E, Raha S, Wade MG, Holloway AC. Effect of environmental contaminants on Beta cell function. *Int J Toxicol.* 2011;30(4):410-8.
3. Szabad G. [Diabetic foot syndrome]. *Orv Hetil.* 2011;152(29):1171-7.
4. Groff T. Bisphenol A: invisible pollution. *Curr Opin Pediatr.* 2010;22(4):524-9.
5. Schecter A, Malik N, Haffner D, Smith S, Harris TR, Paepke O, et al. Bisphenol A (BPA) in U.S. food. *Environ Sci Technol.* 2010;44(24):9425-30.
6. Nadal A, Alonso-Magdalena P, Soriano S, Quesada I, Ropero AB. The pancreatic beta-cell as a target of estrogens and xenoestrogens: Implications for blood glucose homeostasis and diabetes. *Mol Cell Endocrinol.* 2009;304(1-2):63-8.

7. Ryan KK, Haller AM, Sorrell JE, Woods SC, Jandacek RJ, Seeley RJ. Perinatal exposure to bisphenol-a and the development of metabolic syndrome in CD-1 mice. *Endocrinology*. 2010;151(6):2603-12.
8. Alonso-Magdalena P, Morimoto S, Ripoll C, Fuentes E, Nadal A. The estrogenic effect of bisphenol A disrupts pancreatic beta-cell function in vivo and induces insulin resistance. *Environ Health Perspect*. 2006;114(1):106-12.
9. Meeker JD. Exposure to environmental endocrine disrupting compounds and men's health. *Maturitas*. 2010;66(3):236-41.
10. Diabetes Basics - American Diabetes Association. Available at http://www.diabetes.org/diabetes-basics/?loc=GlobalNavDB_ Accessed 26 March 2012.
11. Centers for Disease Control and Prevention. National diabetes fact sheet: national estimates and general information on diabetes and pre-diabetes in the United States, 2011. Atlanta, GA: U.S. Department of Health and Human Services, Centers for Disease Control and Prevention, 2011.
12. Maly R, Chovanec V. Peripheral arterial disease and diabetes. *Vnitr Lek*. 2010;56(4):341-6.
13. Economic costs of diabetes in the U.S. In 2007. *Diabetes Care*. 2008;31(3):596-615.
14. Beaser RS, Caballero E, Leahy JL. Diabetes and Insulin: Indications, Initiation, and Innovations. Available at http://www.medscape.org/viewarticle/533668_1. Accessed 20 October 2011.

Complications of Ambulating on an Elevated Heel: A Literature Review

Kristin Visco, BS and Keleigh Muxlow, BS

Abstract

Introduction:

The purpose of this study was to evaluate the effects of high-heeled shoes on gait mechanics. This literature review focuses mainly on etiology regarding the pathomechanics involved with high-heeled gait.

Study Design:

Qualitative Systematic Review of the Literature

Methods:

PubMed was searched using search terms, "heel height + gait". Articles were excluded based on their irrelevance as determined by their abstracts.

Results:

It was noted that high-heels were the contributing factor to many pathologies of the foot, including Achilles tendonitis, knee pathology, and metatarsalgia.

Conclusions:

High-heeled footwear was associated with altering normal gait. This in time leads to suboptimal gait and conditions that can become debilitating to the patient. This is why so many patients, women especially, present to the podiatrist.

Key Words: heel height, gait
Level of Evidence: 4

Introduction

In today's society the accepted standard of female shoe wear is not known for comfort, but for style. For this reason, high-heeled shoes have come to play a large role in the podiatric practice. Although high heels are notorious for discomfort, they are still the predominate shoe choice for many women. Problems that occur due to wearing this type of footwear include but are not limited to hallux abducto valgus, plantar calluses, degenerative joint disease, shortened Achilles tendon, and ankle injury. These pathologies are due to the alterations that high heels have on the alignment of the foot affecting the relative orientation of the ankle, midtarsal, and metatarsophalangeal joints^{1,3}. Reviewing full-text literature provided the opportunity to understand the biomechanical changes that a high-heeled shoe induces on the foot during the gait cycle.

Methods

Information for this literature review was collected from PubMed using the search terms, "heel height + gait". Of the 88 hits that were obtained, 25 were selected based on title. After reviewing abstracts, 9 articles were selected and deemed relevant for this literature review.

Discussion

Kinetics of High-Heeled Gait

Kinetics is the study of forces that are responsible for motion in the body. Altering functional structures in the lower extremities can result in pathology. This is why it is imperative to understand the effects of high-heels and the alterations in architecture of both the bony and soft tissue structures during ambulation.

Gait is a combination of changes in ground reaction forces between the foot and the ground in both direction and magnitude.² Any imbalance between these forces may cause the foot to function abnormally during gait.

Changes that are caused by increased heel height occur in the early stance phase of gait¹. The stance phase of gait is critical for the human foot to interact and stabilize the body against the ground. Wearing a raised heel, one loses the ability to "adapt" to the terrain caused by diminished pronation at the subtalar joint. This occurs because a high heel shoe forces the foot into 14° of plantarflexion¹ at the ankle joint during the beginning of stance phase. This position causes the knee and hip to compensate for the loss of dorsiflexion at the ankle.

A recent study found in JAPMA titled, "Kinetics of High Heeled Gait," set out to study the compensatory mechanisms of the muscles of the lower extremity while wearing high heels.

Results of the high-heel were compared to that of a low-heeled sports shoe.¹ It was found that wearing a higher heel increases the work of the hip flexors to enhance the pull-off and acceleration needed for the active propulsive phase before going into swing. Interestingly, this study also presented information indicating that the knees of these subjects created a larger knee varus moment and hip adduction. The increase of muscular activity and abnormal entry into phases of gait put the hip and knee under great stress.

Interestingly, another adaptive influence caused by high-heeled shoes is decreased step length and increased cadence during gait.^{4,5} The plantarflexed attitude of the foot caused by the increased vertical and anteroposterior GRF causes the foot to spend more time in double support.⁶ This adaptive measure taken by the body is in an attempt to compensate for the decreased stability during gait while wearing high heeled shoes. An unstable gait is due to a combination of the foot being unable to pronate and adapt to the terrain while walking as well as the smaller base of the shoe.

A study comparing the different effects of running shoes, leather flats, and high heels demonstrated that a higher heel caused the load to shift from the normal point at the heel to the 1st metatarsal.⁵ This is an important aspect to consider when evaluating patients with hallux abducto valgus.

Pathologies

Achilles Tendonitis: As previously mentioned raised heels can be detrimental to the foot. It was found that there was a higher incidence of Achilles tendonitis in women that wore this type of footwear. It is thought that the increased stress to the Achilles tendon may have been generated from the increased pressure under the metatarsal heads.⁴ High heeled shoes cause the foot to act in a fixed plantarflexed position, thus increasing the stress on the Achilles tendon during toe-off. In addition it has been found that women wearing high heels have a softer heel strike. The gastrocnemius complex has to work harder to increase control of plantarflexion during heelstrike to achieve this softer landing pattern.⁴ This could be the contributing factor of the tendonitis that has been documented.

Knee Pathologies: Decreased use of the plantarflexors results in abduction at the hip, which eventually leads to a varus deformity at the knee. Over time with repetitive loading this can result in degenerative joint disease.^{6,8} In addition to DJD, an increased heel height can predispose the knee to injury due to the

decreased flexion at the knee. This diminished flexion disengages the shock absorption once provided by the knee, subjecting people to injury.

Metatarsalgia: Metatarsalgia is a broad definition of pain associated with increased stress over the metatarsal head region. As reviewed in multiple articles, increased heel height shifts plantar pressure forward, thus increasing pressure at the metatarsal heads. Repeated loading, with an increase of pressure would increase the chances of the forefoot developing a deformity. One study established that the medial forefoot results in the highest amount of pressure leading to an increased chance of injury.⁹ Considering the anterior movement of the foot caused by raised heels, the center of mass is pushed forward, more pressure is now placed on the forefoot than the rearfoot. One study, "Relationship Between Plantar Pressure and Soft Tissue Strain Under Metatarsal Heads and Different Heel Heights," measured the soft tissue thickness under the metatarsal heads and found that the soft tissue in the medial forefoot was indeed most taut in subjects wearing heels. Interestingly, this study found that the plateau of pressure was greatest with a heel height of 2 cm and heels less than 2 cm may be less destructive.⁸ With that said, the occurrence of forefoot pain caused by increased pressure could be proportionally related to heel height and can be reduced by lowered the height of the heel.

Although these associations have been made in relation to high-heeled gait the prevalence of each has not been determined. Further research should attempt to quantify the incidence of pathologies as they relate to high heeled gait.

Therapeutic Effect

Although high heels are associated with much pathology, the therapeutic effects that they can offer are sometimes overlooked. Plantar fasciitis represents a common complaint in the podiatry clinic. The United States National Library of Medicine defines plantar fasciitis as inflammation of the plantar fascia that can be caused by overuse or overstretching. Predisposing factors to this condition include obesity, long-distance running, tight Achilles tendon, and shoes with poor arch support. This represents 10-15% of foot problems that are presented to podiatrists.

One study demonstrated the use of a 5 mm heel lift to alleviate pain caused by plantar fasciitis.⁷ The raised heel provides the ability for the posterior compartment to shorten decreasing

the tension on the plantar fascia. Patients in this study noticed some relief upon wearing shoes with platforms. The outcome of this study was however highly variable. Further investigation must be done regarding this topic.

Conclusion

Women have worn high-heeled shoes for centuries. The apparent deleterious effects of heels on the body have not deterred women from wearing these uncomfortable and damaging footwear. As suspected, our literature review presented us with more negative outcomes of high-heeled shoe gear than positive. Our recommendation would be to limit the amount of time spent in this shoe due to known hip, knee, and foot pathologies that are associated with a high-heeled gait. However, it is unrealistic to assume that all women would switch out of their preferred shoe gear. For those women who refuse to abandon this popular style, a recent study has shown that the use of total contact inserts can be of help. Total contact inserts were shown to improve comfort by increasing the overall foot contact area, allowing the midfoot to bear more of the plantar pressure, thus relieving the forefoot from increased pressure³. It will be interesting to see what types of products will become available and targeted to women in the future to prevent foot pain and other associated pathologies with high-heeled footwear.

The authors of this literature review would like to see future research conducted in a more focused manner. This includes focusing on one specific anatomical site that pathology occurs in due to high heels. For example one could focus on the effects that this type of footwear creates on a specific joint rather than the gait cycle as a whole. It would also be interesting to conduct a larger study on the therapeutic effects that wearing a shoe with a heel could offer an individual with plantar fasciitis.

Author's Contributions

The authors of this article KM and KV each contributed equal amount of research and writing of this article. We searched PubMed for relevant articles concerning the effect of heel height on gait and then divided them equally to read and review. Our literature review was equally written between both of us. We each revised the article and then discussed it together.

Statement of Competing Interest

The authors declare no competing interests in relation to this manuscript.

References

1. Esenyel, M, and K. Walsh, and J. Walden, and A. Gitter. (2003). Kinetics of High-Heeled Gait. *Journal of the American Podiatric Medical Association*, 93 (1), pp. 27-32.
2. Curran, S. A, and H. Dananberg. (2005). Future of Gait Analysis. *Journal of the American Podiatric Medical Association*, 95 (2), pp. 130-142.
3. Hong, W, and Y. Lee, and H. Chen, and Y. Pei, and C. Wu. (2005). Influence of Heel Height and Shoe Insert on Comfort Perception and Biomechanical Performance of Young Female Adults During Walking. *Foot and Ankle International*, 26 (12), pp. 1042-1048.
4. Wang, Y, and D. Pascoe, and C. Kim, and D. Xu. (2001). Force Patterns of Heel Strike and Toe Off on Different Heel Heights in Normal Walking. *Foot and Ankle International*, 22 (6), pp. 486-492.
5. Blanchette, M. G, and J. Brault, and C. Powers. (2011). The influence of heel height on utilized coefficient of friction during walking. *Gait and Posture*, 34 pp. 107-110.
6. Broch, N. L, and T. Wyller, and H. Steen. (2004). Effects of Heel Height and Shoe Shape on the Compressive Load Between Foot and Base. *Journal of the American Podiatric Medical Association*, 94 (5), pp. 461-469.
7. Eisenhardt, J, and D. Cook, and I. Pregler, and H. Foehl. (1996). Changes in temporal gait characteristics and pressure distribution for bare feet versus various heel heights. *Gait and Posture*, 4 pp. 280-286.
8. Ko, P, and T. Hsiao, and T. Wang, and J. Kang, and Y. Shau, and C. Wang. (2009). Relationship Between Plantar Pressure and Soft Tissue Strain Under Metatarsal Heads with Different Heel Heights. *Foot and Ankle International*, 30 (11), pp. 1111-1116.
9. Kogler, G. F, and F. Veer, and S. Verhulst, and S. Solmonidis, and J. Paul, and . (2001). The Effect of Heel Elevation on Strain Within the Plantar Aponeurosis: In Vitro Study. *Foot and Ankle International*, 22 (5), pp. 433-439.

Diagnosis and Management of a Navicular-Medial Cuneiform Coalition: A Case Report

Christopher L. Lovell, BA and Adisa Mujkic, BA

Abstract

Introduction:

Tarsal coalitions vary in location, symptoms, frequency, and age of onset. Appearing in 1% of the population the most commonly encountered are talocalcaneal and calcaneonavicular coalitions. Isolated navicular-medial cuneiform coalitions often present asymptotically until the 4th decade and are considered to be a rarity, with few reported cases. Treatment includes initial conservative care with a last resort of surgical intervention depending on the severity of pain, patient age, and joint condition.

Study Design:

Case Report

Methods:

A 36-year-old male presents with a painful congenital fibrocartilaginous navicular-medial cuneiform coalition. A case review of two years of clinical and surgical visits. A PubMed search of the literature was conducted to review the observations and findings of previous accounts of navicular-medial cuneiform coalitions and compare with the findings established in this case. The purpose of this case report is to document an isolated navicular-medial cuneiform coalition in order to provide further information in terms of clinical presentation, diagnosis, and treatment in hopes of advancing earlier detection in a condition with minimal documentation in the medical literature.

Results:

This case demonstrates that navicular-medial cuneiform coalitions may have a demographic correlation and symptomatology that varies from other tarsal coalitions, prompting the importance of further research. Operative intervention was found to be necessary in this case; results in terms of symptomatology at 12 weeks post-op are good but not optimal.

Conclusions:

In part due to misdiagnosis and a tendency to be asymptomatic with a late onset, a review of the literature and this case indicates that navicular-medial cuneiform coalitions may be under-diagnosed. This case displays that late detection leads to further degenerative changes, strongly suggesting operative intervention. Further research is necessary to gain a better grasp on conservative and operative treatments specific for navicular-medial cuneiform coalitions.

[Level of Evidence: 4]

Introduction

A tarsal coalition is a union between two tarsal bones that limits range of motion of the joint interspace and often presents with pain. Understanding the different etiologies, symptoms, and treatment options is essential to the proper diagnosis and management of tarsal coalitions.

Possible etiologies of tarsal coalitions are grouped into congenital or acquired. Congenital etiologies are thought to be more common. The most accepted congenital postulation is the failure of differentiation of primitive mesenchyme during the first trimester of pregnancy. This failure of differentiation has been linked to a mutated gene passed in an autosomal dominant fashion. Another possible but less accepted congenital theory is a fusion of accessory bones to normal tarsal bones. Though acquired coalitions are quite rare they have been

attributed to trauma, infections, neoplasms, and other syndromes.¹

There is no conclusive evidence on the incidence of tarsal coalitions but most estimates are just under 1% for the general population.⁹ Of the reported tarsal coalitions, 43.6% have been calcaneonavicular and 48.1% talocalcaneal. All other tarsal coalitions account for 8%.⁹ However, Kumai et al. highly disputed these numbers in their focus on the navicular-medial cuneiform coalition with findings of incidences of 59% for talocalcaneal coalitions, 30% navicular-cuneiform coalitions and 10% calcaneonavicular coalitions.²

The most common method for classifying coalitions is by tissue type. These have been divided into synchondrosis, synostosis, syndesmosis, and a combination of the ones previously noted.¹ In Choi et al., no synostosis among the 35 feet exhibiting navicular-medial



cuneiform coalitions were found.³ Miki et al. noted that most navicular-medial cuneiform coalitions consist of fibrous tissue with islands of chondroid tissue.⁴

Clinically, tarsal coalitions present with a deep and aching pain localized to the coalition site, muscle spasms, and limited joint range of motion. Kumai et al. argued that pain in tarsal coalitions is due to free nerve endings found in the periosteum and in the articular capsule at the site of the coalition.⁷ Tonic muscle spasms, especially of the peroneal tendons, have been noted as a protective mechanism seen in patients with reduced, painful, subtalar joint range of motion. Peroneal muscle spasms lead to an acquired peroneal spastic flatfoot, which is the most common associated foot type of patients presenting with tarsal coalitions. However, peroneal muscle spasms associated with coalitions are not as common as previously believed. In a study of 32 feet exhibiting tarsal coalitions, Varner et al. found only two incidences of peroneal spasm. Further evidence needs to be conducted in order to provide more conclusive information regarding clinical presentations of tarsal coalition.

Various imaging techniques can be used to diagnose tarsal coalitions. Traditionally, CT scans have been the gold standard for diagnosis, however an MRI may be utilized in the case of a non-osseous union. Incomplete coalitions are harder to identify via imaging, but certain characteristics in the joint space can be noted on plain radiography and CT. On plain film and CT, evaluation of irregular articular cartilage, subchondral sclerosis, beak-like spurring, and subchondral cyst should be done.³ An MRI would aid in the analysis of the histological type of coalition.³

Treatment of tarsal coalitions begins conservatively with the use of physical therapy, casting immobilization, orthotics, steroid and/or anesthetic injection. Conservative treatment has proven to have good outcomes when there is a lack of degenerative changes and in a foot that is relatively asymptomatic.¹¹ With the persistence of pain and onset of destruction of the joint space and bone quality, the coalition can be surgically resected with or without arthrodesis. Several long-term studies have shown 77% to 100% good or excellent results after calcaneonavicular coalition resection.¹⁰ Long-term studies have shown variable good or excellent rates of 50% to 94% with resection of talocalcaneal coalition.¹⁰ Once degenerative changes are present in the midfoot, triple

arthrodesis is the indicated mode of treatment.¹⁰ In regards to the treatment of isolated navicular-medial cuneiform coalitions, there is not enough evidence in the literature to formulate a percentage range of success.

There is a limited amount of reported isolated navicular-medial cuneiform coalitions, thus it is critical to document specific cases in order to gain insight on how to obtain an early diagnosis and plan the most successful management of the condition.

CASE: Methods and Results

In September of 2009, a 36-year-old Hispanic male patient first presented to the Metropolitan Hospital podiatry clinic with complaints of burning, sharp pain on the medial side of his left ankle and on the dorsum of his left foot. Prior to his visit to the podiatry clinic, the patient visited the ER three times for the pain. The patient explained that the pain became noticeable in April 2009, he denied experiencing any direct trauma or having any family members presenting with similar symptoms. Working on his feet for long hours at a restaurant, he states that the pain is most severe at the end of each workday. His medical history is significant for GERD, hypercholesterolemia, and psoriasis.

A clinical exam demonstrated normal neurological and vascular findings. Muscular strength was adequate with no indication of muscle spasm. Limited bilateral dorsiflexion at the ankle and at the first MPJ was noted. All other joints exhibited normal range of motion. Patient's arch height was +3 off weight bearing and non-reducible on weight bearing. During this initial visit to the clinic, the patient was diagnosed with a bilateral rigid cavovarus foot type.

Over the following twenty-one months the pain would appear occasionally, persist for a short time period and then subside. Management with custom foot orthosis and physical therapy were recommended. However, at the time the patient elected not to treat with conservative measures.

In the spring of 2011 the pain returned with greater severity and more notable consistency. In July 2011, x-rays and a CT scan confirmed bilateral navicular-medial cuneiform fibrocartilaginous coalitions. Pre-operative radiographic imaging of both feet display findings of degenerative navicular-medial cuneiform joint changes such as narrowing and radiolucency (refer to figure 1). A CT scan of

the left foot demonstrates subchondral sclerosis and abnormal articular surfaces of the plantar aspects of the joints aiding in the diagnosis of incomplete bilateral fibrocartilaginous coalitions (refer to figure 2).

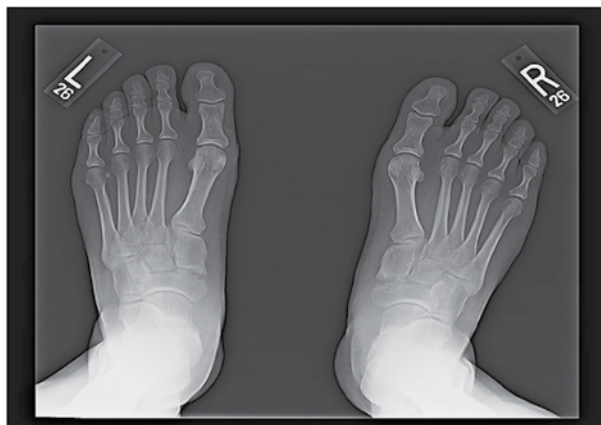

Figure 1: A bilateral anterior-posterior radiograph demonstrating degenerative changes at the navicular-medial cuneiform joint.

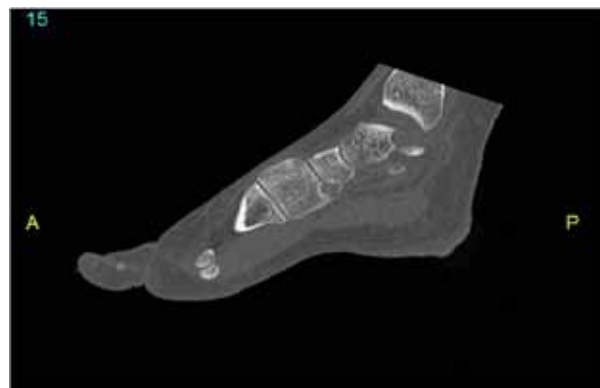


Figure 2: Sagittal CT image of the left foot demonstrating a sclerotic plantar articular surface at the navicular-medial cuneiform joint.

Due to the progressive nature of his pain, degenerative changes in the midfoot, and non-compliance with conservative therapy, surgical intervention was deemed necessary. A resection of the left navicular-medial cuneiform bar with possible arthrodesis of the navicular-medial cuneiform joint was proposed. The surgical procedure consisted of resecting the coalition and the cartilaginous surfaces of the joint. Due to the extent of degenerative changes noted intra-operatively, the navicular-medial cuneiform joint was then fused with a 4.0 cannulated partially threaded screw and a locking plate that was fixated with three 18mm 2.7 locking screws and one 20mm 2.7 locking screw.

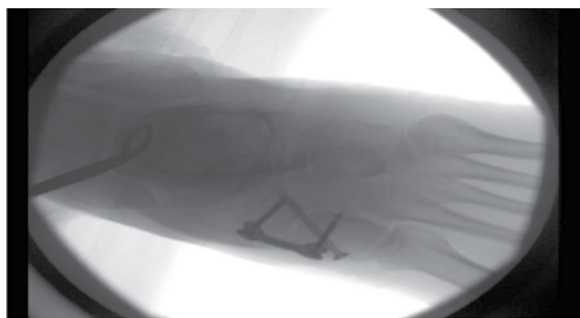

Figure 3: An intra-operative radiograph of the left foot displaying the proper placement of a cannulated partially threaded screw and a locking plate following resection at the navicular-medial cuneiform joint.

The resection and fixation were intra-operatively assessed with C-arm fluoroscopy. Compression without shortening of the medial column was achieved (refer to figure 3). A post-op course of a posterior splint and non-weight bearing ambulation with crutches was taken.

At twelve weeks post-op, the patient had returned to wearing sneakers and complained of mild tenderness at the proximal dorsal aspect of the left foot while walking. X-rays at twelve weeks post-op indicated normal alignment of hardware and normal bone healing. Physical therapy was recommended, however, the patient did not return to clinic after that visit.

Discussion

The patient in this case presented with pain in his mid-thirties. The patient denies experiencing any earlier foot or ankle pain despite being an active soccer player while growing up in Mexico. This later onset correlates with Kumai et al.'s findings that navicular-medial cuneiform coalitions present later than other tarsal coalitions. Kumai found that the average age in which patients present with navicular-medial cuneiform coalitions is 31.9 years while talocalcaneal coalitions present at 20.1 years and calcaneonavicular coalitions present at 17.8 years.²

For the last several years in the United States the patient has been working on his feet all day as a restaurant employee. This strenuous life style most likely contributed to the onset of his pain. The patient denies any trauma and does not have a history of any primary degenerative joint diseases. His medical history along with the bilateral presentation of the navicular-medial cuneiform coalitions led us to believe that his condition is congenital.

The findings in this case correlate with the radiological features of 35 incomplete navicular-medial cuneiform coalitions reviewed by Choi et al. The most common findings Choi noted on plain radiography and CT were: subchondral sclerosis, beak-like spurs, irregular articular surface, and a narrowing of the joint space. The authors noted that fibrocartilaginous coalitions can evoke micro-fractures and subsequent remodeling at the joint surface, which can result in secondary degenerative changes that resemble osteoarthritis. All 35 cases showed bony abnormalities at the plantar aspect of the joint with a normal dorsal joint surface. While the degenerative changes are similar to that of osteoarthritis, contributing to misdiagnosis, the localization to the plantar aspect of the joint can be used to distinguish from true osteoarthritis, which would present with dorsal joint obliteration and dorsal spurs.³

Surgical intervention for our patient was deemed necessary due to the unbearable pain experienced by the patient and destructive bony changes displayed on the x-rays and CT scan. Although, radiographs displayed similar bilateral findings, due to lack of symptomatology of the right coalition, surgery was only planned for the left foot. Due to the patients' age and bone quality, assessed intra-operatively, arthrodesis following resection was considered to be the best surgical approach. Of the 14 navicular-medial cuneiform coalitions Kumai et al. operated on, only three procedures were isolated resections and those were on younger individuals with salvageable joint conditions. Of the 14 operated cases, 86% had good to excellent results. Overall, the authors suggested that fusion is the optimal procedure for navicular-medial cuneiform coalitions due to the joint's anatomically limited range of motion.²

Generally, it has been thought that tarsal coalitions are not predominant in certain ethnic demographics. However, our review of the literature shows that coalitions could be an exception. Of the nine originally reported cases

seven patients were of Japanese descent and two were of Hispanic descent.^{6,4} Since then the cases reported by Kumai et al. and Choi et al. have been primarily of Asian descent. In the Western hemisphere there is a lack of substantial literature and notable case reports on navicular-medial cuneiform coalitions; this is assumed to be due to an ethnic correlation.²

Taking into consideration our patient's age, ethnicity, and symptomatology, this case aligns well with reasons for a decreased incidence and presentation of navicular-medial cuneiform coalitions. Navicular-medial cuneiform coalitions could be a lot more common than originally thought. Prior to 1996 there were only 10 reported cases of navicular-medial cuneiform coalitions. Kumai et al. diagnosed 60 cases and Choi et al. found an additional 35. The navicular-medial cuneiform joint has an anatomically limited range of motion in comparison to other tarsal joints. This helps explain why there is a later presentation of symptoms that most often coincides with strenuous activity and degenerative processes that occur as the patient ages. Amongst the cases we reviewed, the vast majority of navicular-medial cuneiform coalitions were of the incomplete fibrocartilaginous type without peroneal spasms. This would further contribute to a lack of, or later onset of symptomatology since some motion is still retained in a joint that does not require that much motion to begin with.

Conclusion

As a result of patient non-compliance, the case at hand did not involve a conservative treatment course. This suggests a need for evaluation of conservative treatment of isolated navicular-medial cuneiform coalitions and research of alternative operative procedures to construct a ground for comparison.

The documentation of this case sheds some light in terms of epidemiology, clinical presentation, and radiographic findings onto an under-diagnosed and poorly understood condition. Twelve weeks post-op our patient's pain had greatly diminished when compared to his pre-op status, with only mild discomfort for which physical therapy was recommended. With a longer follow-up time, a more conclusive analysis of the success of this surgical procedure would have been possible. A longer follow-up time of future cases is necessary to provide further insight on the outcome of surgical intervention in terms of presence of

symptomatology and biomechanical implications with degenerative changes of adjacent joints.

Too often tarsal coalitions are grouped together in literature, despite their variations in presentation and demographic incidence. Further studies taking into account specificities of navicular-medial cuneiform coalitions will allow for better methods of detection, diagnosis, and treatment.

Acknowledgements

The authors would like to thank Johanna Godoy, DPM for her guidance throughout the study of the case. A special thank you to Jose Loor, DPM for his encouragement and assistance during the background research of the case.

Author's Contributions

C.L and A.M worked together to gather and analyze the case information, conduct a search of the literature, draft, and edit the manuscript.

Statement of Competing Interests

The authors declare that they do not have any competing interests in regards to this manuscript.

References

1. Downey M. Tarsal Coalitions. In: Banks A, Downey M, Martin D, Miller S. *McGlamry's Comprehensive Textbook of Foot and Ankle Surgery*. 3rd ed. Philadelphia, PA: Lippincott Williams and Wilkins; 2001: 993-1031.
2. Kumai T, Tanaka Y, Takakura Y, Tamai S. Isolated First Naviculocuneiform Joint Coalition. *Foot and Ankle International*. 1996; 17(10):635-640.
3. Choi Y, Kim S, Lee K, et al. Naviculo-Medial Cuneiform Coalition: Radiological Features. *The Journal of the Korean Radiological Society*. 2005; 53: 381-386.
4. Miki T, Yamamuro T, Iida H, Ohta S, Oka M. Naviculo-Cuneiform Coalition A Report of Two Cases. *Clinical Orthopedics and Related Research*. 1985; 196: 256-259.
5. Varner K, Michelson J. Tarsal Coalition in Adults. *Foot and Ankle International*. 2000; 21(8): 669-672.
6. Hynes R, Romash M. Bilateral Symmetrical Synchondrosis of Navicular First Cuneiform Joint Presenting as a Lytic Lesion. *Foot and Ankle*. 1987; 8(31): 164-168.
7. Kumai T, Takakura Y, Akiyama K, Higashiyama I, Tamai S. Histopathological Study of Nonosseous Tarsal Coalition. *Foot and Ankle International*. 1998; 19(8): 525-531.
8. Gregersen H. Naviculocuneiform Coalition. *The Journal of Bone and Joint Surgery*. 1977; 59-A(1): 128-130.
9. Wiles S, Palladino S, Stavosky J. Naviculocuneiform Coalition. *Journal of the American Podiatric Medical Association*. 1988; 78(7): 355-360.
10. Htwe Z and Calder J. Tarsal Coalitions. *Foot and Ankle Clinics of North America*. 2010; 15 (2): 349-364.
11. Lemley F, Berlet G, Hill K, et al. Current Concepts Review: Tarsal Coalition. *Foot and Ankle International*. 2006;27(12):1163-11639.

Off-loading the Diabetic Foot for Ulcer Treatment

JiSun Lee, MS and Poovasiit Klinoubol, BS

Abstract

Introduction:

The etiology of diabetic foot ulceration is complex. One of the main causes is neuropathy, the result of which any area where there is excessive pressure on the foot can lead to an ulcer. Non-infected and non-ischemic ulcers heal when an area is off-loaded. Therefore, off-loading of an affected area is considered critical to the treatment and healing of diabetic foot ulcers. In this article, we undertake a comprehensive review of a compilation of relevant data in order to determine whether relieving areas of elevated plantar pressure (off-loading) can heal ulceration.

Study of Design:

Qualitative Systematic Review of the Literature

Methods:

Narrative overview of literature retrieved from searches of computer databases with hand searches of pertinent journal texts published before September 2010.

Results:

To assess plantar pressure, the semi-quantitative estimation of pressure technique and the planscan ultrasound technique are more practical than the optical pedobarograph. After successful assessment, clinicians apply one of the several mechanical off-loading techniques. While the total contact cast, TCC, has long been considered the gold standard in plantar foot ulceration, many other devices also have been studied and proven to be good alternate methods.

Conclusions:

For plantar foot ulceration, off-loading remains an effective treatment. Also, it is highly recommended that clinicians educate their patients of all treatment options and in light of all relevant factors choose the method most likely to achieve the desired outcome.

Key words: diabetic foot ulcers, plantar pressure, off-loading devices, total contact cast, walking cast, orthotic, insole, footwear

Level of Evidence: 4

Introduction

Neuropathic foot is commonly seen in clinical practice and is primarily related to the increasing prevalence of diabetes mellitus.¹ People with diabetes develop foot ulcers because of neuropathic ischemia, foot deformity or both.² The initiating injury, generally a minor trauma, may come from mechanical, thermal, or repetitive and continuous mechanical stress. Moreover, vulnerable feet usually involve vascular insufficiency with peripheral neuropathy.³ In the ulcer healing process it is useful to determine the depth of the ulcer and the underlying structures such as tendons, ligaments, muscles, bones or joints. Treatment that is applied locally consists of repeated debridement and dressing in general. Nowadays, there are many techniques to enhance healing processes. One of the most successful conservative treatments of foot ulcers is transitional off-loading to redistribute pressure.⁴ There is no consensus in the literature concerning the role of weight transduction measurement and off-loading

devices in the prevention of plantar ulcers. This is likely due to the diversity of intervention of plantar pressure measurement and the lack of information about off-loading efficacy.⁵ A review of the literature provides important information about the measurements of weight transduction over the foot which is effective in preventing both ulceration and ulcer recurrence. The main part of this article provides an overview of off-loading modalities for pressure redistribution, which may be useful for researchers or clinicians to identify, justify, and/or refine for further research or for their practice.

Research Design and Methods

A search for relevant articles was conducted using PubMed and CINAHL, using diabetic foot treatment as a key word and limiting the search to English articles. From PubMed, 4,969 articles were retrieved. Among these, 30 articles were included in this review. From CINAHL, by using the same key word and limiting the search to English articles, full text and review articles, 1020 articles were found, of which eight articles



were included. Furthermore, plantar pressure, diabetic ulcers and off-loading devices were used as key words for narrowing down the topic from PubMed; 212 and 88 articles were identified as relevant articles, respectively, of which three and 18 articles were selected for review. For off-loading devices, three articles were identified from a thorough search of the college library.

Results

From several studies of methodologies to assess plantar pressure, we were able to conclude that the semi-quantitative estimation of pressure technique and the planscan ultrasound

technique are more practical than the optical pedobarograph. When clinicians are applying mechanical devices after successfully assessing the plantar pressure, the total contact cast, TCC, has been known as the gold standard for treating diabetic foot ulceration. However, other devices such as vacuum stabilization boot (Figure 1) and instant TCC, iTCC (Figure 2) have also been found to be almost as effective as TCC and may offer certain advantages. Although slightly less effective, the removable walking boot and molded ankle foot orthosis are also good alternate devices. When the ulceration is less severe, custom-made footwear (Figure 3), a rocket sole shoe (Figure 4), and half-shoes are also effective devices.



Figure 1: Vacuum Stabilization Boot

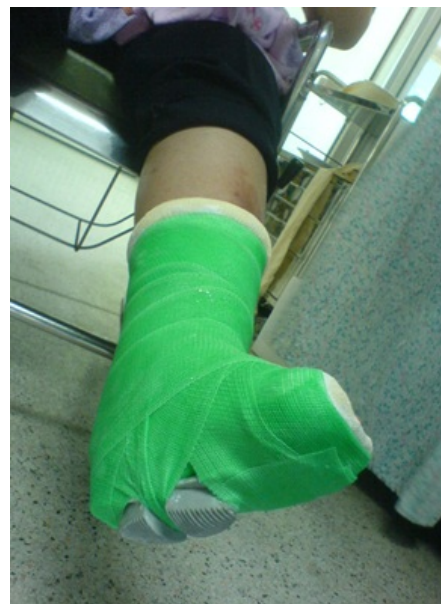

Figure 2: Instant Total Contact Cast



Figure 3: Custom Made Footwear



Figure 4: Rocket Sole Shoes

Discussion

There are a number of techniques available to assess plantar pressure abnormalities for diabetic patients at risk of foot ulceration (Table 1). Veves A. and Boulton AJ discussed optical pedobarograph, which uses a matrix of transducer software with a computer system and usually is used in a gait laboratory⁶. The advantages of this device are high resolution, reliability, and accuracy. However, it requires a high cost and a highly trained person.⁶ As with the optical pedobarograph technique, a semi-quantitative estimation of pressure distribution technique is also widely used in a gait laboratory. It generates impressions in different shades of gray while the patient is walking on the mat according to plantar pressure distribution.⁷ Compared to the pedobarograph, it is inexpensive, portable, and disposable. Thus, recently it is recognized as a more useful screening device to assess plantar pressure.⁸ More recently, the usefulness of the planscan ultrasound technique was described by Abouaesha et al.⁹ From an extensive study of subcutaneous tissue, they concluded that a greater risk of foot ulceration occurs in the area of reduced thickness of the subcutaneous tissue. Moreover, the ultrasound method is very safe because it does not use radiation like an x-ray or CAT scan. However, in order to effectively employ this method, physicians must learn the way a particular type of tissue responds to an ultrasound wave.

After carefully assessing a patient's plantar pressure, clinicians are now able to choose one of the many mechanical off-loading devices to cure the ulceration (Table 2). Among many devices, TCC is known as one of the most effective off-loading devices and has been considered the gold standard in the treatment of diabetic plantar foot ulcers. However, TCC requires a long manufacturing time and frequent changes of the cast to prevent complications.¹⁰ By rendering walking nearly impossible, it also may greatly interfere with the life of an otherwise ambulatory patient. Due to these disadvantages, Cook JJ et al. and many researchers designed studies to compare TCC with other possible devices¹⁰. In particular, Cook JJ et al. compared the TCC, the effectiveness of which is often attributed to its non-weight bearing nature, with the vacuum stabilization boot for diabetic foot ulcer patients¹⁰. They showed that the vacuum stabilization boot is more practical than TCC in many respects (Figure 1). It allowed the patients to be further examined with radiography without

removing the device. It was also more manageable to accommodate any edema during the treatment. By allowing patients to remove the sole while sleeping, patients' liners remained clean.¹⁰

An irremovable cast walker or iTCC is also another effective device in the treatment of foot ulceration (Figure 2). This treatment is relatively easier to use and requires much less time to place and remove than other devices. However, Katz IA et al. suggested further research is necessary in order to observe long-term outcomes.¹¹

To yield greater forefoot off-loading in plantar ulceration, the removable cast walker is recognized as the most suitable device. Although, it is less effective in treating overall areas of the plantar ulcer, it still has significant benefits because the forefoot is the most common area for diabetic ulceration.¹²

Custom made footwear can be a good alternative for diabetic foot ulcer patients with a low risk of neuropathy or peripheral artery disease and without any foot deformity (Figure 3).¹³ Benefits attributed to using this device included lower incidences of device-related complications and greater effectiveness than other similar devices. However, a significantly longer healing time was identified as one of the considerable disadvantages.¹⁴ Rocket sole shoes are also used to treat foot ulcers for patients with a normal longitudinal arch (Figure 4). Kavros SJ et al. reported that when rocket sole shoes were used with a 1.25cm plastizote insert, the peak plantar pressure was reduced the most¹⁵. However, the variation in the amount of off-loading is reported as the main problem that has to be addressed in order to make it a more dependable device.¹⁵

The molded ankle foot orthosis can also be used. It is especially efficacious for redistributing lateral side pressures to other areas. Despite being considered one of the most effective treatment methods, its heavy weight and the resulting discomfort may interfere with a patient's daily life activities. Such disadvantages have prevented this treatment method from being widely adopted.¹⁶ On the other hand, a half shoe has been a popular device for treating patients with diabetic foot ulcers. It was originally designed to treat post-operative patients to reduce forefoot pressure. However, due to its low cost and simple application method, it has been also attractive for use in the treatment of foot ulceration.¹⁷

Table 1: Methodologies To Assess Plantar Pressure

Techniques	Advantages	Disadvantages
Optical pedobarograph ⁶	Accurate	Expensive
	Reliable	Require trained person
	High resolution	
Semi-quantitative estimation of pressure technique ⁷ [Podo Track, PressureStat]	Sensitive	Require training of observer
	Portable	
	Inexpensive	
	Disposable method	
Planscan ultrasound technique ⁹	Safe	Require knowledge of the way a particular type of tissue responses to an ultrasound wave.
	Assess the depth of subcutaneous tissue under high-pressure sites	
Summary of advantages and disadvantages of each technique to assess plantar pressure.		

Table 2: Devices for Mechanical Offloading

Devices	Advantages	Disadvantages
TCC ¹⁰	Greater proportion of ulcers healed	Long manufacturing time
	Great immobilization device	Interfere quality of life Require frequent changes of cast
Vacuum stabilization boot ¹⁰	Allow radiography without removal	Need further research
	Accommodate change in edema if occur	
	Compliance locking straps	
iTCC or Irremovable cast walker ¹¹	Easier to use	Need further research
	Less time to place and remove	
	Lower cost	
Removable walking boot ¹²	Greater forefoot load reduction	Slightly less effective than TCC (but comparable)
	Easy to remove and reposition	
Custom-made footwear ^{13,14}	Less complication	Only patients without foot deformity
		Longer healing time
Rocket sole shoe ¹⁵	Best effect with plastizote insert	Only patients with normal longitudinal arch. Amount of off-loading varied
Molded ankle foot orthosis ¹⁶	Effective for reducing lateral side pressure	Heavy and uncomfortable
Half-shoes ¹⁷	Inexpensive	Need crutch assistance
	Easy to apply	
Abbreviation: TCC, total contact cast; iTCC, instant TCC.		
Summary of advantages and disadvantages of each device for mechanical off-loading in the treatment of diabetic plantar foot ulcer.		

Conclusion

For diabetic patients with plantar foot ulceration, off-loading has been proven to be an important and effective conservative treatment. Also, without necessary patient follow-up, even in the case of TCC treatment, which is considered the gold standard of plantar ulcer treatment, foot deformity and more severe plantar ulceration often results. Thus, it is highly recommended that clinicians educate patients as to their treatment options and use the most appropriate methodologies and mechanical devices in light of all relevant circumstances to tailor each treatment to meet the unique needs of the patient. More research is necessary in this field.

Acknowledgements

We are thankful to our faculty advisors, Dr. D'Antoni and Dr. Khan, whose guidance and support throughout enabled us to write this article. We also would like to thank the Editor-in-Chief, Adisa Mujkic, and other Associate Editors for their hard work.

Statement of Competing Interests

The authors of the article, JL and PK are not affiliated with any institutions and neither author has received funding from any organization. Thus, neither author has a competing interest which would have to be disclosed.

Authors' Contributions

Curiosity about the treatment of neuropathic foot ulcers, particularly in the case of diabetic foot ulceration inspired the authors to conduct research and write this article. The authors looked for relevant articles and gathered helpful information from a variety of sources. We helped each other in designing the study and drafting the manuscript. All authors read and approved the final manuscript.

References

1. Tamir E. Treating the diabetic ulcer: practical approach and general concepts. *Israel Medical Association Journal* 2007 Aug; 9980:610-5
2. Carvanage PR, Lipsky BA, Bradbury AW, Botek G. Treatment for diabetic foot ulcers. *Lancet* 2005 Nov 12;366(9498):1728-35
3. Leung PC. Diabetic foot ulcers-a comprehensive review. *Surgeon* 2007 Aug;5(4): 219-31
4. McGuine J. Transitional off-loading: an evidence-based approach to pressure redistribution in diabetic foot. *Advance Skin Wound Care* 2010 Apr;23(4):175-88
5. Cavanagh PR, Bus SA. Off-loading the diabetic foot for ulcer prevention and healing. *Journal of American Podiatric Medicine Association* 2010 Sep-Oct;100(5):360-8
6. Veves A, Boulton AJ. The optical pedobarograph. *Clin Podiatr Med Surg* 1993;10:463-470
7. Cavanagh PR, Ulbrecht JS, Caputo GM. The biomechanics of the foot in diabetes mellitus. In: Pfeifer MA, ed. Levin and O'Neal's The Diabetic Foot. St. Louis: Mosby; 2001: 125-196.
8. Van Schie CHM, Abbott CA, Vileikyte L, Shaw JE, Hollist S, Boulton AJM. A comparative study of PressureStat, a simple semiquantitative plantar pressure measuring device, and the optical pedobarograph in the assessment of pressures under the diabetic foot. *Diabet Med.* 1999 Feb;16(2):154-9.
9. Abouaeha F, van Schie CH, Griffiths GD, Young RJ, Boulton AJ. Plantar tissue thickness is related to peak plantar pressure in the high-risk diabetic foot. *Diabetes Care* 2001;24:1270-1274.
10. Cook JJ, Cook EA. Protected Weight Bearing During Treatment of Acute Charcot Neuroarthropathy. *The Foot and Ankle Online Journal* 4 (7): 1.
11. Katz IA, Harlan A, Miranda-Palma B, et al. A randomized trial of two irremovable off-loading devices in the management of plantar neuropathic diabetic foot ulcers. *Diabetes Care* 2005 Mar;28(3):555-9.
12. Gutekunst DJ, Hastings MK, Bohnert KL, Strube MJ, Sinacore DR. Removable cast walker boots yield greater forefoot off-loading than total contact casts. *Clin Biomech.* 2011 Jul;26(6):649-54.
13. Ramachandran A, Lakshmi S, Nanditha A, Samith SA, Snehalatha C. Role of Industries in the Care of Diabetic Foot. *International Journal of Lower Extremity Wounds* 2010 9: 116.
14. Van De Weg FB, Van Der Windt DA, Vahl AC. Wound healing: total contact cast vs. custom-made temporary footwear for patients with diabetic foot ulceration. *Prosthetics and orthotics international* 2008 Mar;32(1):3-11.
15. Kavros SJ, Van Straaten MG, Coleman Wood KA, Kaufman KR. Forefoot plantar pressure reduction of off-the-shelf rocker bottom provisional footwear. *Clin Biomech.* 2011 Aug;26(7):778-82.
16. Nowak MD, Abu-Hasaballah KS, Cooper PS. Design enhancement of a solid ankle-foot orthosis: real-time contact pressures evaluation. *Journal of Rehabilitation Research & Development* 2000 May/June;37(3):273-82.
17. Armstrong DG, Lavery LA, Nixon BP, Boulton AJ. It's Not What You Put On, but What You Take Off: Techniques for Debriding and Off-Loading the Diabetic Foot Wound. *CID* 2004:39.

Tenosynovitis of the Lower Extremity: A Systematic Review

Javeria Hussaini, BA, Hanya Almudallal, BA, Jonathan R. Roy, MS, and
Gabriel Lopez-Ross, BA

Abstract

Introduction:

Tenosynovitis of the lower extremity is defined as inflammation of a muscle tendon sheath in the ankle and foot. Trauma and overuse of the foot can lead to common symptoms such as swelling and pain of the ankle and foot. Other causes that attribute to the onset of tenosynovitis include antibiotics, bacterial infection, and protothecal infection. Depending on the resources available to the clinician, there is a wide range of diagnostic tools that can be used to identify the condition. Both non-operative and operative treatments should be explored when presented with tenosynovitis. The purpose of this paper is to discuss possible causes, diagnostic techniques, and treatment options of tenosynovitis of the lower extremity due to the minimal literature currently available.

Study Design:

Qualitative Systematic Review of the Literature

Methods:

A PubMed database search was performed with the inclusionary term "tenosynovitis". 3217 articles were retrieved and reviewed; one article was selected. The inclusion criterion was based on broad relevance to tenosynovitis and correlation to the lower extremity. A PubMed advanced search was performed with the terms "tenosynovitis" and "foot", with AND used as the exclusion operator. 267 articles were retrieved and abstracts were reviewed. Ten articles were selected based on inclusionary criteria of tenosynovitis related to the lower extremities.

Results:

Our study showed that tenosynovitis of the lower extremity can manifest due to several etiologies: use of antibiotics, protothecal species, gonococcal infection and structural abnormalities of the lower extremities. It was found that MRI, and ultrasound, also termed sonography, were the most accurate forms of diagnosis. Treatments found for tenosynovitis consisted of both non-operative and operative methods. If non-operative methods were unsuccessful in relieving the symptoms, surgical debridement and tendonoscopy were performed.

Conclusions:

The study concludes that there are various causes, diagnostic tools and treatments for tenosynovitis. Clinicians should be aware of these components when encountering patients with tenosynovitis so effective underlying causes, diagnosis, and treatment can be utilized.

Key Words: tenosynovitis, foot
Level of Evidence: 4

Introduction

Tenosynovitis is the inflammation of a tendon that is enclosed by a synovial sheath. This pathology is generally detected in the upper and lower extremities. Common sites of inflammation, however are mainly seen in the lower extremities, such as the posterotibial and peroneal compartments⁴. Tenosynovitis of the lower extremity is characterized by tenderness, pain, swelling, and inflammation of the ankle and foot².

In the study conducted by Gluck, physical trauma and overuse were the most common causes for tenosynovitis². However, recent studies have reported uncommon etiologies to result in tenosynovitis of muscle tendons of the lower extremity^{1,5,7}. Some of these causes were secondary to a pathological condition and some induced by the drug side-effects⁵. These studies

have not been discussed in any broad study for tenosynovitis to date, based on preliminary searches on the topic.

Clinicians diagnose tenosynovitis in a range of cases and the diagnostic tools in each case vary extensively. Several studies found in literature searches utilized different diagnostic tools to determine the pathology as tenosynovitis^{8,10}.

A wide variety of studies on tenosynovitis in literature searches have stated the ideal treatment for the pathology. These treatments range from non-operative procedures, such as medication to operative methods, such as tendonoscopy.^{3,10} It is evident that currently, clinicians use their discretion for their choice of diagnostic tool utilization and treatment for tenosynovitis.

Scientists and clinicians should be aware of all causative agents, diagnostic tools, and

treatments available for tenosynovitis. A literature search on tenosynovitis correlating to the lower extremity revealed no meta-analysis or general systematic review for this pathological condition. The lack of such research prompted this study to be conducted. The goal of this study was to establish a clear and in-depth summary on possible etiologies of tenosynovitis present in the lower extremity, as well as various diagnostic tools and treatments that are currently utilized by physicians.

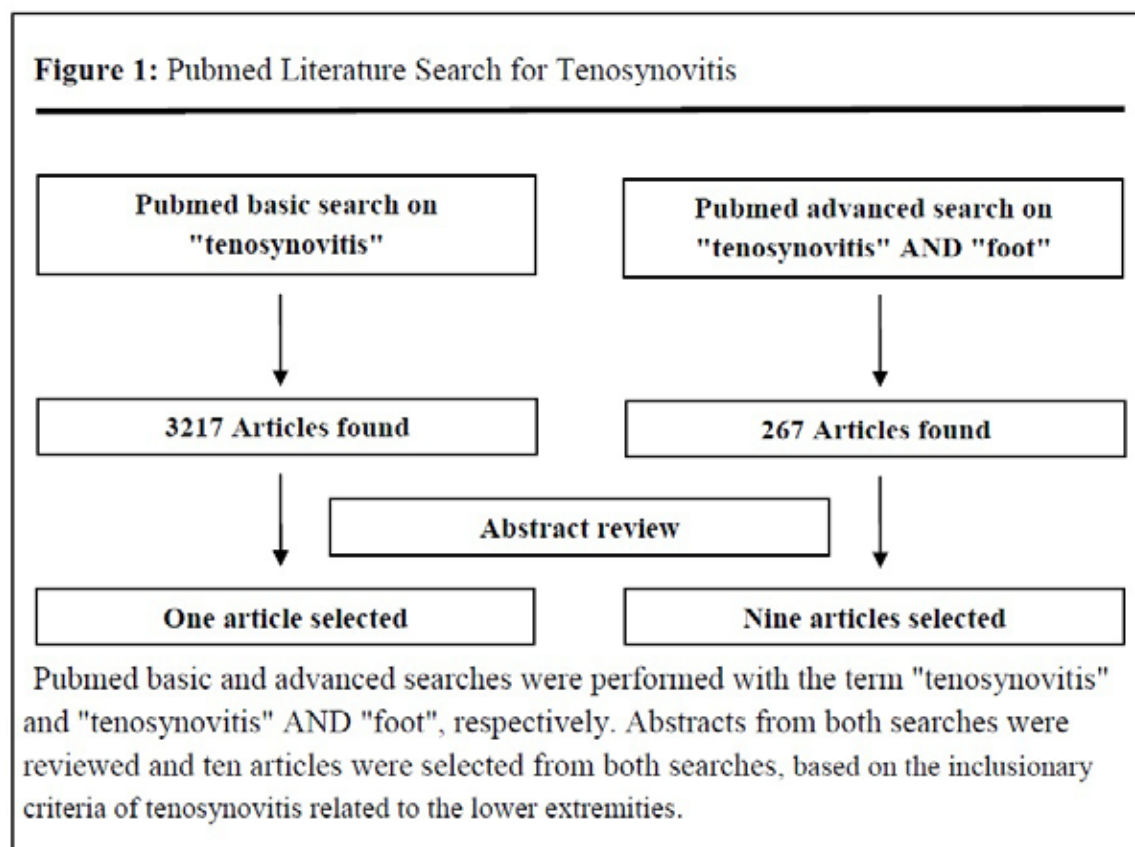
Methods

A PubMed search was performed with the term "tenosynovitis" using no inclusion/exclusion operators. 3217 articles were found, abstracts were reviewed, and one article was selected. The inclusion criteria for articles were those focusing on tenosynovitis related to the lower extremities. Another PubMed search was performed with the terms "tenosynovitis" and "foot" with AND used as the exclusion operator. 267 articles were found, abstracts were reviewed and ten articles were selected based on the same inclusion criteria as the previous search. (Fig. 1).

Results

Review of the selected articles revealed several causes, diagnostic tools and treatments for tenosynovitis of the lower extremity. In the case report we reviewed by Kayabas et al.,⁵ ciprofloxacin was found to be a cause of tenosynovitis. Protothecal infection was the cause of tenosynovitis in the case report we reviewed by Lee et al.⁷. Bacterial infection, specifically *Neisseria gonorrhoea*, was the cause of tenosynovitis in the case report by Faraj et al.¹. General trauma was mentioned as a cause of tenosynovitis in the article by Helal et al.⁴, while anatomical deformities and variations were found to contribute to tenosynovitis in the case report by Heckman et al.³.

In terms of diagnostic tools, ultrasound, also termed sonography in several studies, was mentioned as the preferred method in the article by Mastos et al.⁸ as well as in the case report by Kesikburun et al.⁶ MRI was used to diagnose tenosynovitis in the reports by Gluck et al.,² and Heckman et al.³ The various treatments of tenosynovitis that we came across in our review included both non-operative and operative forms. The non-operative treatments we found were outlined in the report by Gluck et al.,²



which included NSAIDs and tendon stabilization. Surgical treatments for tenosynovitis such as tendonoscopy and tendon debridement were explained in the case series by Scholten et al.¹⁰ and in the case report by Heckman et al.³, respectively. Throughout our review of literature on the topic of tenosynovitis of the lower extremity, we found useful information on the many causes, diagnostic tools, and treatments that can be used to further the understanding of this condition.

Discussion

Tenosynovitis: Causes

Based upon our findings, there are many causes of tenosynovitis of the lower extremity. A review of several case reports has presented drug, green algae, and bacteria as some causes of tenosynovitis. In addition to these instances, some people have structural abnormalities of the foot that can lead to tenosynovitis and other foot tendinopathies.

Kayabas et al.⁵ presents a case report of tenosynovitis induced by the use of the antibiotic ciprofloxacin. In this study, a healthy female patient was evaluated for complaints of abdominal pain, nausea, vomiting, fever, chills, dysuria, and urinary urgency. Blood and urine tests revealed an underlying urinary tract infection, verified by the presence of pyuria and hematuria. Her blood test was negative for bacteria but the urine culture revealed the presence of *Escherichia coli* (103 CFU/ml).⁵

Four days after beginning treatment with ciprofloxacin, the patient developed itchy, erythematous swelling over the left elbow and dorsolateral aspect of the fifth toe. The patient also developed calor over that region on the left foot. Pain was elicited during joint movements in these areas and progressed to the hallux of the left foot by the fourth day of treatment.⁵

The patient was sent to imaging where a T2-weighted MRI revealed inflammation in the synovial fluid surrounding the flexor hallucis longus tendon. Following the diagnosis, the patient discontinued use of ciprofloxacin and was prescribed ceftriaxone (2g/day). The patient's complaint of pain and discomfort began to improve within two days and all symptoms were resolved within three days. A second MRI performed showed a decrease in tenosynovitis in the flexor hallucis longus tendon following the discontinuation of ciprofloxacin.⁵

Another cause of tenosynovitis was described in a case report by Lee et al.⁷, presenting a 51-year-old female patient who

was diagnosed with tenosynovitis due to exposure to the achlorophyllic algae, *Prototheca*. The patient presented herself with a swollen skin lesion on her dorsal right foot, which originated at an injection site from past varicose vein treatments. Injections were administered at four different sites, only the dorsal region of the right foot had signs of inflammation. The patient was preliminarily treated with oral amoxicillin/clavulanate antibiotic and local triamcinolone but had no response. MRI imaging revealed a lesion on the skin and subcutaneous tissue from the first metatarsal bone to the dorsal aspect of the cuneiform bone. Tenosynovitis was noted along with the extensor hallucis longus tendon. Resection of the nodule revealed multiple morula-like sporangia and tissue cultures showed creamy yeast-like colonies. The Vitek II YST card for species identification system was used and *P. wickerhamii* was found to be the causative agent.⁷

Prototheca species are generally ubiquitous in nature such as in salt water, trees, garbage dumps, and household garbage. These organisms are normally found in the sputum, skin, and feces of humans and animals. Clinical manifestations for the *Prototheca* species are due to opportunistic infections and are generally found in patients with open wounds or post-surgery. Also, immunosuppressed individuals are more at risk for these infections.

Faraj et al.¹ report a case of tenosynovitis caused by a bacterial species. In this report, a 31-year old female patient was diagnosed with acute septic extensor hallucis longus (EHL) tendon tenosynovitis caused by *Neisseria gonorrhoea*. The patient complained of pain and discomfort upon weight bearing in her right foot with no history of trauma, gout or arthritis. Vaginal and cervical swabs were conducted and were negative for any signs of infection. The pain and discomfort was unilateral, red, warm, and swollen on the dorsum of her right foot extending to the ankle joint area. Marked tenderness along the extensor tendon sheath of the extensor hallucis longus muscle tendon with pain induced by passive plantarflexion of the right hallux. Blood tests revealed an infection and a radiograph revealed swelling around the ankle and dorsal aspect of the right foot.¹

Usually, gonococcal infections can be seen in synovial joints and cause certain effects of arthritis; both of which were not seen in this case. It is unusual to find gonococcal infections in tendon sheaths as stated in this study.¹

In addition to drug, green algae, and bacterial induced causes of tenosynovitis, some anatomical predispositions can exacerbate the occurrence of tendon disorders.³ For instance, a shallow or narrow retromalleolar sulcus can cause tendon subluxation and affect the stability of peroneal tendons. Hypertrophy of the peroneal tubercle may cause friction of tendons within tendon sheaths. In this particular study performed on 103 people with tendon disorders, 29% had this hypertrophy present causing peroneal tenosynovitis. A cavovarus hindfoot (a common form of pes cavus) can increase frictional forces at the lateral malleolus, peroneal tubercle, and cuboid notch. This increases mechanical stress and leads to tenosynovitis,³ among other tendon disorders.

Tenosynovitis: Diagnosis

Tenosynovitis frequently presents during a physical exam with tenderness, pain, swelling and inflammation of the ankle and foot.^{4,1,7} Anatomical factors such as a pes cavus or pes planus play a role in tenosynovitis and can be visualized by visual imaging sources like ultrasound and MRI.^{8,2} X-ray techniques, however, are not preferred because they do not accurately identify structural foot deformities like ultrasound can. This may be due to the X-ray image's "lack of clear distinction between normal and pathological structures".⁶ Early diagnosis of tenosynovitis is important so that it does not progress into a more critical condition and complications do not arise.⁶

Ultrasound, which is also termed sonography in several studies, can be used as a diagnostic tool and has been proven helpful in diagnosing patients with tenosynovitis. According to Mastos et al.⁸ there are many advantages to using ultrasound for tenosynovitis, such as its sensitivity. In this case report, the patient selection included a variety of parameters: patients with no previous diagnosis of inflammatory arthritis, patients on treatment for a known diagnosis, and patients with a chronic or previous history of arthritis linked with a recurrence of symptoms. To confirm the effectiveness of an ultrasound, a Likert scale was used before and after examination of the patient and their specific joints. The tendons surrounding the requested joints were consistently checked for the presence or absence of tenosynovitis. Certainty of the physician in their diagnosis of tenosynovitis increased significantly following the use of ultrasound. Physician certainty increased from

9.7% certain, pre-ultrasound to 46.8% certain, post-ultrasound with a p value < 0.0001. This study suggests that ultrasound provides an accurate and confident diagnosis of inflammatory disorders such as tenosynovitis.⁸ In the case report by Faraj et al.¹ citing *Neisseria gonorrhoea* as the causative agent, ultrasound examination revealed tenosynovitis around the extensor hallucis tendon, with no damage seen on the tendon itself. The visualization of this tenosynovitis and fluid confirmed the necessity of a needle aspiration of the synovial fluid around the EHL tendon.

According to Kesikburun et al.⁶, other advantages to ultrasound include the cost effectiveness, noninvasiveness, and repeatability in diagnosis of tenosynovitis. We reviewed a case report in which a 21-year-old man, with no history of trauma or rheumatic disease, presented with swelling on his right ankle and foot. Physical examination showed tenderness and edema at the level of his medial malleolus and dorsum of the foot. The patient experienced pain on flexion and inversion of the foot and a high longitudinal arch on his right foot. Plain radiography displayed no bony pathology but also showed an increased calcaneal plantar angle on the lateral view. A transverse ultrasound image of the medial ankle reveals inflammation of the tibialis posterior, flexor digitorum longus and flexor hallucis longus tendons. The sonography showed effusion in the tendon sheaths surrounding the tendons.⁶

Based upon our review, the benefit of using MRI in the identification of tenosynovitis is unclear. Two cases were reviewed which argued each side. In a study performed by Gluck, the most important diagnostic tool was an MRI because it showed inflammation and edema, while ultrasound was reported to be useful in recognizing only the edema associated with the tenosynovitis.² On the other hand; a study performed by Heckman showed that MRI had a low 17% sensitivity and 100% specificity for viewing peroneal tenosynovitis. It is noted that identification of peroneal tenosynovitis is sometimes difficult since the fluid within the peroneal tendon sheath can be asymptomatic in some patients. Heckman et al.³ states that MRI sensitivity increased to 38% when diagnosing peroneal tenosynovitis combined with chronic lateral ankle instability. However, artifacts were reported to appear when fibers are oriented 55 degrees to the magnetic field axis according to the basis of the magic angle phenomenon. In this study, another disadvantage of MRI was

that it tended to overvalue problems with the peroneal tendon.³

Tenosynovitis: Treatment

Treatment of tenosynovitis can be in the operative or non-operative form. Non-operative techniques involve stabilizing the tendon and restricting movement through the use of a cast or removable fracture boot for several weeks. Pain and inflammation can be eased with the use of medication such as NSAIDs. These practices combined with physical therapy should be the initial non-operative treatment before any type of surgery is considered.²

We reviewed cases in which the cause of tenosynovitis was rare or specific, so the most effective treatment in these cases was unique to the cause. In the case report of tenosynovitis due to the use of an antibiotic Ciprofloxacin presented by the Kayabas et al.⁵, a dose of itraconazole at 400mg/day and ulcer debridement was used for treatment. In response to a prototheca species induced tenosynovitis; patients were in need of surgical and antifungal agents in order to relieve their symptoms. MRI done at a 5 month follow-up showed a disappearance of tenosynovitis of the extensor hallucis longus tendon and the skin lesion.⁷ In the case report conducted by Faraj et al.¹ *Neisseria gonorrhoea* was the causative agent of tenosynovitis and treatment with oral ciprofloxacin relieved the patient's symptoms.

If no progression is made with non-surgical procedures, surgical options are available to alleviate the symptoms associated with tenosynovitis. One such surgery performed is tendon debridement along with tenosynovectomy.³ During these surgeries, the tendon sheath is opened longitudinally and precautions should be taken to avoid injury to the sural nerve. After opening the sheath, inspection of the inflammation and erythema should be done. Following the initial inspection inside the tendon sheaths, debridement of granulation tissue around the tendons must be performed. If a peroneus quartus muscle or peroneal tubercle is present, it should be excised.⁵ If there are other structural abnormalities contributing to the biomechanical stresses of the patient, they should also be taken care of during the surgery in order to ensure total symptom and pain relief. Post-operatively, weight bearing will be allowed after 2-3 weeks. Exercises to strengthen the foot and increase range of motion should be done at 4-6 weeks after surgery. Delaying diagnosis or treatment of tenosynovitis can lead to greater inflammation and tendon ruptures.³ According to Gluck et al.², surgical treatment for tenosynovitis yielded better results than non-surgical treatment. The results showed that six out of seven patients suffering from tenosynovitis were cured of symptoms after surgeries.² Another surgical option is tendonoscopy.¹⁰

Table 1: Summary of the Study: Tenosynovitis of the Lower Extremity

	Example:	Citations:
Causes:	Gonococcal Infection	Faraj <i>et. al.</i>
	Drug induced (Ciprofloxacin use)	Kayabas <i>et. al.</i>
	Protothecal Infection (Fungi)	Lee <i>et. al.</i>
	General Trauma/Overuse	Helal
	Anatomical Predisposition	Heckman <i>et. al.</i>
Diagnosis:	MRI	Gluck <i>et. al.</i>
	Ultrasound	Matsos <i>et. al.</i>
	Physical examination	Kesikburun <i>et. al.</i>
	X-Ray/ Radiograph	Kesikburun <i>et. al.</i>
Treatment (non operative):	Tendon stabilization with casting/boot, NSAIDs, Physical Therapy	Gluck <i>et. al.</i>
Treatment (operative):	Tendoscopy	Scholten <i>et. al.</i>
	Tendon debridement/	Heckman <i>et. al.</i>
	Tenosynovectomy	

Information on possible causes, diagnosis and non-operative/operative treatment procedures of Tenosynovitis seen in the lower extremity. Citations correlate with research that found the causative agents, sufficient diagnostic tool, and effective treatment procedures for the identification and recovery from tenosynovitis.

The use of tendonoscopy minimizes injury to the sural nerve and superficial peroneal nerve as well as scarring, infection, and stiffness in the joints. This surgical procedure can be used for various peroneal tendon disorders including tenosynovitis. This surgery is an outpatient procedure and requires the use of local anesthesia into the sheath of the tendon to affect the nerves in that compartment. The surgical entrance and removal of the synovial sheath was through surgical portals made.¹⁰ After surgery, there is no need for restriction of motion and activity is encouraged. Out of 23 peroneal tendon surgeries, 10 of which were due to tenosynovitis, there was no relapse of the peroneal tendon disorder in all cases.¹⁰

Conclusion

Treatments for tenosynovitis can be in either non-operative or operative forms. Two main non-operative approaches are tendon stabilization by cast or removable fracture boot. To cope with uncomfortable symptoms, NSAIDs can be used. If non-operative methods are unsuccessful in relieving symptoms, the patient should opt for surgical treatment. According to Heckman et al.³, tendon debridement and tenosynovectomy are common operative treatments for tenosynovitis. A report by Scholten et al.¹⁰ suggests that a tendonoscopy can be performed to treat tenosynovitis while minimizing invasiveness and damage to surrounding neurovascular structures. If there are structural abnormalities also contributing to tenosynovitis and its symptoms, Heckman et al.³ report that they should be removed surgically in order to experience total relief of tenosynovitis symptoms. Depending on the case presented and the resources available, clinicians should consider both the non-operative and operative options when treating tenosynovitis.

In terms of diagnostics, the different sources we reviewed showed conflicting views, so it is difficult to single out a superior diagnostic tool. However, it should be noted that we found the most common tool used in diagnosis of tenosynovitis to be ultrasound. In a study performed by Gluck et al.², MRI was helpful in identifying both edema and inflammation in tenosynovitis whereas ultrasound was only useful in identifying the edema. However, a study reported on by Heckman et al.³ showed MRI to be only 17% sensitive in identifying peroneal tenosynovitis. According to a study by Mastos et al., ultrasound is not only more cost effective than other methods, but also more

sensitive in diagnosing tenosynovitis than both physical examination and radiography. A study by Kesikburun et al.⁶ showed that ultrasound or sonography was useful, inexpensive and noninvasive. It is important to note that the information we reviewed on diagnostic tools were often specific to a muscle group of the lower extremity. We extrapolated this information in order to apply it to the general topic of tenosynovitis (Table 1). Each case of tenosynovitis can manifest differently, so it is important that clinicians diagnosing the condition are aware of the advantages and disadvantages of each tool. After review of these reports, we feel that the best form of diagnosis of tenosynovitis is the use of both ultrasound and MRI, if available. Due to the conflicting nature of the articles reporting on diagnostic devices for tenosynovitis, it is clear that more research can be done to compare each diagnostic modality.

Tenosynovitis of the lower extremity is inflammation of the tendon sheath and can have many etiologies. Specifically, anatomical foot variations such as a shallow retromalleolar sulcus or pes cavus have been reported to contribute to tenosynovitis.⁶ However, there are non-anatomical causes of tenosynovitis to be aware of as well. A rare bacterial cause reported on by Faraj et al.¹ is *Neisseria gonorrhoeae*. This bacterium is known to invade the synovial fluid of the joint spaces and is not commonly found in tendon sheaths, but was presented as the primary cause of tenosynovitis in this case. Lee et al.⁷ presented a prototheca algae infection as another cause of tenosynovitis. This organism, *P. wickerhamii*, is ubiquitous in nature and usually does not cause infection in healthy individuals. In this report, the organism was responsible for causing tenosynovitis in a healthy, immuno-sufficient patient with general complaints of pain. Although it was a rare finding, it was reported that other cases have been found, and the scientific community should be aware of such infections.

Originally used to treat urinary tract infections, the antibiotic ciprofloxacin is not frequently seen as a source of tendon inflammation. However, in the report by Kayabas et al., the drug was found to be the cause of the patient's tenosynovitis. It was discussed that ciprofloxacin inhibits the metabolism of tenocytes and decreases cell proliferation, collagen and matrix synthesis. This could be the reason for the tendinopathy and tenosynovitis seen in the patient. It is important to note that ciprofloxacin is a commonly prescribed antibiotic for bacterial

infections, and was the medication used to cure the tenosynovitis caused by *Neisseria gonorrhoeae*.¹ Thus, more research should be conducted on antibiotic interactions and their adverse effects in relation to tenosynovitis. While these causative agents may be rare in relation to tenosynovitis to clinicians, these recent studies should be taken into consideration and applied to medical practice.

For our review, we did not focus on tenosynovitis in each specific muscle of the lower extremity since every tendon, with the exception of the calcaneal tendon, has a synovial sheath susceptible to tenosynovitis. It seems that there is a lack of meta-analyses and systematic reviews available to the medical community on the topic of tenosynovitis. As a result, many of the reports we reviewed were about specific muscle conditions and not directly on the topic of tenosynovitis. Furthermore, the lack of literature solely on tenosynovitis of the lower extremity limited our review to case reports and expert opinions. It is possible that our search criteria excluded certain topics of tenosynovitis, which may have lead to error.

Authors' Contributions

JH, HA, JR, and GL contributed equally in the production of this manuscript.

Statement of Competing Interest

The author's declare no competing interests in regards to this manuscript.

References

1. Faraj S, Clarke DS. Acute extensor hallucis longus tenosynovitis caused by gonococcal infection. *The New Zealand Medical Journal* (2003); 116
2. Gluck G, Heckman D, Parekh S. Tendon Disorders of the Foot and Ankle, Part 3: The Posterior Tibial Tendon. *Am J Sports Med* 2010; 38(10):2133-43.
3. Heckman D, Reddy S, Pedowitz D, Wapner K, Parekh S. Operative Treatment for Peroneal Tendon Disorders. *The Journal of Bone and Joint Surgery, Inc.* (2008); 90:404-18.
4. Helal B. Tenosynovitis. *J R Soc Med* (1987); 80(2): 68-69.
5. Kayabas U, Yetkin F, Firat AK, Ozcan H, Bayindir Y. Ciprofloxacin-Induced Urticaria and Tenosynovitis: A Case Report. *Chemotherapy* (2008); 54: 288-290.
6. Kesikburun S, Aydemir K, Günendi Z, Özgül A. Tenosynovitis of the Flexor foot tendons secondary to pes cavus: value of sonography. *Rheumatol Int* (2011) Epub.
7. Lee JS, Moon GH, Lee NY, Peck KR. Case Report Protothecal Tenosynovitis. *Clin Orthop Relat Res* (2008); 466: 3143-3146.
8. Matsos M, Harish S, Zia P, Ho Y, Chow A, Ioannidis G, Khalidi N. Ultrasound of the hands and feet for rheumatological disorders: influence on clinical diagnostic confidence and patient management. *Skeletal Radiol* (2009); 38:1049-1054.
9. Ogut T, Ayhan E. Hindfoot endoscopy for accessory flexor digitorum longus and flexor hallucis longus tenosynovitis. *Foot and Ankle Surgery* 2010; 17:7-9.
10. Scholten P, van Dijk CN. Tendoscopy of the Peroneal Tendons. *Foot Ankle Clin N Am* (2006); 11: 415- 420.

Bilateral Tarsal Tunnel Syndrome as a Sequela of Bilateral Clubfoot Surgery: A Case Report

Chioma Odukwe, MS*

Abstract

Introduction:

Clubfoot is a common structural and functional deformity with a multi-factorial etiology. Serial manipulation and casts as well as surgery are well documented for correction of the deformity. Severe, recalcitrant and neglected clubfeet are usually undertaken using surgical treatment. There are a handful of long-term follow-up studies in the literature concerning patients who have undergone surgical correction for clubfoot. The commonly reported long-term complications of clubfoot surgery include arthritis, tendinopathy, neuropathy, and remnants of overcorrection or undercorrection.

Study of Design:

Case Report

Methods and Results:

Presented is a case report of a patient who presented with bilateral tarsal tunnel syndrome thirty years after attempted surgical correction for bilateral clubfoot deformity. To the best of the authors' knowledge, such presentation has not been previously described.

[Level of Evidence: 4]

*DPM, Class of 2012

Introduction

Clubfoot or congenital idiopathic talipes equinovarus is a common structural deformity occurring in one to three per thousand live births¹. The condition consists of both osseous and soft tissue abnormalities. Structurally described, there is equinus at the ankle and at different joints of the foot, adduction at the midfoot and varus of the rearfoot and ankle^{1,2}. Other structural deformities have been described at the tibia and other parts of the body as a result of a syndromic effect.

Treatment for congenital clubfoot, although controversial, is widely accepted and should start as early as possible. The aim of treatment is to obtain a straight, painless, plantigrade, and mobile foot with normal radiographic appearance¹⁵. Serial casting and manipulation adopting the Ponseti or Kite methods^{10,11} are the main stays of initial conservative treatment. Serial casting and manipulation are especially crucial in the skeletally immature and non-ambulatory patient. However, with severe deformity or failed conservative treatment, surgery is undertaken. Common surgical treatments include soft-tissue releases (specifically postero-medial releases of muscles and ligaments) at the subtalar and midtarsal joints, Achilles tendon lengthening, and osseous realignment as needed.

Accompanying surgical treatment are possible complications both short and long-term.

Commonly reported complications with soft tissue releases are arthritis, scar tissue formation, stiffness of the ankle and subtalar joints, overcorrection, under-correction, muscle weakness, and pain^{4,13}. Another reported complication is sinus tarsi syndrome¹⁴.

In this report, a case of congenital bilateral clubfoot was treated with postero-medial soft tissue releases that led to scar tissue formation at the surgical site. The scar tissue and fibrosis resulted in compression of the tibial nerve leading to signs and symptoms resembling tarsal tunnel syndrome.

Tarsal tunnel syndrome has been classically described as an entrapment of the tibial nerve behind the medial malleolus and under the flexor retinaculum^{3,5,6}. The etiology of this entrapment has been attributed to several factors, some of which include trauma, fibrosis or scar tissue around the nerve, varicosities, biomechanical and structural abnormalities, neuropathy, space-occupying lesions or an accessory muscle belly⁵. The clinical presentation is typically posteromedial ankle pain and tenderness over the medial malleolus. Percussion over the area of the tibial nerve behind the medial malleolus may produce a positive Tinel and/or Valleix sign. A positive Tinel or Valleix sign is a sensation of 'pins and needles' distally or proximally and distally along the nerve distribution respectively. Some patients may have paresthesia and others may complain of other altered sensory changes,

such as changes in two-point discrimination or proprioceptive capability. Radiographs may help rule out a bony etiology, however an MRI is more helpful. Ancillary studies such as nerve conduction velocity and electromyography may also be performed to evaluate the intrinsic muscles of the foot.

Case Report

A 38-year old Hispanic male presented to the clinic with a one-year history of worsening pain and swelling in his feet and ankles. He described the pain as most intense with weight-bearing activities. He had no complaint of pain at rest although pain was produced with changes in foot and leg position. No previous trauma was attributed to the condition and the patient had sought medical help prior to clinical presentation. He was subsequently referred to our clinic. His past medical history is highlighted

with clubfoot surgery performed in Puerto Rico in 1974 when he was a year old. He is otherwise healthy and denies smoking or use of recreational drugs.

On physical exam, dorsalis pedis and posterior tibial pulses were palpable and regular. Dermatological exam revealed edema and an extensive surgical scar inferior to the medial malleoli. Passive range of motion was marked with stiffness at the ankle, subtalar and midtarsal joints with pain elicited upon each maneuver. Pain on palpation was present at the posteromedial ankles and extended medially towards the midfoot at the navicular bone. Mild edema was noted over the medial peri-malleolar area. Percussion of the tarsal tunnel area produced both Tinel's and Valleix signs bilaterally. Weight-bearing exams demonstrated loss of the medial longitudinal arches, valgus position of the rearfoot and abduction of the forefoot.

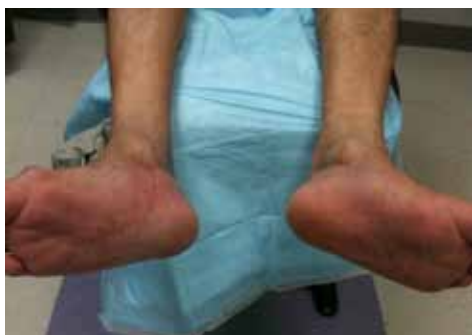

Figure 1.

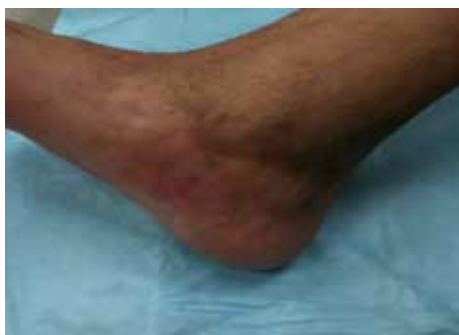

Figure 2.

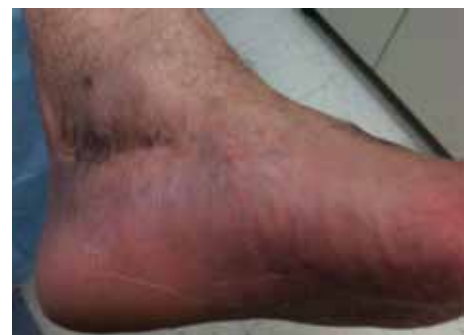

Figure 3.

Figures 1-3: Initial clinical presentation: Note the edema and visible scar tissue surrounding the medial malleoli.

The preliminary diagnosis of tarsal tunnel syndrome was made based on the clinical examination. A referral was made to the neurology clinic in order to obtain quantitative nerve conduction velocity and electromyography results. The patient was initially managed with a bilateral injection of 6cc 0.5% Marcaine plain and 1.5cc Kenalog-10 into the tarsal tunnel area. He was also referred to physical rehabilitation medicine.

The condition was discussed with the patient citing both conservative and surgical treatment. There were inconsistencies of the patient in keeping clinical appointments and referrals. He has been fitted for accommodative shoes. At the writing of this report, the patient is in Puerto Rico.

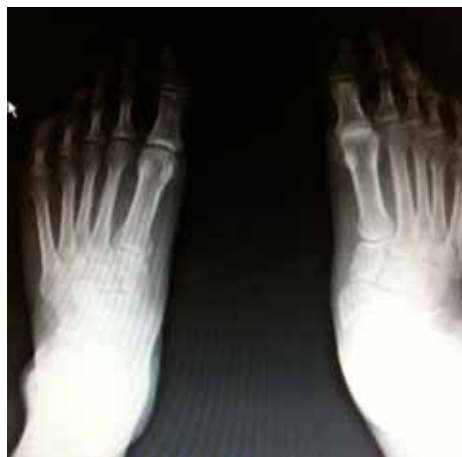

Figure 4.

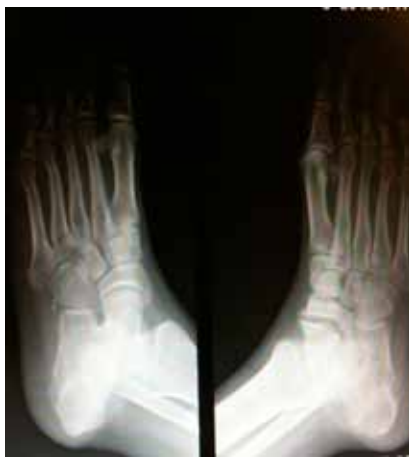

Figure 5.

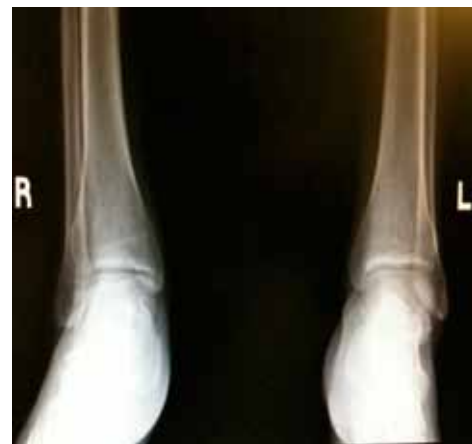

Figure 6.

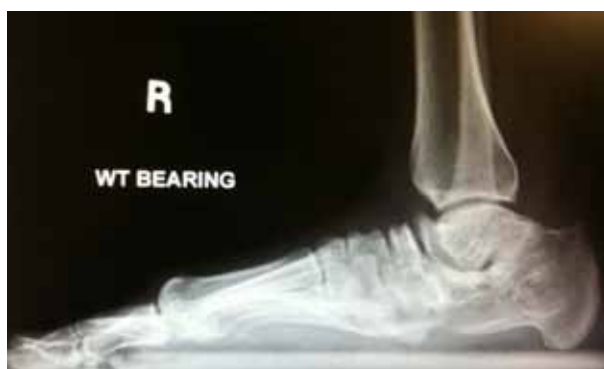

Figure 7.

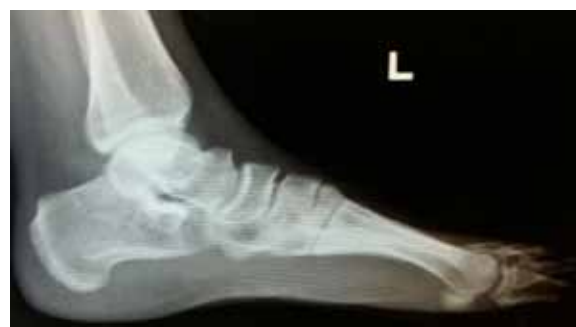

Figure 8.

Figures 4-6: Plain radiographs demonstrating diffuse arthroses and chronic deformity of the talus and navicular. **Figures 7-8:** The lateral view demonstrates a low calcaneal inclination angle, ptosis of the midfoot, and first metatarsal elevation.

Discussion

Tarsal tunnel syndrome as a sequela of clubfoot surgery is rare in the literature. Literary findings mostly report arthritis, stiffness, muscle weakness, pain and residual structural deformity as major complications of extensive soft tissue release^{15,16,17}. The closest in the literature correlating clubfoot and neural abnormality is a study of children with clubfeet where 57% had abnormal EMG-NCV studies of the peroneal nerve⁸. The authors reported that peroneal mononeuropathy was the most common disorder involving 41% of the subjects who had undergone surgical correction for clubfoot. Anatomically, the surgical site of the soft tissue release overlies the course of the tibial nerve. Therefore, scar tissue formation at this site is the most probable source of entrapment

and irritation to the nerve. However, there is no explanation enlightening why this specific complication is so rare given that many soft tissue releases are performed in this area of the foot. It is possible that the surgeon's technique in Puerto Rico may be the reason for this pattern of scar tissue formation. Alternatively, the patient's own physiology and ability to produce exuberant fibrosis could be another reason. Correspondingly, other complications of clubfoot surgery reported in the literature such as arthritis, stiffness, and weakness were also present in this patient, further substantiating prior observations.

One limitation to the completeness of this report is that ancillary test results for nerve conduction velocity and MRI have not yet been obtained. Another limitation is that the patient has not yet been evaluated following

physical rehabilitation. In the future, it is hoped that such results will be obtained and an update will be written to this case report.

Conclusion

Clubfoot is a common condition whose incidence has remained constant. Surgical treatment protocol remains controversial with a movement away from surgery and more towards less invasive treatment with casting and manipulation¹⁹.

Surgery for treatment of clubfoot has undergone changes in its technique and implementation. A resurgence of the Ponseti method in the 1990's has prompted several studies comparing short and long-term outcomes of conservative treatment and surgery. The results are mixed, some in favor either of conservative treatment or surgery. A 2006 study assessing forty-five patients reported a direct correlation between the extent of the soft tissue release and the degree of functional impairment¹³. Another study draws a comparison between patients treated with serial manipulation and casting versus surgical treatment¹⁸. In this study, the relapse rate at two years was higher with conservative treatment than with surgery. Yet another study demonstrated a substantial decrease in the rate of clubfoot surgery performed in the United States¹⁹. Between 1996 and 2006 there was a decline in surgery at a rate of 6.7% decreasing from 70% in 1996 to 10% in 2006.

There is continued need for further research and long-term follow-ups of patients who have undergone clubfoot surgery. Increased availability of these studies will further educate health-care providers in the most cost-effective method for management of idiopathic clubfoot.

Statement of Competing Interest

The author denies any competing interests in regards to this manuscript.

References

1. Sureshwar P, Anil, KP. The classification of clubfoot a practical approach. *The Foot*. 2003; 13:61-65.
2. Pagnotta G, Boccanera F, Rizzo G, Agostino R, Gougoulakis N, Maffulli N. Bilateral Clubfoot in Three Homozygous Preterm Triplets. *J Foot Ank Surg*.2011;50:718-720.
3. Gould JS. Tarsal Tunnel Syndrome. *Foot Ankle Clin*. 2011;16:275-286.
4. Brodsky JW. The Adult Sequelae of Treated Congenital Clubfoot. *Foot Ankle Clin*. 2010; 15:287-296.
5. Saar WE, Bell J. Accessory Flexor Digitorum Longus Presenting as Tarsal Tunnel Syndrome: A Case Report. *Foot Ankle Spec*. 2011;4(8)-379-382.
6. Rodriguez D, Devos Bevernage B, Maldague P, Deleu PA, Leemrijse T. Tarsal tunnel syndrome and flexor hallucis longus tendon hypertrophy. *Orthop Traumatol Surg Res*. 2010; 96(7):829-831.
7. Baghla DP, Shariff S, Dega R. Calcaneal osteomyelitis presenting with acute tarsal tunnel syndrome: a case report. *J Med Case Reports* 2010. 23;4:66.
8. Thometz J, Sathoff L, Liu XC, Jacobson R, Tassone JC. Electromyography nerve conduction velocity evaluation of children with clubfeet. *Am J Orthop*. 2011;40(2):84-86.
9. Matos MA, Alcantara de Oliveira LA. Comparison Between Ponseti's and Kite's Clubfoot Treatment Methods: a Meta-analysis. *J Foot Ank Surg*.2010;49:395-397.
10. Ponseti IV, Current concept review. Treatment of congenital clubfoot. *J Bone Joint Surg*.74-A(3) 1992;448-454.
11. Kite JH. Principles involved in the treatment of congenital clubfoot. *J Bone Joint Surg*.1939;21:595-606.
12. Gelder JH, van Ruiten AGP, Visser JD, Maathis PGM. Long-term Results of the Posteromedial Release in the Treatment of Idiopathic Clubfoot. *Pediatric Orthop*.2010;30:700-704.
13. Dobbs, MB, Nunley R, Schoenecker PL. Long-term Follow-up of Patients with Clubfeet Treated with Extensive Soft-Tissue Release. *J Bone Joint Surg*.2006;88-A(5):986-996.
14. Giorgini RJ, Bernard RL. Sinus tarsi syndrome in a patient with talipes equinovarus. *J Am Podiatr Med Assoc*. 1990;80(4):218-222.
15. Ippolito E, Farsetti P, Caterini R, Tudisco C. Long-term comparative results in patients with congenital clubfoot treated with two different protocols. *J Bone Joint Surg Am*.2003;85:1286-1294.
16. Aronson J, Puskarich CL. Deformity and disability from treated clubfoot. *J Pediatr Orthop*. 1990;10:109-119.
17. Hutchins PM, Foster BK, Paterson DC, Cole EA. Long term results of early soft tissue release in club feet. *J Bone Joint Surg Br*. 1985;67:791-799.
18. Clarke N, Uglow MG, Valentine KM. Comparison of Ponseti Versus surgical Treatment in Congenital Talipes Equinovarus. *J Foot Ank Surg*.2011;50:529-534.
19. Zionts L, Guofen Z, Hitchcock K, Maewal J, Ebramzadeh E. Has the Rare of Extensive Surgery to Treat Idiopathic Clubfoot Declined in the United States? *J Bone Joint Surg Am*. 2010;92:882-889.

The Point of Being “En Pointe”: Biomechanical Stresses and Injury in Classically Trained Ballet Dancers

Ilya Shnitser, BA and Alicia Attanasio, MS

Abstract

Introduction:

Classical ballet is a beautiful art form that requires a dancer to endure rigorous physical stresses. This review systematically examined the current literature in dance medicine to give a detailed assessment of the biomechanical demands placed on a ballet dancers' body and the associated injuries, specifically to the foot and ankle region.

Study of Design:

Qualitative Systematic Review of the Literature

Methods:

The reviewers searched electronic databases PubMed and PubMed Central, which yielded 46 pertinent articles. Of the 46 publications, 9 were determined to be relevant to the aim of the review. Additional hand searches were performed for topic specific injuries.

Results:

As is the nature of dance, especially ballet, is one that is rooted in repetition of core movements and positions. The most commonly cited cause of lower extremity injury has been attributed to overuse, which correlates well with the strenuous rehearsal schedule dancers endure daily. Repetitive extreme plantarflexion like that seen in dancers on pointe for example is one of the many causes of career ending injuries in dancers.

Conclusions:

Early identification of injury through modalities such as X-ray, CT, and MRI is essential to the therapeutic treatment of the injury and in the preservation of a professional dancer's career. Most dancers despite their painful injuries will endure to further their career. This is precisely why educating dancers on the stresses placed on their bodies and the identification of injury is paramount.

Key Words: ballet, injuries

Level of Evidence: 4

Introduction

"It takes an athlete to dance, but an artist to be a dancer." - Shanna LaFleur

Dancers have the unique ability to contort their bodies to convey their artistic message. Successful dancers need to be athletic, strong, flexible yet graceful. However, conveying their artistic message does not come without it's own inherent cost. The demands placed on a dancers body, specifically in the foot and ankle region are tremendous. It has been reported that the injuries of female ballet dancers account for 34-64% of all injuries in female athletes annually⁸. The most commonly cited cause of injury in dancers has been due to overuse. This is particularly relevant in the context of the hierarchy of the ballet dance company in which members of the corp are constantly performing repetitive movements during rehearsals and shows. In fact it has been estimated that in consideration of the entire body as far as overuse injury, the lower extremity is involved

20% of the time, the ankle 15% and the foot 15% overall¹.

What causes injuries in dancers? This question requires a multifactorial answer. For start, environment plays an important role in injury. This is due to the fact that dancers are required to practice and rehearse for multiple hours a day. Dance studios and theaters are often cold in temperature, with hard, unforgiving surfaces on which the dancer is to perform. Also, with respect to the nature of the profession, dancers are required to learn new choreography and techniques at a moments notice. It is within this window period where the chances of a dancer getting injured rises. This is due to the reality that with new choreography comes the increased possibility of damaging technical errors⁸. Improper technique is not only detrimental to the art but places the dancers body out of proper alignment and places biomechanical stresses on the lower extremity that would not otherwise be administered. The nature of dance, specifically ballet is one that is

rooted in repetition of core movements and positions, including; “turnout” or an outward positions of the leg and foot, set in different orders and at different tempos. Ballet dancers are notorious for repetitive biomechanical stresses placed on the lower extremity⁴. In conjunction with these stresses to the foot and ankle are certain biological and social factors that can help facilitate injury. Termed the “Female Athlete Triad”⁸, it has been described that concurrent conditions such as amenorrhea, eating disorders and low bone density can significantly predispose female ballet dancers to stress fractures.

One thing that separates ballet from the other dance specialties is the utilization of the positions of “en pointe” and “demi-pointe”. These positions place extensive stresses on the foot and ankle, with the effects traveling as high as the back³. The spectrum of types injuries seen in dancers spans from acute to chronic, soft tissue to osseous injuries and includes a variety of injuries that are specific to ballet dancers. This articles aims to review some of the various foot and ankle injuries seen in ballet dancers, especially those dancers on pointe. It also serves to discuss the biomechanical demands this unique art form places on the lower extremity and to give a brief overview of the diagnostic modalities available in the identification and treatment of dance injuries.



Figure 1: *Ballet Dancer “en pointe”*
It is important to appreciate the extreme ankle plantarflexion required for dancers to dance “en pointe”.

Methods

For this literature review the electronic databases searched for references included PubMed and PubMed Central. The MeSH terms “ballet” AND “injuries” keyword combinations were utilized to find the most sensitive material. Search limits were set to include only full text articles published in the English language. All study designs and publication dates were included. MeSH terms, with search parameters yielded a total of 46 articles. Of the 46 full text articles only 26 were relevant to the lower extremity, the aim of the literature review. Inclusion criteria, “ballet specific injuries”, and exclusion criteria, “lower extremity”, were applied to all the studies retrieved by the searches. At this stage using the titles and abstracts of the articles of the 26 publications, 9 articles were selected for use in the publication. Additional hand searches in foot and ankle and sports medicine specific journals was preformed for topic specific injuries, including but not limited to: “anterior impingement syndrome”, “posterior impingement syndrome”, “plantarflexion” AND “pointe”, “ankle sprains”.

Results

In total a cohort of 20 articles was used for the publication work. Of the 20 referenced publications; 4 pertained to ankle sprains, 2 cited ankle impingement syndromes, 2 related to stress fractures, 5 to the diagnostic modalities used in the treatment of dance injuries and 7 pertained to generalized stress/overuse injury. The combination of these articles was imperative in the portrayal of an accurate account of biomechanical stress induced injuries seen in professional ballet dancers. Since this review does not encompass every possible injury seen in dancers but rather the most commonly documented injuries, further search criteria could be useful in expanding the survey of injury in professional ballet dancers.

Dancing “En Pointe”

On pointe or “en pointe” is a dance position where the dancer weight bears fully, in complete plantarflexion on the tips of the toes, in specially designed pointe shoes⁴. This particular dance position provides an illusion of the ballet dancers being “weightless” as if they are dancing on air. The pointe shoe is a special shoe that is designed specifically for ballet and is comprised of a toe box, which usually is a narrowed extension and embodies the tip of the foot, a shank, which supports the arch of the foot, and

usually a satin cover, which is the outside of the shoe and holds all of the components of a pointe shoe together¹⁹. The shank and the hard toe box provide the needed stability to the foot while on pointe.

Ballet dancers dancing on pointe require a great amount of muscle strength in the foot and ankle, and significant amount of plantarflexion of the ankle joint. The dancers body weight is mostly supported by the tips of the toes, which are in neutral position relative to the longitudinal axis of the foot. According to the research, the total pressure on the toe box while on pointe is 1.5 MPa. The majority of the weight is on the first toe and ranges between 0.14 and 0.58 MPa. The pointe shoe absorbs some of the pressure, but the foot and the ankle also absorb about 70% to 80% of pressure⁸.

Dancing on pointe is one of the major goals many female ballet dancer work to achieve. However, the attainment of this goal come with both it's own rewards and failures. For this reason there are many guidelines that are to be followed prior to a dancer beginning to dance on pointe. Some of these guidelines are "dancers' age, usually 12 years old, stage of physical and mental maturity, strength and control of the core, the strength and stability of feet and ankles, and duration of dance training¹⁹." It is important to recognize that following the guidelines aids in limiting the amount of injuries associated with dancing on pointe, but does not fully eliminate the risks.

Acute Injuries In Dancers

Ankle sprains make up one of the most common acute sports related injuries, accounting for about 14% of all-sport related injuries. Ligamentous inversion injuries, about 80%, are the most common amongst dancers⁵. Most sprains involve lateral ligamentous structures and are caused by forced rapid inversion of the foot. When the foot is in plantarflexion, such as on pointe, the talus is unstable in the mortise and the only lateral structure that restricts lateral movement is the anterior talofibular ligament. Therefore, rapid inversion may result in full or partial tear of the anterior talofibular ligament. In fact, among lateral ankle sprain injuries, 73% involved isolated rupture or tear of the anterior talofibular ligament^{5,8}. Having prior history of ankle sprains may predispose a dancer to future ankle sprain injuries.

Ankle sprain injuries with any bony tenderness over the ankle or lateral foot should

be evaluated with radiographs and if the symptoms are persistent for over a week, a CT scan should be obtained. Most ankle sprain injuries in dancers are treated conservatively with rest, compression dressing, and ice massage. However, treatment may depend on the severity of the sprain. The severity of the ankle sprain may be classified on a grading scale and may aid in choosing the correct treatment options.

The goal of early and effective treatment options in dancers is required to regain and strengthen the mobility and range of motion of the hindfoot and midfoot joints, which are required for ballet dancers to dance on pointe.

Stress fractures of the metatarsals in athletes represents about 9% of all stress fractures and affected 12.6% of ballet dancers who had not reached skeletal maturity¹. Although, most stress fractures in dancers are found in metatarsals, but they also may be found in fibula, tibia and hip. Biomechanical factors related to higher risk for stress fractures are external hip rotation greater than 65 degrees, forefoot varus, poor ankle joint dorsiflexion, and dancers with a over pronated foot type. The frequent loading and unloading of metatarsal bones on a hard training surface greatly hinders the process of bone remodeling, thereby weakening the bone and increasing the risk of fractures. Research has shown that other factors such as poor nutrition, eating disorders, low body weight, amenorrhea of more than 90 days and osteoporosis increase the risk of developing stress fractures^{1,8}.

Dancers as opposed to other athletes are more susceptible to getting stress fracture of the base of the second metatarsal and a spiral fracture of the distal one-third of the fifth metatarsal, which is also known as the "dancers fracture". This particular fracture occurs due to the dancers losing balance while on pointe and roll over to the lateral aspect of the foot. Usually the dancer will present with mild tenderness, dull pain that is not well localized and may occur during the night or while walking. However, diagnosing such fractures maybe difficult with plain radiographs since initially the results maybe normal, therefore they should be confirmed with a bone scan, CT and MRI which are sensitive and specific to stress fractures. Tests such as CT and MRI may aid in confirming the diagnosis of a stress fracture as early as two to eight days after the onset of symptoms.

Treatment of stress fractures are dependent on the severity of the fracture, however, rest,

restricted activity, physical therapy, and shock wave therapy may be recommended treatment modality. In fact Albisetti¹ et al. have found that medium external shock wave therapy has been shown to provide great results in the treatment of fractures in young dancers.

Subluxation of the cuboid has also been seen with lateral ankle sprains. Most injuries in dancers are from overuse and the constant movement from a pointe position to flat foot position has been shown to be detrimental to a dancers foot. The dancer will typically complain of lateral midfoot pain, inability to run, jump, and increased weakness and lack of intrinsic support

of the foot. The cuboid often subluxes to the plantar aspect of the foot and tenderness is usually on the plantar aspect of the cuboid. Treatment requires a manual reduction of the cuboid known as a “cuboid whip”, and strapping for stabilization of midfoot and rearfoot joints⁹.

The use of proper diagnosing and therapeutic modalities will aid with faster diagnosis and proper treatment options of stress fractures. Thus, enabling the physician to preserve and maintain the anatomical and functional components that dancers greatly rely on to continue to dance on pointe and practice their art form.

Table 1: Ankle Sprain Classification System

Grade	Symptoms	Treatment Options
Grade I: partial tear of anterior talofibular ligament	Mild tenderness and swelling, Able to bear weight and ambulate with minimal pain, No mechanical instability	Continue icing, rest, elevation, and compression, Air cast and serial taping
Grade II: incomplete tear of anterior talofibular ligament, with varying degrees of injury to the calcanealfibular ligament	Moderate pain and swelling, Some loss of motion and pain upon ambulation or while weight-bearing, mild to moderate instability	Compression dressing and posterior splint
Grade III: complete or close to complete tear of both anterior talofibular ligament and calcanealfibular ligament	Severe swelling, Unable to ambulate or bear weight, mechanical instability	Conservative treatment may heal with unpredictable results and ankle instability, Therefore surgical intervention may be required

Table adopted from Wolfe²⁰ and Fong⁵

Chronic Injuries In Dancers

Chronic injuries in ballet dancers can significantly impair a dancer’s ability to continue dancing to the level and quality required by a professional dancer. Chronic injuries for our purposes is defined as injuries that have evolved over a period of months to years and are often associated with some sort of degenerative process.

Tendinopathies of the foot and ankle have been traditionally described as overuse injuries occurring over an extended period of time in which there is persistent inflammation¹⁷. This endured overuse most commonly affects the tendons of flexor hallucis longus (FHL), the peroneus longus and brevis (PL, PB) and the Achilles tendon, although other tendons of the lower extremity are also susceptible⁷. Injury to

the FHL tendon is the most common tendinitis seen in classical ballet dancers in relation to the lower extremity. “Chronic tendinopathy of the FHL tendon leads to chronic pain, early arthritis and fibrosis with decreased range of motion”¹⁷. Achilles tendinopathy is the second most common tendon often injured due to dancer overuse. Specific to ballet, causative factors such as “ overtraining, overpronating of the foot, having poor flexibility of the gastrocnemius-soleus muscle, exercising on uneven surfaces and wearing inappropriate shoes for the activity”¹⁷ can all lead to Achilles tendinopathy.

However, recent research data has suggested that the complications associated with chronic tendinopathies are less about the inflammation and more likely related to the “mode, intensity or duration of the physical

activity changing in some way”¹⁷. When a tendon is exposed to consistent mechanical stresses and becomes injured it responds by activation of the inflammatory cascade. After the inflammation has subsided the site of injury is remodeled by the deposition of a new collagen matrix¹⁷. However, upon repeated injury the normal healing sequence is impaired and consequences such as disorganized deposition of collagen and fibrin deposition can occur.

Since it has been shown that most chronic tendon injuries are inherently not an inflammatory issue, dancers should be aware that the use of non-steroidal anti-inflammatory drugs (NSAIDs) alone is not a viable treatment option¹⁷. While research has yet to demonstrate the best course of treatment for these conditions it is clear that a reduction in physical activity is needed. By reducing the level of activity, the biomechanical stresses placed on the tendon diminish allowing the tendon to heal uninterrupted. It is also paramount that dancers work with a physical therapist to strengthen weakened areas and work on a more beneficial body posture. In cases where non-surgical treatment options have been exhausted, only then should surgical intervention be entertained¹⁷.

Anterior impingement syndrome of the ankle of a dancer refers to a decreased range of motion in the direction of dorsiflexion. The dancer often presents with pain and movement limitation with associated edema⁷. Anterior impingement has a number of causes but most commonly includes hypertrophied soft tissue or proliferation of osteophytes. Notably, current theory suggests that proliferation of osteophytes is a result of a dancer with a history of repetitive ankle sprains or repeated micro-trauma to the talar neck or tibia¹³. “It is well accepted that anterior impingement can occur without the formation of osteophytes secondary to entrapment of hypertrophied synovium or torn anterior lateral ligaments”¹³

The ability to dorsiflex is paramount to a ballet dancer’s technique including those involved in landing of various jumps, in plié and other associated barre work. Therefore dancers experiencing anterior impingement should seek medical evaluation early on. As was suggested for treatment of tendinopathy, surgical intervention should only be pursued after conservative treatment measures have been proven unsuccessful. In the case of osseous impingement whether associated with the talar neck or tibia, surgical intervention becomes

more likely¹³. However, the recovery period can be detrimental to a dancer’s career causing the dancer unable to return to peak performance for at least 6 months.

Posterior ankle impingement syndrome like that of anterior impingement syndrome is associated with a limitation to range of motion. However, in this particular case it is in the direction of plantarflexion. Ask any ballet dancers what it means to have a reduction or an inability to plantarflex and she will tell you that it practically inhibit her ability to dance at all. Plantarflexion often termed in ballet as pointe or pointing, is essential to performance. Almost all of the core features of ballet involve the foot in a pointed position at one period of time. A lack of plantarflexion is also detrimental to a ballet dancer who dances on pointe, as most if not all professional female ballet dancers do.

The causes of posterior impingement are numerous and varying in nature. However, they are most notably the result of lateral instability due to chronic lateral ankle sprains¹⁴. The mechanism of instability proceeds when: “The unstable lateral ankle allows the foot to move anteriorly from under the tibia during the dance maneuver of releve (rising to the toes). At the peak of releve anterior translation of the talus in the ankle mortise brings the posterior tibial plafond in approximation with the superior calcaneus and causes pain.”¹⁴

Due to the numerous ligaments of the posterior ankle region, posterior impingement can also be soft tissue in nature. From an anatomical perspective the ligaments: posterior talofibular, posterior intermalleolar and posterior tibiotalar (part of the Deltoid ligament) have all been shown to cause posterior ankle impingement, particularly in dancers¹⁴. Previously noted above, the flexor hallucis longus was the most common tendinitis seen in classical ballet dancers in relation to the lower extremity. It is of no surprise that it is also associated with posterior impingement. The FHL tendon anatomically travels in between the medial and lateral tubercles of the posterior aspect of the talus, making it highly susceptible to biomechanical stress at the level of the ankle.

No matter the type or cause of chronic injury it is important to remember that these pathologies can greatly affect the livelihood of a dancer. The dancer should seek medical evaluation and conservative therapy as soon as possible. Continuing to let biomechanical stresses relentlessly pummel a weakened area is undoubtedly a recipe for a change of career.

Diagnostic Modalities

Early identification of injury in dancers is paramount to the therapeutic treatment of the injury and in the preservation of a professional dancer's career. According to the American Academy of Orthopedic Surgeons the three most commonly used diagnostic modalities in orthopedic injury include the use of X-ray, CT and MRI.

X-ray has been reported to be the most widely used and the most common initially ordered diagnostic imaging technique by treating physicians. An x-ray essentially uses electromagnetic waves, a form of low dose radiation, to create an image of osseous structures of the body. In order for an x-ray film to be attained the body part in question must be held in a fixed position while electromagnetic waves are passed through it onto an imaging plate. Some of the conveniences of x-ray include the ability to shoot film at a wide variety of angles, and the fact that the healthcare cost is relatively minimal in comparison to other modalities. In terms of dancer's injuries x-ray has been useful in evaluating stress fractures, osseous dislocations, hallux rigidus and in determining the extent of a hallux valgus deformity⁸. Specifically, in the classification of hallux rigidus, which is an arthritic joint space narrowing of the metatarsalphalangeal joint, x-ray has been highly successful in demonstrating "joint space narrowing, subchondral sclerosis and osteophyte presence"⁸. Plain film radiography is also valuable in demonstrating tendon calcifications, which is often seen in chronic tendinopathies¹⁷.

Computed tomography (CT), aims to extend the success of the x-ray in combination with computer technology to provide a more detailed cross-sectional image of the body. It has been debated amongst clinicians and clinical researchers alike if plain film x-ray is sensitive enough in diagnosing sports injuries and in determining a treatment plan. Those who feel that x-ray is an initial, not a final diagnostic, marker often recommend single photon emission computed tomography (SPECT), in the study of injury in young athletes³. In a study by Gregory et al. it was determined that SPECT had 60% sensitivity and 85% specificity in determining spondylolysis in young individuals. However, it is important to remember that there is a considerable healthcare cost associated with CT.

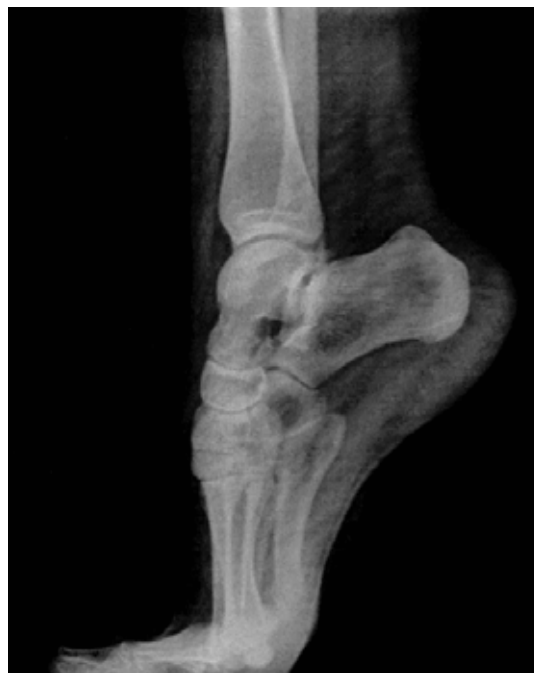

Figure 2: X-ray of Left Ankle in "demi-pointe"
Lateral x-ray of a ballet dancers' left foot in "demi-point" position.

Magnetic resonance imaging (MRI) has often been considered the "gold standard" of diagnostic modalities due to its ability to confer high resolution, cross-sectional images of both soft tissue and osseous structures. Although there are many forms of the imaging, T1 and T2 weighted images are most often used in sports related injury assessment. In a T1 weighted image water/fluid appears darkened while fat appears bright, in a T2 weighted image it is the reverse, in which fat is differentiated from water in that fat appears darkened and water/fluid appears lighter.

In a study by Russell¹⁵ et al. nine female ballet dancers were examined with the use of MRI (T1 & T2 images) in Gaynor Mindon pointe shoes to evaluate the extreme plantar-flexion that occurs at the ankle in dancers en pointe. The study goes on to discuss that not only is MRI an excellent way to assess pathology in the lower extremity of dancers but that it also helps to characterize the anatomical position of lower extremity structures. Understanding the positional relationship gives greater insight into the demands placed on the limb in the extreme positions seen for example in dancers en pointe.

No matter the imaging technique used it is important that injured dancers seek medical evaluation and treatment early on in the time line of the injury. The diagnostic modalities of X-ray,

CT and MRI although varyingly different all play an important role in the diagnosis and treatment of injuries in dancers.

Present on MRI	Number of Cases (n=9)	Percentage of Cases
Anterior tibial and/or talar spurs	4/9	44%
Bone marrow edema	1/9	11%
Stieda's process	4/9	44%
Synovitis or joint effusion	6/9	67%
Flexor hallucis longus tenosynovitis or tendinosis	2/9	22%
Widened anterior ankle joint congruity: Weight-bearing "en pointe"	5/8*	63%
* Total case count less than 9 due to poor quality of MRI image.		

Table 2: Pathologies Seen on MRI

**Table adopted from Russell et al.¹⁵*

Summation of pathological findings seen on MRI in nine female ballet dancers.

Conclusion

"Ballet technique is arbitrary and very difficult. It never becomes easy--it becomes possible. The effort involved in making a dancer's body is so long and relentless, in many instances painful, the effort to maintain the technique so grueling that unless a certain satisfaction is derived from the disciplining and the punishing, the pace could not be maintained". -Agnes de Mille

The bodies of dancers, especially professional ballet dancers, are subjected to tremendous biomechanical stresses. This is undoubtedly why dancers have a high rate of injury. In a questionnaire study conducted by Bowling² et al. 84% of surveyed dancers reported experiencing an injury the significantly altered their ability to dance. The stresses and injuries dancers experience are numerous; daily activities such as extreme plantarflexion/dorsiflexion, repetition of movements, flexibility at the expense of stability and full body weight-bearing on the tips of the toes can all lead to injury.

Dancers are asked to be at their peak performance for multiple hours a day, seven days a week. The career of a dancer is not an easy one. It requires the dancer to be disciplined, determined and both mentally and physically sound. It is a profession that deserves great admiration and respect. Dancers are

asked to endure hostile environments for the betterment of their art. They are constantly subjected to cold, unforgiving studios, long grueling hours, and social pressures to remain thin. This in combination is a recipe for injury.

It has been demonstrated that there are excellent diagnostic modalities available in the field of dance medicine, including the use of X-ray, CT and MRI in the identification and treatment of lower extremity pathology; while the aim of this review was to discuss the common injuries in dancers, especially those whom dance en pointe, it is important to note that this discussion is by no means exhaustive. However, it is critically important that professional ballet dancers and physicians that treat these incredible athletes be knowledgeable about the serious stresses placed on the body of a dancer and the associated injuries they are likely to present with. Future research should center on preventative measures aimed at reducing the number of overuse injuries in dancers, with a focus on core strengthening measures. In truth, there are hundreds of possible injuries that dancers are predisposed to experiencing. However, what is most important and is part of the underlying purpose of this review is to quantify how important it is that dancers be educated of the importance that lies in the preservation of their bodies' health. The body is to the dancer what the instrument is to the

musician. Keeping the body fine-tuned and in harmony will allow a dancer to have a long, fruitful career. However, until dancers see this importance they will continue to destroy their bodies at the expense of their craft.

Acknowledgements

The authors would personally like to thank Gregory Taylor, PT and Randy Cohen, DPM for their help with acquisition of images for the review.

Statement of Competing Interest

AA and IS declare that they do not have any competing interests in relation to the work of this literature review.

Author's Contribution

AA and IS equally conceived the design of the literature review, reading of the literature material and in drafting and editing the manuscript for submission.

References

1. Albisetti W, Perugia D, Bartolomeo OD, Tagliabue L, Camerucci E, Calori GM. Stress fractures of the base of the metatarsal bones in young trainee ballet dancers. *International Orthopaedics SICOT* 34, 51-55, 2010.
2. Bowing A. Injuries to dancers: prevalence, treatment, and perception of causes. *Br Med J* 298, 731-733, 1989.
3. Cassas K, Cassettari-Wayns A. Childhood and Adolescent Sports-Related Overuse Injuries. Annual clinical focus on caring for children and adolescents 2006.
4. Elias I, Zoga AC, Raikin SM, et al. Bone stress injury of the ankle in professional ballet dancers seen on MRI. *BMC Musculoskeletal Disorders* 9:39, 2008.
5. Fong D, Chan YY, et al. Understanding acute ankle ligamentous sprain injury in sports. *Sports Medicine, Arthroscopy, Rehabilitation, Therapy & Technology* 1:14, 2009.
6. Grahame R, Jenkins JM. Joint hypermobility-asset or liability? A study of joint mobility in ballet dancers. *Ann. Rheum Dis* 31, 109-111, 1972.
7. Hillier JC, Peace K, Hulme A, Healy JC. MRI features of foot and ankle injuries in ballet dancers. *The British Journal of Radiology* 77, 532-537, 2004.
8. Kadel NJ. Foot and Ankle Injuries in Dance. *Phys Med Rehabil Clin N Am* 17, 813-826, 2006.
9. Kaufman BA, Warren MP, et al. Bone Density and Amenorrhea in Ballet Dancers Are Related to a Decreased Resting Metabolic Rate and Lower Leptin Levels. *The Journal of Clinical Endocrinology and Metabolism* 6:87, 2777-2783, 2002.
10. Klemp P, Learmonth ID. Hypermobility and injuries in a professional ballet company. *Br J Sports Med* 3:18, 143-148, 1984.
11. Noronha M, Refshauge KM, Herbert RD, Kilbreath SL. Do voluntary strength, proprioception, range of motion, or postural sway predict occurrence of lateral Ankle sprain? *Br J Sport Med*, 824-828, 2009.
12. Nussbaum AR, Treves ST, Micheli L. Bone Stress Lesions in Ballet Dancers: Sintigraphic Assessment. *Am Journal of Radiology* 150, 851-855, 1988.
13. O'Kane J, Kadel N. Anterior Impingement syndrome in dancers. *Curr Rev Musculoskeletal Med* 1, 12-16, 2008.
14. Russel J, Kruse D. Pathoanatomy of posterior Ankle Impingement in Ballet Dancers. *Clinical Anatomy* 23, 613-621, 2010.
15. Russell J, et al. Magnetic Resonance imaging of the ankle in female ballet "en pointe". *Acta Radiologica* 2010.
16. Schoene L. Biomechanical Evaluation of Dancers and Assessment of their risk of injury. *J Am Podiatr med Assoc* 1:97, 75-80, 2007.
17. Simpson MR, Howard TM. Tendinopathies of the Foot and Ankle. *American Family Physician* 10:80, 1107-1114, 2009.
18. Strong-Tytherleigh G, Baxandall R, Unwin A. Rupture of the ankle extensor retinaculum in a dancer. *Journal of the Royal Society of Medicine* 93, 638-639, 2000.
19. Weiss DS, Rist RA, Grossman G. When Can I Start Pointe Work? Guidelines for Initiating Pointe Training. *Journal of Dance Medicine and Science* 3:13, 90-92, 2009.
20. Wolfe MW, et al. Management of Ankle Sprains. *American Family Physician* 1:63, 93-104, 2001.

Short-Term Efficacy of Stretching in Conjunction with Other Conservative Treatments for Plantar Fasciitis

Kunal Amin, BS, Mina Hanna BA, Pooya Lashkari, BA, and Jalpen Patel, BS

Abstract

Introduction:

Plantar fasciitis is the most common cause of heel pain, affecting 10% of the general population. Plantar fasciitis is due to chronic inflammation to the fascia of the plantar foot. The overuse of the plantar fascia leads to inflammation at the site of its origin, the medial tubercle of the calcaneus. This literature review was written to observe the combination of stretching with an additional conservative treatment as an effective course of initial treatment.

Study Design:

Qualitative Systematic Review of the Literature

Methods:

The literature search was performed using PubMed as the electronic database. Various search terms were used individually and in combination for PubMed. The search terms included 'plantar fasciitis', 'plantar heel pain', 'stretching', 'orthosis' and 'short term treatment'. The inclusion criteria comprised of studies involving patients with plantar heel pain where stretching alone was compared to an alternative treatment combined with stretching.

Results:

All studies (4 RCTs and 1 Cohort) being investigated have demonstrated reduction of pain levels in patients who were treated with a combination of stretching and conservative methods.

Conclusions:

Conservative methods and stretching have shown to be effective in terms of initial treatment. Also, the combination of a conservative method with stretching has shown recovery times to be faster with decrease in pain levels. The studies reviewed in this paper focused more on short-term treatments, although long-term treatments are available.

Key Words: plantar fasciitis, plantar heel pain, stretching, orthosis, short-term treatment

Level of Evidence: 4



Introduction

Plantar fasciitis is the most common cause of heel pain, affecting 10% of the general population³. Although much has been published about this condition, little is known about the underlying disease process. Since heel pain is recognized as a feature of inflammatory rheumatic disease, it is more likely to have an inflammatory origin¹. The plantar fascia, also called plantar aponeurosis, is a thick fibrous connective tissue consisting of longitudinal fibers originating from the anterior aspect of calcaneal tubercle and terminating at the dorsal aspect of the proximal phalanges. The plantar fascia has 3 bands: medial, central and lateral, each separated by an intermuscular septum. The thickness of a normal plantar fascia is approximately 3 mm, but in patients with plantar fasciitis, the thickness can increase up to 7 mm⁵. The plantar fascia acts as a bowstring to maintain the longitudinal arch of the foot for support and acts as a shock absorber during gait. Plantar fasciitis is defined as exhibiting an inflammatory response, which is due to an overuse syndrome resulting in micro-tears of the

plantar fascia at its origin on the medial tubercle of the calcaneus. Patients with plantar fasciitis typically complain of "first step pain", which is pain during the first few steps after prolonged rest. The two most common underlying causes of plantar heel pain are believed to result from years of overuse and trauma⁶. Some risk factors include obesity and pregnancy as the greater weight puts increased strain on the fascia, which leads to chronic stretching and degenerative changes causing pain⁵. Most patients only seek treatment after having pain for weeks and it has been shown that longer duration of pain leads to worse prognosis¹.

Plantar fasciitis often responds to a wide range of conservative therapies. However, there is no single universally accepted way of treating this condition³. Stretching appears to be the simplest and most convenient technique to ease the symptoms by decreasing the pain. Unfortunately, it does not address the underlying pathology of poor foot biomechanics. In a way, stretching is a means of providing only temporary relief⁶. Currently, there are numerous approaches that use stretching in combination

with a variety of conservative methods that include anti-inflammatory drugs, myofascial trigger point manual therapy, and orthosis. Although stretching provides temporary relief, combining stretching with any of these conservative methods decreases pain in a shorter time period, allowing the patient to quickly regain physical function. This literature review focuses on the initial temporary relief given by conservative approaches with stretching. The compiled data show that stretching along with different conservative approaches were effective at reducing pain and improving biomechanical function in patients with plantar fasciitis.

Methods

The literature search was performed using PubMed as the electronic database. Limits were

applied to search for articles published between the years of 1995 to 2011. Various search terms were used individually and in combination for PubMed. The search terms included 'plantar fasciitis', 'plantar heel pain', 'stretching', 'orthosis' and 'short term treatment'. 301 titles and abstracts resulting from the searches were screened for inclusion criteria and quality, which resulted in the exclusion of 280 articles. The remaining 21 full-text articles were evaluated and 10 articles were selected based on eligibility. Included literatures satisfied one or more of the following criteria: randomized controlled trial, clinical trial, systematic review, published in English. The primary inclusion criteria was to include studies involving patients with plantar heel pain where stretching alone was compared to an alternative treatment combined with stretching.

Table 1: *Summary of General Study Characteristics*

	Radford et al.	Donley et al.	Renan-Ordine et al.	Drake et al.	Pfeffer et al.
Study Type	RCT	RCT	RCT	Cohort study	RCT
Recruitment	Newspaper advertisements	Did not mention	From physical therapy clinic	Fliers	Did not mention
Clinical Signs and Symptoms	Diagnosis of plantar heel pain	Increased heel pain with weight-bearing, 'first step' pain	Unilateral plantar heel pain, sharp pain under plantar heel surface upon weight-bearing	'First step' pain	Proximal plantar fasciitis, isolated pain over the medial calcaneal tuberosity
Total Sample Size and Sample Size for Each Group	N=92, 46 assigned to stretching & 46 assigned to control group	N=29, 12 assigned to treatment group & 17 assigned to placebo group	N=60, 30 assigned to treatment group and 30 assigned to control group	N=15, all were assigned to treatment group	N = 236, 190 assigned to treatment group & 46 assigned to control group
Randomization	Yes	Yes	Yes	No	Yes
Mean age ± SD (years)	Stretching group = 50.7 ± 11.8, Control group = 50.1 ± 11.0	Treatment group = 55 ± 10.2, Control group = 48.1 ± 10.7	Treatment group = 44 ± 11, Control group = 45 ± 10	37.6	Treatment group = 23 to 76 (range), control group = 25 to 81 (range)
Duration of Trial	2 weeks	6 months	1 month	12 weeks	12 weeks

Table 2: Summary of Interventions and Outcomes

	Outcome Measurement	Group	Baseline	Follow Up	Changes
Radford et al.	'First step' pain using Visual analog scale (0-100mm, 0 is no pain & 100 is worst pain)	Treatment	70.9 ± 23.0	51.1 ± 29.1	-19.8 ± 26.0
		Control	75.8 ± 19.1	62.5 ± 29.5	-13.2 ± 25.2
Radford et al.	Foot pain using Foot Health Status Questionnaire (0-100, 0 is worst & 100 is best foot health)	Treatment	34.0 ± 21.5	50.9 ± 23.1	16.9 ± 20.4
		Control	31.7 ± 17.8	50.8 ± 26.4	19.2 ± 21.6
Donley et al.	Average pain score (0-10, 0 is no pain & 10 is worst pain)	Treatment	7.48 ± 2.38	1.43 ± 1.51	6.05
		Control	6.71 ± 2.48	1.86 ± 2.48	4.96
Donley et al.	Average disability score (0-10, 0 is decreased disability & 10 is increased disability)	Treatment	6.12 ± 2.18	1.16 ± 1.22	4.96
		Control	5.30 ± 2.78	1.49 ± 2.46	3.81
Renan-Ordine et al.	Pressure Pain Threshold of Calcaneus (kg-cm ²) [minimal pressure when sensation of pressure changes to pain]	Treatment	2.3 ± 1.1	2.6 ± 0.9	0.3
		Control	1.7 ± 0.8	3.2 ± 1.3	1.5
Renan-Ordine et al.	Physical function using SF-36 questionnaire (0-100, 0 is lowest level of functioning & 100 is highest)	Treatment	44.3 ± 16.8	65.2 ± 12.2	20.9
		Control	41.2 ± 16.2	52.8 ± 19.4	11.6
Pfeffer et al.	Overall Pain Score derived from the Subscale for Pain of the Foot Function Index	Treatment	Data not provided	Data not provided	-23.3
		Control	55.8 ± 21.4	Data not provided	-15.8

Results

The final 10 articles, out of which 7 were clinical studies and 3 were systematic reviews, were assessed. A total of 432 participants, 137 males and 295 females, were included in this review. Of the 432 patients, 228 were assigned to stretching, either alone or along with other conservative treatment. The length of the trial in each study varied from 1 week⁶ to 6 months³. Six out of the seven clinical trials randomly allotted their subjects to control and treatment groups (2, 3, 6, 7, 8, 9).

In the study performed by Radford et al., the outcome was measured as 'first-step' pain on a scale of 0-100 with 0 being no pain and 100 being the worst pain. The pain in the treatment group decreased by 19.8 ± 26.0 as opposed to the pain in the control group decreased by 13.2 ± 25.2 . This study also measured foot health as an outcome on a scale of 0-100 with 0 being the worst and 100 being the best. The foot health in the treatment group and the control group improved by 16.9 ± 20.4 and 19.2 ± 21.6 respectively⁸.

The results from the RCT by Donley et al. were measured as average pain and disability scores, both on a scale of 0-10, with 0 being no pain/disability and 10 being the worst pain/disability. The treatment group in this trial had an improvement of 6.05 in their pain score, while the control group's pain score improved by 4.96. The disability level of the treatment group decreased by 4.96 and of the control group by 3.81³.

Renan-Ordine et al documented physical function as their outcome measurement. On a scale of 0-100, with 0 being the lowest and 100 being the highest level of functioning. The functioning enhanced in the treatment group by 20.9 and in the control group by 11.6⁹.

Pfeffer et al. recorded the outcome from their investigation as an overall pain score, where the treatment group's pain was reduced by 23.3 and the control group's pain was reduced by 15.8⁷. Further details can be found in table 1 and table 2.

Discussion

Patients diagnosed with plantar fasciitis have become an increasing complication. There are numerous interventions that physicians may consider. Even with all of the possible treatments, it is still controversial on what treatment is the best approach. Most professionals take the conservative approach initially and perform surgical interventions as a

last resort. When considering initial short-term treatments, the application of a physiotherapeutic treatment, such as stretching, has shown to be an effective intervention². Calf muscle stretching is used in patients with plantar fasciitis. There is usually no debate on the importance of stretching for patients with plantar fasciitis. However, the combination of stretching with another conservative approach as opposed to just stretching still needs to be investigated. The major focus of this article is to demonstrate the usefulness of various techniques when used along with stretching. The use of conservative treatments in conjunction with stretching has shown to be more of an effective approach in initial treatments for plantar fasciitis. NSAIDs, myofascial trigger point, and foot orthosis with stretching were studied.

NSAIDs with Stretching

In a particular study, an NSAID (celecoxib) was given to patients. Celecoxib selectively inhibits COX-2 and spares COX-1 activity. The outcome was measured in the context of improvement in pain and disability. The control group was given a placebo once a day for a month while the treatment group was given 200 mg of NSAID with the same daily regimen. Patients in both groups were kept on a conservative treatment regimen, which included heel-cord stretching, night splints, and heel cups. Assessments were made at 1 month, 2 months, and 6 months. Major improvement in pain and disability occurred at the final assessment. On average, all patients used night splints 3.6 nights /week and stretched 5.8 days /week. The data (refer to table 1) demonstrates that the treatment group's pain and disability scores improved from baseline to 6 months by a factor of 5.2 and 3.8, respectively, compared to 3.6 and 3.5 in the placebo group. Although the sample size was not sufficient to show statistical significance, it can be inferred from the data that the use of an NSAID may increase pain relief and decrease disability in patients with plantar fasciitis when used with a conservative treatment regimen³.

Myofascial Trigger Point with Stretching

Myofascial trigger point (TrP) is defined as areas associated within a tight band of muscle. After compression or stretching of these areas, patients may feel a referred pain distant to the TrP. For example, this referred pain can be plantar heel pain. The outcomes were measured at baseline and at a one-month follow up. They

measured the physical function and bodily pain domains of the quality of life (SF-36 questionnaire). They also used pressure pain thresholds (PPT). PPT is the point at which the sensation of pressure becomes pain. PPT was assessed over the affected gastrocnemii muscles, soleus muscle, and over the calcaneus. Patients receiving both self-stretching and TrP had greater improvement ($p < 0.01$) in physical function and pain reduction. There was also greater improvement in PPT in the combo group rather than stretching alone group ($p < 0.03$). The p -values allowed the study to conclude there was a statistical significance difference between the two groups. Due to limitations such as more contact with the clinician in the Trp group, some bias in the experiment had occurred. Also, since the same clinician evaluated the patients in both groups, the data may be difficult to reproduce by other clinicians. With these limitations, the study concluded that self-stretching + TrP had better short term improvement than stretching alone⁹.

Foot Orthosis with Stretching

Using the combination of temporary custom foot orthosis (TCFO) in conjunction with stretching is an efficient and affordable short-term treatment of plantar fasciitis. The use of a TCFO has been shown to reduce excessive pronation, improve mechanical loading, decrease pressure on the plantar fascia and provide arch support. TCFOs help transfer pressure from the heel to the forefoot by maintaining the foot in a plantarflexed and inverted position. The rigid material used to construct the orthosis stimulates mechanoreceptors to limit pronation, thus decreasing pressure on the plantar fascia. TCFOs also allow for healing and decreases further tearing of the fascia. TCFOs are simple to construct and cost less than \$14 per orthosis. After the application of a TCFO, the patients followed a stretching program of the plantar fascia, gastrocnemius, and soleus for 10 weeks. The stretching program allowed the plantar fascia to return to normal length and aided in the maintenance of the healing achieved by TCFOs⁴. In a particular randomized study, when comparing orthosis combined with stretching to stretching alone, there were higher statistical improvements found in the combination group in comparison to the stretching only group. This study shows tremendous improvement in the responses. The response was defined as “the

patient reporting that heel pain is all, much, or slightly better”⁷.

The clinical advantages of these conservative treatments are that they are relatively easy to perform and can be done in an outpatient setting. Patients who received conservative treatments with stretching showed reduction of pain and quicker recovery time. The advantage of such results may allow the patients to return to their daily activities at an earlier time. However, the studies in this review were limited when considering patient compliance and reviewing long-term studies. Based on the relative results, clinicians may have a personal preference as to which conservative treatment to use as long as stretching is used in combination.

Conclusion

All these conservative interventions with stretching demonstrated short-term relief from heel pain and allowed the patient to manage the condition more effectively. The combination of an additional conservative approach with stretching allowed patients to have notably greater reduction in pain levels as opposed to the control group (stretching only) in all the studies investigated. Future studies should focus on long-term treatments. Also, studies need to include other promising conservative approaches. For example, radial shockwave therapy has shown to be just as effective as stretching, but time, cost, and the use of instruments must be considered². So the goal of future studies should focus on time, cost, procedures, and the overall comfortableness of the patients undergoing the interventions. According to a study, calcaneal taping can prevent excessive pronation, a major risk factor of plantar fasciitis, thereby showing short-term relief of pain⁶. In conclusion, future research should involve RCTs with both short-term and long-term follow up.

Author's Contributions

JP contributed to the literature search, data extraction, analysis and writing of the manuscript. KA contributed to the literature search, data extraction, analysis and writing of the manuscript. MH contributed to the literature search, data extraction, analysis and writing of the manuscript. PL contributed to the literature search, data extraction, analysis and writing of the manuscript. All authors read and approved the final manuscript.

Statement of Competing Interest

The authors declare that they have no competing interests.

References

1. Atkins D, Crawford F, Edwards J, Lambert M. A systematic review of treatments for the painful heel. *Rheumatology*. 1999;38:968-973.
2. D'Andrea Greve JM, Grecco MV, Santos-Silva PR. Comparison of radial shockwaves and conventional physiotherapy for treating plantar fasciitis. *Clinics*. 2009;64(2):97-103.
3. Donley BG, Moore T, Sferra J, Gozdanovic J, Smith R. The efficacy of oral nonsteroidal anti-inflammatory medication (NSAID) in the treatment of plantar fasciitis: A randomized, prospective, placebo-controlled study. *Foot & Ankle International*. 2007;28(1):20-23.
4. Drake M, Bittenbender C, Boyles RE. The short-term effects of treating plantar fasciitis with a temporary custom foot orthosis and stretching. *Journal of Orthopaedic & Sports Physical Therapy*. 2011;41(4):221-231.
5. Healey K, Chen K. Plantar fasciitis: Current diagnostic modalities and treatments. *Clin Podiatr Med Surg*. 2010;27:369-380.
6. Hyland MR, Webber-Gaffney A, Cohen L, Lichtman SW. Randomized controlled trial of calcaneal taping, sham taping, and plantar fascia stretching for the short-term management of plantar heel pain. *J Orthop Sports Phys Ther*. 2006;36(6):364-371.
7. Pfeffer G, Bacchetti P, Deland J, et al. Comparison of custom and prefabricated orthoses in the initial treatment of proximal plantar fasciitis. *Foot & Ankle International*. 1999;20(4):214-221.
8. Radford JA, Landorf KB, Buchbinder R, Cook C. Effectiveness of calf muscle stretching for the short-term treatment of plantar heel pain: a randomised trial. *BMC Musculoskeletal Disorders*. 2007;8(36) [<http://www.biomedcentral.com/1471-2474/8/36>].
9. Renan-Ordine R, Albuquerque-Sendin F, Rodrigues De Souza DP, Cleland JA, Fernandez-De-Las-Penas C. Effectiveness of myofascial trigger point manual therapy combined with a self-stretching protocol for the management of plantar heel pain: A randomized controlled trial. *Journal of Orthopaedic & Sports Physical Therapy*. 2011;41(2):43-51.
10. Sweeting D, Parish B, Hooper L, Chester R. The effectiveness of manual stretching in the treatment of plantar heel pain: a systematic review. *Journal of Foot and Ankle Research*. 2011;4(19) [<http://www.jfootankleres.com/content/4/1/19>].

Investigations in the Use of Grafts for Treatment of the Chronic Diabetic Wound

Angel Colandrea, BS and Tammer Elmarsafi, MB BCH

Abstract

Introduction:

The purpose of this study is to investigate current concepts in advanced wound healing by reviewing the nature of the chronic diabetic wound, including its pathophysiology, treatment, and therapeutic outcomes utilizing current treatment modalities. The authors will review the importance for continued research in the field of chronic diabetic wounds, recognize the differences between the diabetic and non-diabetic patient, and demonstrate that these differences will shape the approach to future research and treatment of non-healing diabetic wounds.

Study Design:

Qualitative Systematic Review of the Literature

Methods:

Studies were carefully selected from searches conducted using PubMed from the origin of the databases to August 2011 and by hand-searching bibliographies of relevant articles. Articles involving research done on chronic non-diabetic wounds and/or venous ulcers were excluded from this review. Individual products were also researched by name.

Results:

The authors found that new technologies in advanced wound healing are becoming more successful with each new product hitting the market, however currently there is no one treatment that stands alone as the "gold standard" in advanced diabetic wound care.

Conclusions:

Previous studies have given researchers criteria to aim for in the development of new products that if met, will distinguish itself as the standard of care. Currently, a combination of available modalities is the best treatment to achieve optimal results and in the healing of chronic diabetic wounds.

Key Words: chronic diabetic foot ulcer OR wound, healing standard of care AND complication therapy, tissue engineer OR bioengineer skin, "advanced wound healing" human skin equivalent

Level of Evidence: 4

Introduction

Diabetes is a growing issue that affects 25.8 million people of all ages in the United States. In 2010 alone, about 1.9 million people ages 20 years or older were newly diagnosed with diabetes. Although not commonly thought of as fatal by the general population, diabetes is the seventh leading cause of death in the United States, and the leading cause of non-traumatic lower-limb amputations (more than 60% of all non-traumatic lower limb amputations).¹ Lower extremity ulcers proceed up to 85% of amputations in the diabetic population, and more than 15% of patients with a diabetic foot ulcer will eventually require an amputation.² Additionally, Tentolouris et al. found that approximately 60% of diabetic patients die within 5 years after their first amputation.³ For these reasons, it is apparent that the prevention and treatment of diabetic foot ulcers is crucial to improving length and quality of life in diabetic patients.

The skin is the body's first line of defense against potential pathogens, so it seems obvious to conclude that restoring an intact barrier over a chronic wound is the first step to prevent infection and initiate healing of an extensive wound, while also decreasing hospital stay and restoring function of the affected site. Routinely, autogenous skin taken from the patient's own body is the optimal treatment for sites of extensive skin loss, completely eliminating the risk for rejection of the donor graft while providing immediate availability; unfortunately, diabetic patients are anything but "routine." At the top of a long list of co-morbidities, impaired circulation, peripheral neuropathy, and cellular dysfunction are largely the main contributors to defective wound healing in the diabetic patient, all three of which are systemic problems that don't only occur at the wound itself, but also at potential donor sites. For these reasons, creation of an additional wound through the removal of skin from a donor site is a plan with obvious flaws.

Methods

Studies were identified by systematically searching PubMed and journals *Advances in Skin and Wound Care*, *Diabetes Care*, *Foot and Ankle International*, *Journal of the American Podiatric Medical Association*, and *Journal of Foot and Ankle Surgery* using Boolean search terms, from the origin of the databases to August 2011. Searches were conducted without language restriction. Bibliographies of all retrieved articles were also hand-searched for additional relevant references. Individual products were also searched in combination with the terms listed above. Exclusion criteria included studies done on non-healing wounds in patients who were non-diabetic (i.e. burn wounds, venous ulcers).

Results

A total of 14 journal articles were selected to be included in this review, as well as information from the US Department of Health and Human Services and lecture material presented by Dr. Eileen Scigliano during the Pathophysiology course at the New York College of Podiatric Medicine in November, 2010. The authors found that although there is not yet one true "gold standard" in treating the diabetic wound, by utilizing a combination of treatment modalities and maintaining patient compliance, healing is prolonged but possible. With time, the medical community makes progress in understanding the pathophysiology of the chronic diabetic wound and continues to improve its methods of treatment.

Discussion

Pathophysiology of the Diabetic Wound

Ulceration occurs primarily under the plantar surfaces of the toes, forefoot, and midfoot, followed by the dorsal surfaces of the toes and the heel, and is predominantly caused by repetitive and excessive pressure to skin leading to tissue damage.⁴ Ulceration of this kind rarely occurs in patients of good health, because the protective sensation of the body to feel pain under duress would prevent pressure from escalating to the point of ulceration. Unfortunately, in diabetics with peripheral sensory neuropathy, the protective sensation is diminished or lost completely and there is no warning to the body that these changes are even occurring. Autonomic neuropathy causes dryness to the skin by decreased sweating and leaves the skin vulnerable for breakdown.⁵ Neuropathy can also lead to a deformed foot,

and therefore altered gait pattern, which changes the distribution of plantar pressures during gait. Lack of proprioceptive feedback from the lower extremities leads to postural instability, altered foot anatomy, and disturbed coordination.⁶ Increased duration of pressure to an area (when the body is exposed to a manageable amount of pressure for an unmanageable amount of time), or increased magnitude of pressure (when a small area of skin is subject to a large force), leads to ischemia and cell death. Callus formation, although meant to be a protective measure against repetitive micro-trauma, leads to even higher pressures, altered loading of the foot, and ultimately ulceration; callused skin may even conceal underlying fully formed ulcers. Once the skin is broken, the barrier to the outside environment is now compromised and underlying tissues can be exposed to bacterial infection. Because most ulcers occur over bony prominences, bone is now also in danger of infection (osteomyelitis). When there is direct communication with bone, or when an ulcer overlies bone for a prolonged period of time, it can be assumed that osteomyelitis is present.⁷ Other risk factors for ulceration that can be attributed to diabetes are reduced vision, limited mobility, uremia, and previous ulceration.⁸

Physiology of Healing in Healthy Tissue

The body's response to an open wound is the ultimate Darwinian metaphor, priorities reorganized in order to preserve survival, regardless of cosmesis. Organization and aesthetics are sacrificed for the sake of damage control and accelerated return to function. Tasks of greatest importance are restoration of normal blood flow, lymphatic circulation, formation of a barrier against the outside, minimization of fluid loss, control of infection, elimination of pathogens, and establishment of some kind of architectural integrity.⁹ This cascade of events is the goal of the acute inflammatory response-the first phase of wound healing beginning immediately after initial tissue injury.

Breaks in blood vessel lining lead to exposure of subendothelial collagen and tissue factor to flowing blood. Exposed collagen then binds Von Willebrand factor, which in turn binds platelets via platelet surface receptor glycoprotein 1B. Bound platelets are now activated and release serotonin and thromboxane, which causes vascular constriction and platelet aggregation, respectively. Platelet surface receptor $\alpha_{IIb}\beta_3$ then

binds to fibrinogen, which forms the primary hemostatic plug causing cessation of bleeding and formation of a temporary barrier. Simultaneously, subendothelial tissue factor sets both the extrinsic and intrinsic coagulation cascades in motion to form a strong, cross-linked, fibrin polymer clot.¹⁰ Neutrophils and monocytes are part of the innate immune response and are first to arrive at the site of injury, led by the cascade of chemotactic factors. Neutrophils are present in larger numbers at first, and are important in tissue debridement and bacterial killing. Once the neutrophil has completed its task it undergoes apoptosis and is cleaned up by the macrophage, matured monocytes whose function is to phagocytose bacteria, scavenge tissue debris, and release growth factors. These growth factors are critical for the progression of wound healing by stimulating the migration and proliferation of fibroblasts that participate in the construction of the extracellular matrix.¹¹

Within 3-4 days, fewer inflammatory factors are secreted and numbers of neutrophils and macrophages are reduced at the wound site, indicating that the inflammatory phase is coming to a close and the proliferative phase can begin. Granulation tissue begins to replace the provisional matrix, and is a highly vascular and cellular connective tissue mixture of fibroblasts, endothelial cells, and macrophages that allow for a more permanent barrier. Granulation tissue formation involves fibroplasia (the accumulation of collagen and other matrix molecules) and angiogenesis (growth of new blood vessels) in order to supply the rapidly growing extracellular matrix with adequate nutrients.¹² Through rapid cell growth and death, transition from granulation tissue to mature scar tissue usually takes less than a week, as granulation tissue allows re-epithelialization to take place. Basal keratinocytes transform into a migratory phenotype, and migrate without proliferating across the wound site from the edges and meet in the middle, where they cease migration due to contact inhibition. As keratinocytes migrate across the wound bed, new epithelial cells are being formed and the wound edges contract. Once the wound is covered, keratinocytes revert back to their basal phenotype and reestablish anchorage into the basement membrane. Basal cells begin to divide and differentiate into normal tissue. The third phase of wound healing, the maturation and remodeling phase, includes increase in the tensile strength of the scar through deposition of collagen by myofibroblasts

and can last up to a year or more after the original insult.

Physiology of Non-Healing Wounds

The most important difference between healing and non-healing wounds is that non-healing wounds fail to transition from the first phase of healing to the next two. Wounds that become stunted in the inflammatory phase lack provisional matrix leaving the epithelium with no groundwork from which to grow on causing non-closure of the wound.

Persistence of the inflammatory stage is marked by the persistence of inflammatory cells—neutrophils and macrophages, driven by pro-inflammatory cytokines. Activated neutrophils and macrophages may secrete hydrolytic proteases (especially matrix metalloproteases) into the interstitium, which cause necrosis, tissue destruction, and degradation of growth factors and adhesion proteins, preventing cell adhesion for normal wound closure. The presence of poor arterial supply in diabetic patients leads to inadequate oxygenation and nutrition needed for wound closure, an essential component of the formation of healthy granulation tissue and epithelialization of the wound. The ischemic limb obscures treatment modalities, increases inflammation, and decreases infection clearance in the wound. The presence of necrotic tissue alone is enough to stall healing.

There also exists a delicate balance in which the healing of a wound must not be too dry nor overly moist. Draining ulcers cause peri-wound maceration, which if not treated can lead to expansion of the ulcer. Cells require optimal moisture to allow for migration of healthy tissue to close the ulcer. Moisture balance is therefore an important consideration. Failure to provide moisture can lead to eschar formation necessitating debridement.

The metabolic end products of the offensive organisms in an infected wound are often toxic to angiogenesis. Thus the spread of infection to the local non-ulcerated tissue can lead to expansion of the ulcer site. Polymorphonuclear lymphocytes respond to hypoxia by releasing proteinases and toxic oxygen metabolites, which damage endothelial cells and surrounding tissue leading to further stalling of wound healing.

Chronic diabetic ulcers most often form over bony prominences in the foot, due to the increased pressure and microtrauma. This only further decreases the ability of granulation tissue to form and healthy epithelium to grow over it.

Current Concepts in Advanced Wound Healing

Current treatments of diabetic ulcers include offloading of pressure at the wound site, such as using a Total Contact Cast (TCC), management of infection with antibiotics and sterile dressings, and debridement unwanted tissue at the wound site. These methods involve the removal of callus, necrotic tissue, and infected soft tissue or bone with the goal of converting a chronic wound to an acute wound that is once again capable of transitioning through the phases of wound healing without being halted in the inflammatory stage.¹³ Despite all of these treatments, however, the majority of ulcers do not heal, as found in a meta-analysis performed by Margolis et al. This study found that only 12% of ulcers healed after 12 weeks and only 31% of ulcers healed after 20 weeks using the methods described above.¹⁴ Although more conservative methods may eventually work, the longer a wound is allowed to be open, the higher the risk of acquiring a more limb or life-threatening bacterial infection in soft tissue or bone. Due to these stark outcomes scientists are currently looking for other ways to stimulate wound healing.

Skin is arguably the most important organ in preventing infection. Restoring its integrity is vital to patient recovery. Since chronic diabetic wounds have delayed (or complete lack of) migration of epidermal cells across the wound site, grafts have been introduced in-order to overcome this hurdle, close the wound, and facilitate healing. Skin grafting not only provides immediate coverage of the wound but has been shown to stimulate healing by re-vascularizing the wound bed.¹⁵ Although currently the clinical "gold standard," in treatment of full-thickness injuries is split-thickness autologous skin grafting,¹⁶ it requires harvesting epidermis with a superficial part of the dermis from an undamaged donor site. Besides the obvious creation of a new second wound that likely will not heal, there is no consistent evidence that the cells harvested are up to the monumental task of reviving the original wound site. In a 2001 study, Spravchikov et al. found that glucose not only affects the cell morphology of keratinocytes by making them larger, flatter, and mal-orientated, but that high glucose concentrations also inhibits keratinocyte proliferation and induces cell crisis.¹⁷ The keratinocytes located at the chronic diabetic wound site are no different than the keratinocytes that will be harvested at the diabetic donor site and are just as dysfunctional. Skin cells of the diabetic patient

are physiologically different and therefore a different approach must be taken to treat wounds in the diabetic patient.

Aside from autologous grafting, another possibility explored by physicians is the ability to grow human skin cells in-vitro from the patient's own cells. Although this abolished the need for a donor site and has the obvious advantage of donor availability, cells can take weeks to grow, time which leaves the patient extremely vulnerable and in acute danger of infection. Cadaveric allografts have also been taken into consideration as well, but once again, time is not on the diabetic patient's side as demand for cadaveric skin is quite high. In addition, most cadaveric skin grafts must be removed at a later date, so an additional graft would be needed and the patient would be required to go through a second surgical procedure carrying its own risks and complications. Cadaveric skin also poses the problem of donor rejection and transmission of disease; effective screening processes are impossible because some diseases may not yet be expressed at the time of graft harvest.¹⁸

Dermal replacements have been used, such as Dermagraft (Advanced Tissue Sciences Inc. La Jolla, CA), a bio-absorbable membrane impregnated with human dermal fibroblasts derived from neonatal foreskin. The fibroblasts are screened, enzymatically treated, and placed into a tissue culture. Allogenic dermal fibroblasts are the seeded onto a bio-absorbable polyglactin mesh, where the cells proliferate and produce dermal collagen, growth factors, GAGs, and fibronectin during a 2-3 week period. Dermagraft has been approved by the FDA for use in chronic wounds lasting longer than six weeks, but is contraindicated in wounds that involve tendon, muscle, joint capsule, or bone.¹⁹ Although, Dermagraft eliminates problems such as creating a second wound site and using defective cells from the host, it must be stored in dry ice at -70° Celsius and has a short shelf life unless cryopreserved (which can cause cells to lose viability and therefore therapeutic effect). Despite these limitations, Dermagraft proved that researchers were moving in the right direction, as shown by a prospective randomized clinical trial performed by Marston et. al., which studied the outcomes of 314 patients in 35 centers throughout the US with chronic diabetic wounds lasting greater than 6 weeks. Their research showed that 30% of patients treated with Dermagraft grafts fully healed in 12 weeks compared with 18.3% of

patients treated with conventional therapy, allowing researchers to conclude that Dermagraft is a safe and effective treatment for chronic diabetic foot ulcers. Although both groups experienced similar ulcer-related adverse events, the incidence of occurrence in patients treated with Dermagraft was significantly decreased.²⁰

Composite replacement grafts are bi-layered skin grafts consisting of both dermal and epidermal components. Apligraf (Graftskin, Organogenesis, Canton MA) is a bioengineered allogenic composite graft consisting of human epidermal cells, human fibroblasts, and type I bovine collagen. Apligraf simulates both the epidermis and dermis by featuring epidermal keratinocytes, a well-differentiated stratum corneum, an extracellular matrix, and viable allogenic dermal fibroblasts. The extracellular matrix composed of bovine type I collagen provides a scaffold for the healed wound.²¹ Apligraf looks and feels like human skin. Compared to human skin, Apligraf lacks blood vessels, sweat glands, and hair follicles in the dermis, and Langerhans' cells and melanocytes in the epidermis, but contains all cytokines present in human skin. It can self heal when injured and there has been no clinical evidence of rejection, sensitization, or immunogenicity.²² In 2001, a prospective, multicenter, randomized clinical trial was conducted by Veves et. al., which studied 208 patients in 24 centers across the US to assess the efficacy of treatment of chronic, diabetic wounds with Apligraf over 12 weeks, followed by a 3-month safety follow-up. After 4 weeks, 20% of patients who received Apligraf achieved wound healing compared to 3% in the control group (treated with saline-moistened gauze treatments, surgical debridement, and adequate foot off-loading); at 8 weeks, 45% of patients who had received Apligraf treatment achieved wound healing compared to 25% of the control group, and at 12 weeks, 56% of Apligraf-treated patients had achieved complete wound healing compared to 39% of the control group. The rate of adverse reactions was similar between the two groups with the exception of osteomyelitis and lower-limb amputations, both of which were less frequent in the group treated with Apligraf.²³ In addition, a European follow-up study to the clinical trial performed by Veves et. al., was performed and published in 2010, which demonstrated consistent superiority of Apligraf over control treated groups. Combining the results of the two studies, authors Steinberg et.

al., concluded that 55.2% of Apligraf treated patients had achieved complete healing by 12 weeks, compared to only 34.3% of control subjects.²⁴ Although the results speak for themselves, some disadvantages of Apligraf are that the graft can only be kept for 5-days at room temperature and once the sealed bag containing the graft is opened, application of the graft to the wound must occur within thirty minutes, and Apligraf is also contraindicated in wounds containing exposed tendon, capsule, or bone.²⁵

These conclusions from previous studies have allowed us to see the strengths and weaknesses in some of the current modalities in the treatment of chronic diabetic wounds, and lead the way for future research. From our research, we have concluded that the optimal graft material would be one that is not only immediately available but available in large quantities, is non-toxic, non-immunogenic, and prevents fluid and heat loss from the wound surface while providing a physical barrier against pathogens, able to support the reconstruction of normal tissue, is cost effective and convenient for use by surgeons, has a long shelf-life, and can be used in patients with full thickness ulcers that may have tendon, capsule, or bony involvement.²⁶

PriMatrix (TEI Biosciences Inc, Boston, MA), a dermal repair scaffold, may reach all of these standards. PriMatrix is an acellular dermal matrix composed of Types I and III collagen from fetal bovine dermis preserved in their native, non-denatured, non-damaged state without the use of artificial chemical cross-linking. PriMatrix is terminally sterilized via exposure to ethylene oxide gas, with a sterility assurance level of 10^{-6} with undetectable ethylene oxide residuals. It can be stored at room temperature for up to 3 years and is highly porous, supporting rapid rehydration in a sterile room-temperature saline immediately prior to implantation. In a retrospective comparison between PriMatrix and Apligraf completed by Dr. J. Karr, diabetic ulcers treated with PriMatrix had an average healing time of 37 days, while patients treated with Apligraf had an average healing time of 87 days. In addition, the average size of the wounds treated with PriMatrix were larger versus Apligraf, 10.2cm^2 to 6.4cm^2 , respectively. Both methods were shown to significantly improve healing time in chronic wounds.²⁷ The outcome of this study is especially promising, but further studies are needed to confirm these results, as this was an original investigation done by Dr. Karr.

Conclusion

Endless research efforts have been placed towards understanding the microenvironment of the unique tissue characteristics of diabetic ulcers. Overall, advancements in wound healing over the past decade have proven to be advantageous. With a greater understanding of the wound structure on a cellular and biochemical level, biologics have become an important tool for management of diabetic ulcers. This working knowledge has propagated the evolution of a multitude of products that aim to address those parameters. Nonetheless, diabetic ulcers prove to be a challenge to both patients and physicians. As we better understand the wound's peculiar nature, and as the technologies address more of these underlying particularities, even small improvements provide dramatic increases in a patients' well-being.

The complexity of the multivariable nature of diabetic wounds, in addition to the inherent complications of the diabetic patient, implore that optimal wound healing strategies must be employed to gain the greatest therapeutic advantage. The use of biologics alone, even when used with the best patient/product selection, can only address a small fraction of healing potentials. Careful manual and enzymatic approaches for wound debridement, judicious usage of antibiotic and antifungal therapeutics, use of human skin equivalents, and concomitant application of vacuum assisted wound closure are all paramount considerations for optimal results.

Neither a single treatment modality, nor any single protocol should be taken as the sole guideline for therapeutic alignment. Moreover, no two diabetic patients are the same. Therefore, the diligence of the practitioner in custom tailoring treatment should ultimately be the key towards success of diabetic wound's demise. The challenges of understanding the true biological nature of these chronic wounds is already complex and most studies attempt to clump the diabetic ulcer into one genre towards which this patient population is studied, missing the point that each patient, and thus each diabetic ulcer, is unique. It is important to highlight the importance of treating each ulcer, even when in the same limb, individually, to accomplish optimal results.

Author's Contributions

AC and TE conceived the design of the study and drafted the discussion. AC drafted the objective, abstract, introduction, methods, and results portions. TE drafted the conclusion.

Statement of Competing Interest

The authors have no conflict of interest to declare.

References

1. National Diabetes Statistics. US Department of Health and Human Services. National Institute of Diabetes and Digestive and Kidney Disorders; 2011. p. 1-11
2. Ramsey, SD; Newton, K; Blough, D; et al.: Incidence, outcomes, and cost of foot ulcers in patients with diabetes. *Diabetes Care*.1999 Mar; 22(3):382-7.
3. Tentouris, N; Al-Sabbagh, S; Walker, MG; et al.: Mortality in Diabetic and Nondiabetic Patients after Amputations performed from 1990 to 1995. *Diabetes Care*. 2004 Jul; 27(7): 1598-1604.
4. Van Schie, C; Boulton, J.M.; Biomechanics of the Diabetic Foot: the Road to Foot Ulceration, In A. Veves et. al. *The Diabetic Foot*, pp. 147-161; 2002, Humana Press Inc.
5. Vuorisalo, S.; et. al.: Treatment of Diabetic Foot Ulcers. *The Journal of Cardiovascular Surgery*. 2009 50(3): 275-91
6. Vuorisalo, S.; et. al.: Treatment of Diabetic Foot Ulcers. *The Journal of Cardiovascular Surgery*. 2009 50(3): 275-91
7. Pinzur, M.S.; Slovenkal, M.P.; et. al. Guidelines for Diabetic Foot Care: Recommendations Endorsed by the Diabetes Committee of the American Orthopaedic Foot and Ankle Society. *Foot and Ankle International* 2005 Jan 26(1):113-9.
8. Vuorisalo, S.; et. al.: Treatment of Diabetic Foot Ulcers. *The Journal of Cardiovascular Surgery*. 2009 50(3): 275-91
9. Davidson, J; DiPietro, L: The Wound Healing Process. In A. Veves et. al. *The Diabetic Foot*, Second Edition, pp. 59-82; 2006, Humana Press Inc.
10. Scigliano, E. (2010, November 17); Hemostasis, Lecture presented in Fundamentals of Pathophysiology course, New York College of Podiatric Medicine; New York, NY.
11. Falanga V: Physiology and Pathophysiology of Wound Healing, In A. Veves et. al. *The Diabetic Foot*, pp. 59-73; 2002, Humana Press Inc.
12. Davidson, J; DiPietro, L: The Wound Healing Process. In A. Veves et. al. *The Diabetic Foot*, Second Edition, pp. 59-82; 2006, Humana Press Inc.
13. Wukich, D.K.; Current Concepts Review: Diabetic Foot Ulcers. *Foot and Ankle International*, 2010 May; 31(5): 460-7.
14. Margolis, D.J.; Berlin, J.A.: Healing of diabetic neuropathic foot ulcers receiving standard treatment: a meta-analysis. *Diabetes Care* 1999; 22(5): 692-695
15. Dinh, T.; Veves, A.; Living Skin Equivalents for the Diabetic Foot Ulcer. In A. Veves et. al. *The Diabetic Foot*, Second Edition, pp. 459-70; 2006, Humana Press Inc.

16. Shevchenko, R.V. et al.: A review of tissue-engineered skin bioconstructs available for reconstruction, *Journal of the Royal Society Interface*, 2010, 7:229-258
17. Spravchikov, N.; Sizyakov, G. et. al.: Glucose Effects on Skin Keratinocytes Implications for Diabetes Skin Complications. *Diabetes* 2001 July, 50(7): 1627-35.
18. Dinh, T.; Veves, A.; Living Skin Equivalents for the Diabetic Foot Ulcer. In A. Veves et. al. *The Diabetic Foot*, Second Edition, pp. 459-70; 2006, Humana Press Inc.
19. Fan, K.; Tang, J.; et. al.: State of the Art in Topical Wound-Healing Products, *Journal of Plastic and Reconstructive Surgery*, 2011, Jan. 127 (1S), 44S-59S
20. Marston, W.A.; et al.: The Efficacy and Safety of Dermagraft in Improving the Healing of Chronic Diabetic Foot Ulcers. *Diabetes Care* 2003 June 26(6): 1701-5
21. Dinh, T.; Veves, A.; Living Skin Equivalents for the Diabetic Foot Ulcer. In A. Veves et. al. *The Diabetic Foot*, Second Edition, pp. 459-70; 2006, Humana Press Inc.
22. Fan, K.; Tang, J.; et. al.: State of the Art in Topical Wound-Healing Products, *Journal of Plastic and Reconstructive Surgery*, 2011, Jan. 127 (1S), 44S-59S
23. Veves, A. et. al.: Graftskin, a Human skin Equivalent, Is Effective in the Management of Noninfected Neuropathic Diabetic Foot Ulcers A prospective
24. Steinberg, J.S.; et. al.: Confirmatory Data from EU Study Supports Apligraf for the Treatment of Neuropathic Diabetic Foot Ulcers, *Journal of the American Podiatric Medical Association* 2010 Jan/Feb 100(1):73-77
25. Bello, Y.M.; et. al.: Tissue-Engineered Skin Current Status in Wound Healin. *American Journal of Clinical Dermatology* 2001; 2(5): 305-13
26. Shevchenko, R.V. et al.: A review of tissue-engineered skin bioconstructs available for reconstruction, *Journal of the Royal Society Interface*, 2010, 7:229-258
27. Karr, J.C.: Retrospective Comparison of Diabetic Foot Ulcer and Venous Stasis Ulcer Healing Outcome between a Dermal Repair Scaffold (PriMatrix) and a Bilayered Living Cell Therapy (Apligraf). *Advances in Skin and Wound Care*, 2011 March 24(3): 119-25.

All opinions and statements presented in this issue of NYCPM's *Podiatric Medical Review* are the sole expressions of the authors.

The Editor-in-Chief reserves the right to edit for grammar and formatting, as deemed necessary. The Editor-in-Chief has the right to reject or defer any submitted manuscripts.

Please direct questions and comments to:

Adisa Mujkic, Editor-in-Chief
amujkic@nycpm.edu

