



**Barefoot Running:  
Defining The Risks &  
Benefits**

---

<b>Plantar Calluses Leading to Subsequent Plantar Ulcerations in the Neuropathic Diabetic Foot</b> Prema Hampapur, BS and Aarti Kumar, BS	4
<b>Defining Barefoot Running: Recognizing the Risks and Benefits: A Systematic Review</b> Amanda Maloney, BA, and Sameep Chandrani, MBS	10
<b>Literature Review of the Surgical Methods of Late-Stage Freiberg's Disease: Diagnosis and Treatment</b> HaeKang Yang, BS, Joseph Park, BA, Innjae Park, MBS	15
<b>Common Injuries in Contact Sports: A Systematic Review</b> Sameep Chandrani, MBS, and Timothy Miller, BA	22
<b>Methylglyoxal and Osteoprotegerin Down-regulation in Patients with Uncontrolled Diabetes Mellitus: A Possible Microvascular Therapeutic Approach to Diminish Lower Extremity Amputations</b> James Adrian Wright, AM, and Virginia Parks, BS	29
<b>Relapsing Polychondritis with Pedal Manifestations: A Case Report</b> Danielle Mercado, BS, and Chelsea Viola, BS	35

---

# Members of the Editorial Board

*NYCPM Podiatric Medical Review 2012-2013*

## Editor-in-Chief Editor

Jonathan Roy, MS  
J. Adrian Wright, AM

## Faculty Advisors

Anthony Iorio, DPM

## Student Reviewers

Sameep Chandrani, MBS  
Michael Gazes, MPH  
Amanda Maloney, BA  
Timothy Miller, BA  
Virginia Parks, BS  
Cailin Rubino, BS  
J. Adrian Wright, AM

## Clinician Reviewers

Anthony D'Antoni, DC, PhD  
Johanna Godoy, DPM  
Kristina Karlic, DPM  
Khurram Khan, DPM  
Jose Loor, DPM  
Giannin Perez, DPM  
Barbara Resseque, DPM  
Susan Rice, DPM  
Thomas Vitale, DPM

### Peer Review

The incorporation of peer review into this publication of NYCPM's *Podiatric Medical Review* has been the cornerstone of ensuring that manuscripts were held to the highest standards. Peer review was conducted with the aim of enhancing the quality of each manuscript, and gave students the opportunity to engage in the peer review process, which included a review by a third-year student and, a clinician. Some reviews required additional input from basic scientists. Manuscripts were systematically reviewed for format, content, appropriateness for the scope of the journal, and overall quality.

Authors were given the opportunity to revise their original manuscripts based on reviewer comments and suggestions that were submitted to the Editor-in-Chief. Authors were asked to grade their manuscripts according to CEBM's *2011 Levels of Evidence*.<sup>1</sup> Upon revision, the Editor-in-Chief assessed all manuscripts for final publication.

1. Jeremy Howick. "The Oxford 2011 Levels of Evidence". Oxford Centre for Evidence-Based Medicine.  
<http://www.cebm.net/index.aspx?o=5653>

## Letter from the Editor-in-Chief

---



Dear Fellow Students and Future Colleagues,

It was only two years ago when the wheels began to turn for the possible revival of the journal after a decade in hiatus. Thanks to the resilient efforts of the previous editor in chief, Adisa Mujkic, along with co-editors and faculty, the rebirth of the *Podiatric Medical Review* journal was possible. Since then, students have been able to publish their research in the student-organized, peer-reviewed medical journal while learning from the published literature of others.

Now, as the editor-in-chief of this journal, I would like to share with you what drew me to this publication. My interest in the journal grew primarily as an author who wanted to publish research that I was interested in along with my colleagues. I was fortunate to also be selected as the only junior co-editor for the journal at the time, and work along with the rest of the team. After seeing the final product, I was thrilled to be promoted as the next editor-in-chief and to continue the journey onwards. I am thankful for the confidence placed in me by our former editor-in-chief as well as the rest of our team.

Looking forward, the journal continues to provide students with the opportunity to engage in and read up on the latest research, which undoubtedly impacts the state of our field. The peer review process will remain a fixture of the journal, as we aim to provide a publication that prides itself on its accuracy and thoroughness. Such a goal could not possibly be met without the indispensable help and guidance that I have received from all the clinicians involved in shaping the journal. A special thank you to Dr. D'Antoni and Dr. Iorio, whom I am extremely grateful to receive guidance from. A fantastic job to Linda Chusuei and Adrian Wright for helping to design the journal and making sure it is sophisticated, professional, and representative of our worthy school.

I would especially like to express my gratitude to my esteemed co-editors Adrian, Cailin, Micheal, Sameep, Tim, Virginia and Amanda for all their fine work. Last but not least, I must thank the student authors for their diligence and dedication to performing research amidst their busy academic schedules. Without their efforts, none of this would be possible. I thank you for being patient while the finalization of the journal took place, and I hope the outcome exceeds expectations.

Sincerely,  
Jonathan R. Roy  
Editor-in-Chief

# Plantar Calluses Leading to Subsequent Plantar Ulcerations in the Neuropathic Diabetic Foot

Prema Hampapur, BS and Aarti Kumar, BS

## Abstract

### Introduction

An analysis of various studies discussing the risk of developing a plantar ulcer from a plantar callus in diabetic patients was performed. By knowing the risk and statistics of such a correlation, it may be possible to prevent ulcerations in the population most at danger by initiating podiatric treatment earlier on in the process and saving patients from life-changing amputations. The effects of callus removal will be discussed in relation to a decrease in plantar pressure.

### Study design

Qualitative systemic review of the literature

### Methods

Using PubMed and Google Scholar, all types of study designs and publication years were included in the search. The MeSH terms “callus formation” AND “diabetic foot ulceration” keyword combinations were used in PubMed to find the most relevant data with AND being used as the exclusion operator. The search topic “formation of callus leading to diabetic foot ulceration” was entered in Google Scholar to obtain further data. Search limits were set to include only full text articles in English. Articles were excluded based on their irrelevance as determined by their abstracts.

### Results

Our study revealed that a great amount of evidence and statistics were available testifying to a significant relationship between a plantar callus developing into a plantar ulcer in the diabetic foot most notably in the presence of neuropathy.

### Conclusion

This study concludes that there are various causes to increased plantar pressure—the major cause being the existence of a plantar callus in combination with a lack of sensation in a neuropathic diabetic patient. This is due to the danger and unawareness of the impending tissue breakdown of a hyperkeratotic lesion. It is the combination of insensitivity secondary to diabetic neuropathy and plantar calluses that result in ulceration. Clinicians can help reduce high foot pressures before they develop into ulcers and reduce amputations.

**Key Words:** Calluses, ulcerations, diabetic neuropathy

**Level of Evidence:** 4

### Introduction

Diabetes mellitus is a common condition affecting patients both in the developed and developing nations across the globe. Complications affecting the lower limb are among the most common manifestations of diabetes, and those precipitated by neuropathy include ulceration, infection and even

amputation.<sup>1</sup> Peripheral neuropathy is considered a major risk factor for the pathophysiology of foot ulceration due to loss of protective pain sensation. However, there is a strong correlation between the presence of callosities and their impact on plantar pressure and ulcer formation.



The physiological process responsible for the formation of hyperkeratotic lesions is thought to be a result of repetitive friction or pressure in which normal healthy skin undergoes accelerated keratinization, or hyperkeratosis, along with a lower rate of desquamation causing a thickening of the stratum corneum. In the absence of pain, hyperkeratinization results in a breakdown of skin and tissue integrity. Neuropathic diabetic patients in the absence of pain, have no warning of impending tissue breakdown—ulceration.<sup>2</sup>

The formation of plantar ulcers involves various components such as neuropathy, biomechanical pressure and vascular supply. Neuropathy can be further divided into sensory, motor and autonomic, with each category contributing to the breakdown of the plantar skin leading to the formation of a plantar ulcer. There are various treatment options for the care of plantar ulcers. Monitoring blood glucose levels and screening for peripheral neuropathy in the diabetic patient, off-loading the diabetic foot with casting, and wound debridement are common practices in treating plantar ulcers.<sup>3</sup> (Cleveland Clinic)

The purpose of this review article is to assess the relationship between a plantar callus and increased plantar pressure resulting in a subsequent plantar ulcer in a diabetic patient. The removal of a callus in a high-risk patient and prevention of plantar ulceration in diabetic neuropathic patients will also be discussed.

## Methods

The researchers conducted independent online database searches of PubMed and Google Scholar for references. The MeSH terms “callus formation” AND “diabetic foot ulceration” keyword combinations were used in PubMed to find the most relevant data. The search topic “formation of callus leading to diabetic foot ulceration” was entered in Google Scholar to obtain further data.

Studies obtained and reviewed were not limited to publications solely in the United States; however, only studies written in English were analyzed. Limits were applied to search for articles published between the years of 1992 to 2012. Our inclusion criteria were all retrospective, prospective, cohort studies, randomized controlled trial and case reports consisting of diabetic patients with calluses in both genders. The exclusion criteria consisted of articles that did not correlate plantar ulceration to plantar calluses in the diabetic foot in the preliminary search. Twenty-five articles were found on PubMed in relation to our search criteria and three articles were chosen for elaboration and discussion. 2,560 search results appeared in Google Scholar, from which three articles were chosen. The primary inclusion criterion was to include studies involving neuropathic diabetic patients with plantar calluses where plantar ulcers developed.

This literature review was a compilation of previous studies and thus did not require further Institutional Review Board (IRB) approval.

## Results

A prospective study was conducted by Murray et al to assess the presence of a callus and its ability to predict the formation of a plantar intrinsic neuropathic diabetic foot ulcer. Sixty-three participated in the study (median age being 62 years with a median diabetes duration of 17 years). All the participants reported to have had neuropathy and elevated peak plantar foot pressures greater than 10 kg cm<sup>-2</sup>. Throughout the study, seven ulcers occurred in six patients. Pressures were higher in the ulcer than non-ulcer study subgroup ( $p= 0.04$ ) with a relative risk of developing an ulcer of 4.7 for an area of elevated plantar pressure. This compared with a relative risk of 11.0 for an ulcer developing under an area of callus.<sup>3</sup> Additionally, according to Murray et al, the presence of a callus was highly predictive of a subsequent ulceration supported by a  $p$  value of 0.004 (Table 1).

Table 1: Incidence of Intrinsic Ulcers during the Study Period

		Incidence	<i>p</i>	RR (95% CI)
Previous history of intrinsic ulcers	No	3/1108 (0.3%)	0.00001	56.8 (13.4, 241.2)
	Yes	4/26 (15.4%)		
Baseline callus	No	3/1011 (0.3%)	0.004	11.0 (2.8, 43.2)
	Yes	4/123 (3.3%)		
Baseline pressure	< 10 kg cm <sup>-2</sup>	3/886 (0.3%)	0.04	4.7 (1.2, 18.9)
	> 10 kg cm <sup>-2</sup>	4/248 (1.6%)		

In a prospective study done by Veves et al, a series of 86 diabetic patients were studied in which the mean age was 53.3 and the average duration of diabetes was 17.1 years. The patients were followed up for a mean period of 30 months. During baseline examination, clinical neuropathy was present in 58 (67%) of the patient population. Plantar foot ulcers developed in 15 patients (17%)—all of whom had abnormally high pressures at baseline. Notably, out of those 15 patients with high pressures developing ulcers, 14 patients had neuropathy at baseline. Plantar ulceration occurred in 35% of diabetic patients with high foot pressures but in none of those with normal pressures.<sup>4</sup> This study depicted for the first time in a prospective study that high plantar foot pressures in diabetic patients are strongly predictive of subsequent plantar ulceration, especially in patients

presenting with neuropathy (Table 2).

In a prospective multicenter trial carried out by Pham et al, patients who developed foot ulcers had significantly higher foot pressures (>6/kg/cm<sup>2</sup>) as compared to nonulcerated patients.<sup>5</sup>

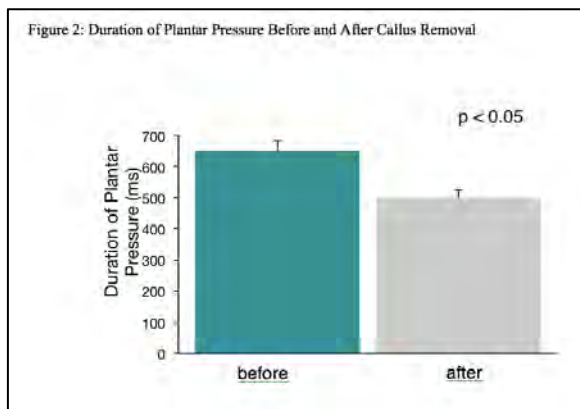
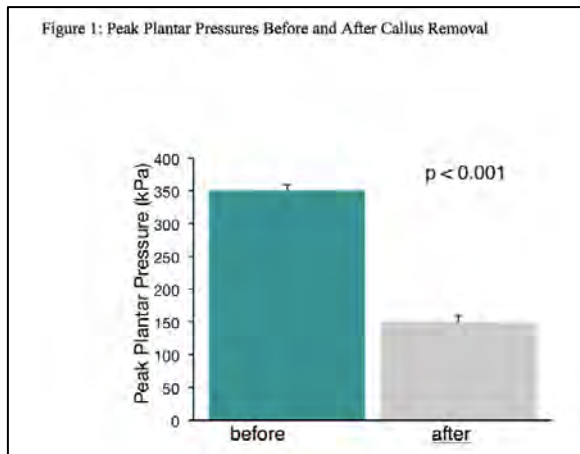
In addition to studying the relationship between plantar calluses, plantar pressures and plantar ulcer formation, Pataky et al further investigated the effects of callus removal in the diabetic patient. The study divided 33 type 2 diabetic patients into 3 groups: Group A consisted of 10 subjects with calluses, Group B consisted of 10 subjects without calluses and Group C consisted of 13 subjects with calluses which were subject to removal. Pataky et al found that subjects in Group C experienced a 58% decrease in peak plantar pressures after callus removal (*p* < 0.001) (Figure 1) as well as a decrease in the

Table 2: Results of Foot Pressure Measurements and Plantar Keratosis

	Diabetic patients ( <i>n</i> = 86)	Neuropathic subgroup ( <i>n</i> =58)	Non-neuropathic subgroup ( <i>n</i> =28)
Baseline peak foot pressure (mean +/- SD, kg . cm <sup>-2</sup> )	11.2 +/- 5.4	12.2 +/- 5.8	9.0 +/- 3.9
Follow-up peak foot pressure	13.5 +/- 7.1	14.8 +/- 7.3	10.9 +/- 5.6
No. of patients with high foot pressures at baseline	43 (50%)	31 (53%)	12 (43%)
No. of patients with plantar ulceration and high pressures at baseline	15 (35%)	14 (45%)	1 (8%)

duration of plantar pressure by 150 milliseconds per step ( $p < 0.05$ ) (Figure 2).<sup>2</sup>

A study by Young et al. also examined the effects of callus removal on plantar pressures. Seventeen diabetic subjects with 43 forefoot plantar callosities were observed. Patients ranged in age from 39 to 88. Measurements of plantar pressures were taken before and after callus removal with the dynamic optical pedobarograph system. Findings revealed a 26% reduction in plantar pressures in areas of callus removal from  $14.2 \pm 1.0$  to  $10.3 \pm 0.9$  kg cm<sup>-2</sup> ( $p < 0.001$ ) (Figure 3). Reductions were found in 37 of the 43 callus sites. Reduction in plantar pressure was observed in all subjects. Average heel pressures, which ranged  $4.9 \pm 0.6$  from  $5.0 \pm 0.6$  kg cm<sup>-2</sup>, were used as controls for variations of gait.<sup>6</sup>



Pitei et al found a decrease in plantar pressures after callus removal. The study looked at subjects with diabetes and neuropathy. Subjects were divided into three groups: Group 0 included

individuals with first time callus and no history of ulceration. Group A included 10 subjects with a history of ulceration and podiatry treatment every 6-8 weeks. Group B included 8 subjects with a history of ulceration and podiatry treatment every 3-4 weeks. Measurements of plantar pressures using the F-SCAN system were taken before and after callus removal. Results showed that the peak pressure was lowered by  $30.9 \pm 4.5\%$  ( $p < 0.005$ ) in Group A whereas subjects in Group B showed plantar pressures decreased at a lesser degree of  $24.8 \pm 4.0\%$  ( $p = 0.005$ ).<sup>7</sup>

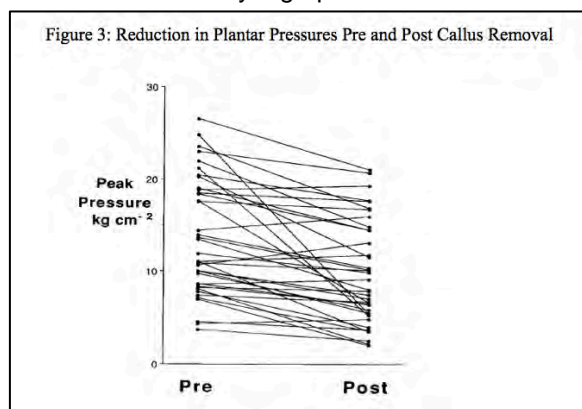
## Discussion

Various studies have confirmed that a previous ulceration is the major risk factor for a development of a subsequent ulcer. However, a prospective study carried out by Murray et al was the first to depict that the presence of a plantar callus was highly predictive of a subsequent ulceration. According to Murray et al, careful history taking and examination of the foot to detect the presence of callus require no special training or equipment and it should be recognized as a "high risk" for foot ulceration. Other risk factors for ulceration included previous ulceration, neuropathy, vascular disease, elevated foot pressures and limited joint mobility.<sup>3</sup> The study states that the relative risk (RR) for a patient with a callus to develop an ulcer is 11.0 while that of an elevated plantar pressure presents with a much lower RR of 4.8. Although the RR for a patient with a previous history of an ulcer is much higher at 56.8, it should be noted that a callus presents with a significant risk and the presence of a callus has been shown by this study to be a significant marker for the development of foot ulceration.<sup>3</sup>

The presence of a callus is easily detected by the patient and can lead to prevention of ulceration if treatment is early on in the process. According to Murray et al, if all patients with neuropathy and calluses are considered to be at risk for ulceration when their feet are examined and are given appropriate education, footwear and podiatric treatment is possible to decrease the incidence of primary plantar foot ulceration considerably, ensuring a better prognosis for the

patient and a decrease of inpatient hospital costs.

Two main risk factors for ulcer formation have been found to be neuropathy in a diabetic patient along with limited joint mobility. According to Veves et al, previous studies have shown that foot ulcers are found at sites with high pressures, but that in the absence of neuropathy, high pressures alone do not lead to ulceration. In their prospective study, Veves et al found that 15 out of 43 (35%) patients with high pressures developed subsequent plantar ulcers. When the diabetic group was subdivided into neuropathic and non-neuropathic subgroups, 14 out of 31 (45%) neuropathic patients and 1 out of 12 (8%) non-neuropathic patients with abnormally high pressures developed plantar ulcers (Table 2).<sup>4</sup> No ulcer formation resulted in patients with normal pressures. The researchers stated that it is the combination of high plantar pressure and insensitivity in neuropathic diabetic feet that cause subsequent ulcer formation. Veves et al clearly points out the etiology of high plantar pressures in the neuropathic diabetic foot in stating that the main contributory factors are sensory and motor dysfunction together with limited joint mobility. The lack of proprioception with an imbalance between the long flexors and extensors of the toes is thought to lead to the characteristic at-risk foot with claw toes and prominent metatarsal heads.<sup>4</sup> In addition to sensory incapacitance, limited joint mobility at the subtalar and metatarsophalangeal joints cause an abnormally high pressure and load.



Measurement of plantar pressures in patients has proven to be useful in assessing podiatric treatment in the diabetic foot. According to

Pataky et al, it is recommended that calluses be removed every 3-4 weeks because the epidermis has a faster rate of cell division in areas of callosities. In addition the stratum corneum has a longer renewal time in calluses. A drawback to this study is that subjects with neuropathy and PVD were not included and conclusive evidence was not recorded in regards to frequency of callus removal in these individuals. The authors, however, suggest that diabetic patients with neuropathy and PVD are recommended to seek podiatric care to remove calluses more frequently. The increase in plantar pressures in areas of callosities in all three studies reviewed have supported that diabetic patients with calluses seek podiatric treatment to remove them and thus lower plantar pressures. Young et al. confirmed the increase of plantar pressures in areas of callosities and the importance of removal. The study further suggests that the increase in plantar pressures may contribute to ulcer formation. The removal of calluses may aid in preventing plantar ulcers in the diabetic patient.

### Conclusion

The increasing incidence of diabetes mellitus has many ramifications which lead to the development of other health issues. The foot in the diabetic patient is prone to various injuries that can be detrimental to the patient. Plantar ulcers are a common complication diabetic individuals develop if proper podiatric medical care is not provided. Ulcers forming on the foot have grave consequences if not treated. Infections can result after ulcer formation and thus can lead to necrosis.<sup>8</sup> According to Reiber et al, 85% of nontraumatic lower extremity amputations have resulted after the formation of ulcers in people with diabetes.<sup>9</sup> After reviewing various studies, findings conclude that plantar calluses are more prone to developing in areas of higher plantar pressures, thus leading to plantar ulcers in the diabetic patient. Murray et al specifically examined the relationship of plantar calluses and plantar ulcers and concluded the formation of plantar ulcers had a higher probability of developing under plantar calluses. Veves et al labeled high plantar pressures in patients suffering from peripheral neuropathy as one of the major risk factors of plantar ulcers.



Plantar pressures are solely not responsible for the formation of ulcers. The loss of sensation in the foot aids in formation of ulcerations in diabetic patients. In addition, various studies have also supported that the removal of calluses in diabetic patients has resulted in lower plantar pressures and subsequent plantar ulcers.

Prevention of plantar ulcers is a significant factor in maintaining the health of diabetic individuals. After reviewing literature, it is clear that measuring plantar pressures, removing plantar ulcers and monitoring peripheral neuropathy are crucial steps in preventing the formation of plantar ulcers. In a literature review examining various ways of preventing plantar ulcers, Singh et al emphasized the importance of screening. Though there is no specific level defined for plantar pressures, screening plantar pressures in diabetic patients is suggested in preventing ulcer formation. Orthotics and other custom-made footwear were a method of maintaining plantar pressures.<sup>10</sup> Orthotics help in spreading pressures over a greater surface area, thus inhibiting pressures to increase in one area. More studies are required to fully support the prescription of specialized footwear for diabetic patients. Singh et al suggest the debridement of calluses as another method of lowering plantar pressures and also inhibiting ulcer formation in diabetic patients. They found that by removing plantar hyperkeratotic lesions, plantar pressures were reduced by 26%.<sup>10</sup> Pitei et al examined the change in plantar pressures before and after callus removal and suggested patients seek podiatric medical care every 3-4 weeks to debride plantar calluses for optimal results.<sup>7</sup>

The pathophysiology of the foot in the diabetic patient becomes more complicated with the formation of ulcers. Preventing the formation of ulcers by closely monitoring diabetic patients, especially those with peripheral neuropathy, can contribute to individuals leading a longer and happier life. Continual podiatric medical care is crucial in screening for various contributing factors such as increased plantar pressures, and treating the symptoms if they arise. Maintaining the health of the diabetic patient requires constant foot care and management.

### Author's Contributions

Both PH and AK jointly conducted literature searches to obtain articles that satisfied the review's criteria. AK created the data tables that classified the incidence of intrinsic ulcers and the pressure measurements along with plantar ulceration. PH created figures demonstrating plantar pressures and their duration both before and after callus removal. PH and AK jointly wrote the rest of the paper and contributed their ideas to the discussion and conclusion sections. Both authors read and approved the final manuscript.

### Statement of Competing Interests

The authors declare that they have no competing interests.

### References

1. Abquaesha F, Van Schie C H.M., Griffiths G, Young R, Boulton A. Plantar Tissue Thickness is Related to Peak Plantar Pressure in the High-Risk Diabetic Foot. *Diabetes Care* 24: 1270-1274, July 2001
2. Pataky Z, Golay A, Faravel L, Da Silva J, Makoundou V, Peter-Riesch B, Assal JP. The Impact of Callosities on the Magnitude and Duration of Plantar Pressure in Patients with Diabetes Mellitus. *Diabetes Metab (Paris)* 28: 356-361, 2002
3. Boike A, Maier M, Logan D. Prevention and Treatment of Leg and Foot Ulcers in Diabetes Mellitus. Cleveland Clinic publication: Diabetes Management Project. August 2010
4. Murray HJ., Young MJ., Hollis S, Boulton AJM. The Association between Callus Formation, High Pressures and Neuropathy in Diabetic Foot Ulceration. *Diabetic Medicine* 13: 979-982, 1996
5. Veves A, Murray HJ, Young MJ, Boulton AJM. The Risk of Foot Ulceration in Diabetic Patients with High Foot Pressures: A Prospective Study. *Diabetologia* 35: 660-663, 1992
6. Pham H, Armstrong D, Harvey C, Harkless L, Giurini J, Veves A. Screening Techniques to Identify People at High Risk for Diabetic Foot Ulceration. *Diabetes Care* 23: 606-611, 2000
7. Young MJ, Cavanagh PR, Thomas G, Johnson MM, Murray H, Boulton AJ. The effect of callus removal on dynamic plantar foot pressures in diabetic patients. *Diabet Med.* 1992 Jan-Feb;9(1):55-7.
8. Pitei DL, Foster A, Edmonds M. The effect of regular callus removal on foot pressures. *J Foot Ankle Surg.* 1999;38:251-255
9. Edmonds M. Diabetic Foot Ulcers: Practical Treatment Recommendations. *Drugs: 2006 - Volume 66 - Issue 7 - pp 913-929*
10. Reiber G, Boyko E, Smith D. Chapter 18: Lower Extremity Foot Ulcers and Amputations in Diabetes. *Diabetes in America*. DIANE Publishing, Jul 1, 1995; 782 pages
11. Singh N, Armstrong D, Lipsky B. Preventing Foot Ulcers in Patients With Diabetes. *JAMA.* 2005;293(2):217-228.

# Defining Barefoot Running: Recognizing The Risks & Benefits A Systematic Review

Amanda Maloney, BA and Sameep Chandrani, MBS

## Abstract

### Introduction:

This systematic review evaluates current literature relevant to barefoot running. It focuses on the potential benefits and injuries related to the lower extremity.

### Study Design:

Qualitative Systematic Review of the Literature

### Methods:

Information for this literature review was retrieved from a PubMed search using the term "barefoot running." The search returned 128 results, of which 40 articles were selected. Articles were chosen based on relevancy as determined by their abstracts. Both authors reviewed the most recent articles that addressed the associated risks and benefits of barefoot running, and related those risks and benefits to the lower extremity and/or gait. Articles that were not relevant to these criteria were not included.

### Results:

Barefoot running is associated with benefits such as alleviation of anterior tibial stress syndrome, as well as injuries like metatarsal stress fractures. It is difficult to give objective results as there is currently a lack of clinical evidence to show an increase or decrease in the incidence of injury upon transition from shod to barefoot running. The same is true for the reported benefits.

### Conclusions:

Runners continue to experiment with various barefoot running practices despite a lack of evidence pertaining to the risks and/or benefits. Future research should further examine the potential for injury on a subjective basis.

**Keywords:** Barefoot Running

**Level of Evidence:** 4

## Introduction

The popularity of barefoot (BF) running has been on the rise in recent years. With the transition from a traditional cushioned running shoe to a barefoot running style comes the potential to alleviate or prevent some injuries and/or acquire entirely new ones. The conversion from a rearfoot strike to a forefoot or midfoot strike has been well reported in current research as the primary difference between shod and barefoot running styles. This biomechanical transition allows for less impact force and will hypothetically reduce injury, however, current research has yet to hone in on the specific risks and/or benefits. Injuries, particularly stress fractures, have been reported in the post-transition phase from shod to barefoot running. Reported injuries may be due to the biomechanical changes that are responsible for positive effects as well, such as a reduction in anterior compartment syndrome.

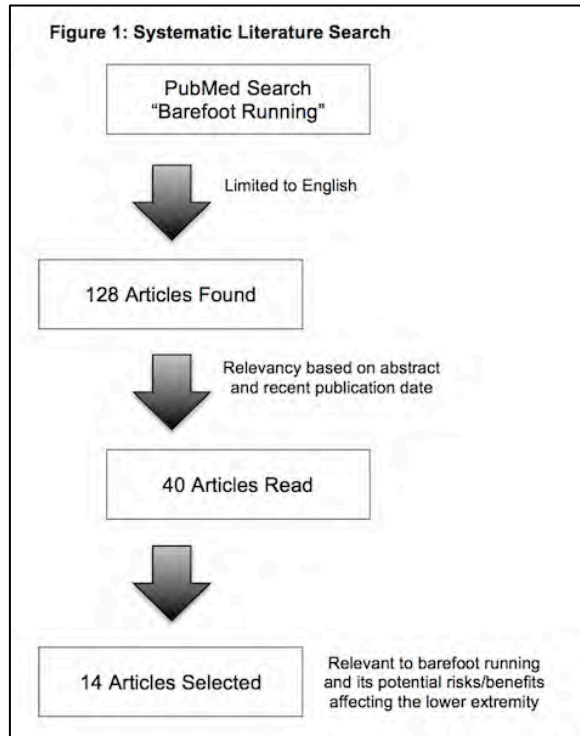
The purpose of this systematic review is to better understand and outline the differences between shod, barefoot, and barefoot mimicry running styles as it pertains to the potential risks and benefits. By clearly defining barefoot running and its variations based on current full-text literature, there is opportunity to expose where information is lacking and propose future research.

## Methods

Information for this literature review was retrieved from a PubMed search, limited to the English language, using the term "barefoot running." No exclusion/inclusion operators were used. The search returned 128 results and 40 articles were selected based on abstracts and publication date. 40 articles were considered



and 14 were ultimately selected for review (Figure 1). Articles deemed relevant were recently published and addressed the associated risks and benefits of barefoot running pertaining to the lower extremity and/or gait. Articles that failed to meet these criteria were not included.



## Results

Our literature search revealed articles that address the biomechanical changes that occur when one transitions from shod to barefoot running (Table 1). The primary emphasis among many of the current articles reviewed is a conversion from a rearfoot strike to a forefoot or midfoot strike. Reported injuries were addressed as well, but a lack of available clinical evidence, such as randomized clinical control trials, makes it difficult to propose a firm correlation between specific injuries and barefoot or minimalist running. The same is true for any suggested benefits of the activity.



## Discussion

### *Barefoot Variations*

Runners who identify themselves as participants in barefoot practices vary when it comes to technique. There is, of course, the population that practices strictly barefoot; completely unshod<sup>11</sup>. Branching off that concept is minimalist footwear. Vibram Fivefingers® (Figure 2) are thin, flexible shoes meant to replicate the barefoot condition. Although they were not originally marketed for the practice, they are now popular among barefoot runners<sup>13</sup>. Other popular shoes, like Nike Frees® (Figure 3) are more substantial in support, but are designed to allow the foot to move more naturally, as if in a BF state, unlike traditional running shoes.<sup>8</sup> Several popular brands produce shoes that are marketed under a similar concept. Current research is lacking in uncovering the specific differences among brands and models.

### *Trending Support*

A popular supporting idea of barefoot running arises from an evolutionary perspective. In his article backing the practice of barefoot running, Lieberman claims that it should not be considered a trend nor should it be deemed dangerous because it is what our primal ancestors practiced<sup>5</sup>. In fact, in areas of the world where people are routinely barefoot, chronic injuries to bone and connective tissue occur less frequently. And in regions where shod and unshod populations exist together, injury is more predominant in the shod group<sup>10</sup>. The avoidance or threats of injury as it pertains to BF

**Table 1: Potential Effects of Barefoot/Minimalist Running & Forefoot Strike**

Advantages	Risks
<ul style="list-style-type: none"> <li>Increased plantar proprioception may contribute to balance and stability<sup>5,6,12</sup></li> <li>Pressure may be dispersed to a wider area, allowing for functional avoidance of injury<sup>10</sup></li> <li>Active internal support by intrinsic musculature<sup>10</sup></li> <li>Reduction of plantar pain due to a lack of constriction<sup>6</sup></li> <li>Decreased impact at the tibia and alleviation of anterior compartment syndrome<sup>2</sup></li> <li>Increased cadence reduces moment arm of ground reaction force, thus reducing loading at knee and hip joints<sup>1</sup></li> </ul>	<ul style="list-style-type: none"> <li>Lack of cushioning and protection from external elements</li> <li>Increased strain on Achilles tendon with forefoot strike<sup>1</sup></li> <li>Increased strain on gastrosoleus during midstance due to more plantarflexion<sup>14</sup></li> <li>Power absorption transfer from the knee to the ankle, thus increasing risk of ankle and/or foot injury<sup>14</sup></li> <li>Increased load at metatarsal heads, potentially increasing risk of metatarsal stress fracture<sup>1,3</sup></li> <li>Increased tensile stress in the plantar flexors<sup>4</sup></li> </ul>

practices are widely debated, but there is not enough peer-reviewed evidence to compare the injury rates between barefoot, minimalist footwear, and shod running conditions<sup>6</sup>.

It has been reported that as much as 79% of runners are injured within a given year<sup>1</sup>. A survey of runners conducted by Rothschild revealed that injury prevention was the most prevalent motivating factor for those who added minimalist or barefoot running to their training program. Paradoxically, a fear of potential injury was the prevailing deterrent to trying these practices<sup>10</sup>. In fact, opponents of BF and minimalist running claim that it may alter the type, not frequency, of injury<sup>9</sup>. A recent case series looked at several experienced minimalist runners who presented with stress fractures of the metatarsals and calcaneus and plantar fascia rupture. However, similar injuries have been reported in habitually shod runners<sup>11</sup>.

While there are many factors that contribute to the avoidance of injury, the traditional running shoe is meant to offer cushioning, elements of stability, and protection. Proponents of BF and minimalist running claim that traditional running shoes limit plantar proprioception, which may prevent runners from maintaining stability in order to avoid injury<sup>5</sup>. Past studies suggest that running shoes may even increase the risk of ankle sprains due to such diminished proprioception<sup>6</sup>.

Current literature claims that a well-trained unshod foot disperses pressure to a wider area and allows for functional avoidance of injury. There is an active, internal support by the foot musculature in lieu of the passive, external support of a shoe<sup>10</sup>. It has been suggested that the stiff soles and arch supports of modern running shoes could promote weakening of the intrinsic musculature and create reduced arch strength<sup>10</sup>. Squadrone et al concluded that cushioned running shoes

significantly impair foot position awareness compared to less structured shoes like the Vibram Fivefingers®<sup>12</sup>. Another study showed that minimalist footwear might result in reduced plantar pain during exercise due to the lack of such constrictions brought on by a traditional running shoe<sup>6</sup>.

#### *The Biomechanics*

But what exactly is occurring from a biomechanical perspective in the transition from shod to BF or minimalist running practices? It has been widely stated in current literature that there is a shift from rearfoot strike to forefoot or midfoot strike when going from a shod to a BF or minimalist condition<sup>11</sup>. The rearfoot strike of shod runners may be due to the elevated and cushioned heel of the running shoe<sup>1</sup>. However, it's possible that the limitations of footwear do not prevent one from taking on a forefoot strike or midfoot strike pattern. Williams et al found that overall changes in the lower extremity and in power absorption appear to be more pronounced in a forefoot strike *shod* condition. Therefore, it may not be necessary to run BF or in minimalist shoes in order to gain the potential benefits<sup>14</sup>. Conversely, it is not guaranteed that one will automatically transition to a forefoot strike pattern upon making the switch to BF. In the same study by Williams, it was found that only 60% of runners in the BF condition actually adopted a midfoot or forefoot strike pattern<sup>14</sup>. This suggests that a number of runners will maintain a rearfoot strike pattern while BF running. It should be noted that none of the subjects in the study were experienced BF runners<sup>14</sup>.

Upon forefoot strike, there is more plantarflexion and conversely, there is more dorsiflexion in a rearfoot strike pattern<sup>14</sup>. A forefoot strike creates a defined impact peak in the ground reaction force upon contact, resulting

in high loading rates early in stance phase. Forefoot strike-practicing runners reduce such impact via transient loading through the posterior compartment muscles, and this may result in increased strain on the Achilles tendon.<sup>1</sup> Equally, a transition from rearfoot strike to forefoot strike is associated with a decrease in impact attenuation at the tibia.<sup>2</sup>

In theory, BF or forefoot strike running may reduce medial tibial stress syndrome, or “shin splints,” but increase the risk of Achilles tendon-related injuries.<sup>6</sup> Increased plantarflexion at initial contact results in greater shortening of the gastrocnemius and soleus, thus requiring more work from these muscles. Such musculature may be more stressed during midstance, when there is a transition from eccentric to concentric contraction<sup>14</sup>. In a case series of 2 runners with chronic exertional compartment syndromes, changing to a shod forefoot strike running pattern was the main intervention. It was hypothesized that more forefoot contact would require less dorsiflexion and would reduce eccentric activity of the anterior compartment, thus theoretically alleviating anterior compartment syndrome.<sup>7</sup>

Forefoot strike has been shown to result in an increased step rate and decreased step length<sup>7</sup>. The increased cadence and decreased stride length may contribute to reducing the chances of developing a tibial stress fracture. Furthermore, the shorter stride length reduces the moment arm of the ground reaction force to the hip and knee joints, thereby reducing the loading at these joints<sup>1</sup>. This shift in power absorption from the knee to the ankle in forefoot and BF conditions may result in increased risk of injury at the foot and ankle<sup>14</sup>.

There is also potential for injury distal to the ankle. Landing on the ball of the foot, which may be more pronounced in forefoot and midfoot strike patterns, will likely increase stress on the metatarsal heads<sup>1</sup> and create a tensile stress within the plantar flexors.<sup>4</sup> Giuliani et al reported on barefoot-simulating footwear being associated with metatarsal stress injury in two patients, both of whom were experienced runners who made the transition to a BF style.<sup>3</sup> Additionally, in a study that compared running in barefoot conditions, Vibram Fivefingers® shoes and running shoes, the authors found peak pressure to be highest under the toes.<sup>12</sup>

A midfoot strike pattern may place the perpendicular position of the vertical ground reaction force further from the ankle joint center in comparison to a forefoot strike pattern. This could potentially increase the torsional forces on the midfoot and forefoot, which are commonly

directed toward the dorsiflexion of the metatarsals on the cuboid and cuneiforms. While it is unknown how these joints will respond to repetitive dorsiflexion stress, it may contribute to the evidence associating metatarsal stress fractures with the strike pattern in BF running<sup>14</sup>. In a recent study by Williams et al, three separate running conditions were examined in experienced runners: shod with rearfoot strike, shod with forefoot strike, and barefoot. It was shown that initial contact forces are transmitted through the smaller midfoot bones and muscles in the forefoot strike and BF conditions, versus through the calcaneus, talus, and tibia in the rearfoot strike condition<sup>14</sup>. Different foot types may respond differently to these increasing forces.

In addition to the lack of research examining certain foot types, few studies look at the effects of different running surfaces when transitioning to BF or minimalist styles. The type of running surface affects the ground reaction force. Both shod and unshod runners adjust “leg stiffness” by employing different muscles in order to experience similar impact forces regardless of surface.<sup>6</sup> However, as mentioned previously, the muscles recruited differ in a shod versus unshod condition. Lieberman points out that habitually shod runners who run barefoot are more likely to strike with the rearfoot on soft surfaces and transition to a forefoot or midfoot strike when running on hard surfaces.<sup>5</sup> In general, it is recommended to change running surfaces gradually to allow the body to acclimate.<sup>6</sup>

## Conclusion

Despite the possible harmful effects, determined runners will continue to experiment with various BF running practices. We recommend that future studies strive for specificity in the examination of barefoot versus shod running. In doing so, there needs to be a clear distinction made between the practice of unshod running and forefoot strike pattern, as the former may not always result in the latter, and vice versa. Future research should continue to examine minimalist and barefoot conditions separately, despite the similarities. The effects of individual anatomical structures, such as length of metatarsals and the conditions of surrounding joints, are primary concerns. Various foot types should also be taken into consideration. Lastly, different running surfaces should be examined in each condition.

The decision to practice a minimalist or barefoot running style should be considered carefully on an individual basis, as certain foot

types may be more vulnerable to certain injuries.<sup>6</sup> Not all runners will benefit from a transition to barefoot running. However, one may continue to benefit from the protective elements of a modern running shoe and still make variations in his or her foot strike pattern. Shoe gear not only provides protection, but also allows for the insertion of corrective orthotics<sup>6</sup>, which may be an absolute necessity for some. Running surfaces should be taken into account as well. Unshod runners should be especially cautious of external hazards.

### Author's Contributions

AM conceived the initial idea of study and both authors contributed to the ultimate design. SC and AM conducted individual literature searches of the PubMed database in order to obtain articles that met the criteria of the review. Both authors wrote the paper and each provided their ideas for the discussion section. SC and AM read and approved the final manuscript.

### Statement of Competing Interest

The authors declare that they have no competing interest in relation to this manuscript.

### References

1. Altman AR, Davis PT. Barefoot running: biomechanics and implications for running injuries. *Current Sports Medicine Reports*. 2012; 11(5):244-50.
2. Delgado TL, Kubera-Shelton E, Robb RR, Hickman R, Wallmann HW, Dufek JS. Effects of foot strike on low back posture, shock attenuation, and comfort in running. *Medicine and Science in Sports and Exercise*. 2012 Oct 15.[Epub ahead of print].
3. Giuliani J, Masini B, Alitz C, Owens BD. Barefoot-simulating footwear associated with metatarsal stress injury in 2 runners. *Orthopedics*. 2011; 34(7): 320-3.
4. Gross DL, Gross MT. A review of mechanics and injury trends among various running styles. *US Army Medical Department Journal*. 2012; Jul-Sep:62-71.
5. Lieberman DE. What we can learn about running from barefoot running: an evolutionary medical perspective. *Exercise Sports Science Review*. 2012; 40(2):63-72.
6. Lohman EB, Sackiriyas KSB, Swen RW. A comparison of the spatiotemporal parameters, kinematics, and biomechanics between shod, unshod, and minimally supported running as compared to walking. *Physical Therapy in Sport*. 2011; 12: 151-163.
7. Lorenz DS, Pontillo M. Is there evidence to support a forefoot strike pattern in barefoot runners? A Review. *Sports Health: A Multidisciplinary Approach*. 2012;4:480-4.
8. Nike, Inc. Nike Free® Website. <http://www.nike.com>. Accessed December 26, 2012.
9. Rixe JA, Gallo RA, Silvis ML. The barefoot debate: can minimalist shoes reduce running-related injuries? *Current Sports Medicine Reports*. 2012 May-Jun;11(3):160-5.
10. Rothschild CE. Primitive running: a survey analysis of runners' interest, participation, and implementation. *Journal of Strength and Conditioning Research*. 2012 Aug;26(8):2021-6.
11. Salzler MJ, Bluman EM, Noonan S, Chiodo CP, de Alsa RJ. Injuries observed in minimalist runners. *Foot and Ankle International*. 2012. April;33(4):262-6.
12. Squadrone R, Gallozzi C. Effect of a five-toed minimal protection shoe on static and dynamic ankle position sense. *The Journal of Sports Medicine and Physical Fitness*. 2011; 51: 401-408.
13. Vibram Fivefingers®. Barefoot Education. <http://www.vibramfivefingers.com/education/index.htm>. Accessed on December 26, 2012.
14. Williams DSB, Green DH, Wurzinger B. Changes in lower extremity movement and power absorption during forefoot striking and barefoot running. *The International Journal of Sports Physical Therapy*. 2012; 7: 525-532.

# Literature Review of the Surgical Methods of Late-stage Freiberg's Disease: Diagnosis and Treatment

HaeKang Yang, BS, Joseph Park, BA, and InnJea Park, MBS

## Abstract

### Introduction:

The purpose of this study is to introduce the reader to surgical methods of late-stage Freiberg's Disease. These procedures include arthroplasty with cheilectomy, dorsiflexion osteotomy, arthroscopic interpositional arthroplasty, autologous osteochondral transplantation with external fixation, osteochondral plug transplantation, titanium hemi-implant and amputation.

### Study Design:

Qualitative Systematic Review of the Literature

### Methods:

A PubMed database search was performed with the inclusionary term "Freiberg" and "surgery". Foot & Ankle International was also searched. A total of 85 articles were found. The authors read and reviewed 28 and chose 17. The authors excluded articles that discussed more general metatarsal pathologies and conservative treatment options.

### Results:

There is currently no general consensus on which surgical procedure is optimal for treating late-stage Freiberg's disease. When considering post-operative recovery length, range of motion, and severity of complications, the authors determined that the dorsiflexion osteotomy with an external mini-fixator is the best procedure to treat Freiberg's disease.

### Conclusions:

Although the authors believe that dorsiflexion osteotomy with an external mini-fixator is the best treatment option, more studies are needed to establish a consensus regarding proper surgical treatment for late-stage Freiberg's disease. Further research should be conducted in the form of randomized clinical trials in order to determine the effectiveness of surgical procedures depending on the patients' medical conditions.

**Key Words:** Freiberg, Surgery

**Level of evidence:** 4

## Introduction

The purpose of this study is to introduce the surgical methods of late-stage Freiberg's disease. Freiberg's disease is the osteochondrosis of one or more of the metatarsal heads. Osteochondrosis is a pathologic process of the ossification centers, involving necrosis and recalcification of the bone. It was first reported on a series of six cases in 1914 by Freiberg.<sup>1</sup> Freiberg's disease is relatively rare and difficult to treat. Freiberg's disease is the only osteochondrosis more common in females of ages 11 to 17 with a 5 to 1 female preponderance.<sup>1,2</sup> It occurs most commonly in the second metatarsal and can lead to pain, swelling, ischemic necrosis, flattening, and eventual collapse of the metatarsal head. Our theory is that the second metatarsal is most commonly the longest metatarsal and the increased weight load may have an effect on the development of the growth plate.<sup>3</sup> Bilateral involvement is reported in less

than 10 percent of cases.<sup>3</sup> The second metatarsal is affected in 68 percent of the cases, the third metatarsal in 27 percent, the fourth in 3 percent, and the fifth rarely.<sup>2,4</sup>

The clinical progression is classified into 5 stages by Smillie.<sup>5</sup> In Stage I, a narrow fissure fracture is found in the epiphysis.<sup>5</sup> At this stage, radiographs often fail to detect the fracture or the ischemia of bone because the fracture zone is too narrow.<sup>5</sup> In Stage II, cancellous tissue on the proximal side of the fracture has begun to be absorbed so the affected cartilage on the dorsal side of the metatarsal begins to sink and appears as a flattening of the head.<sup>5</sup> In Stage III, further absorption of cartilage has occurred so the central portion of the cartilage sinks into the head of the metatarsal.<sup>5</sup> The plantar articular cartilage remains intact in this stage.<sup>5</sup> In Stage IV, the plantar isthmus of articular cartilage has given way and the loose body separates.<sup>5</sup> Fractures of the lateral and dorsal projections have occurred.<sup>5</sup> From this stage on, restoration

is impossible.<sup>5</sup> Stage V, the final stage, is characterized by flattening and deformity of the metatarsal head and a critical loss of joint space.<sup>5,6</sup>

Surgeons consider Smillie's<sup>5</sup> Stages I and II to be early stages and Stage III, IV and V to be late stages.<sup>7</sup> Conservative therapy is recommended at every stage. If it fails, surgical intervention is considered. Due to the fact that the articular cartilage, which has no blood supply, remains intact and is unaffected by the ischemic process in the underlying bone, it is possible to restore it to its normal, healthy conformation.<sup>5</sup> Therefore, Stage III is the latest stage for non-surgical treatment such as orthotics, boot, or cast.<sup>5</sup> In the later stages, there are no clear guidelines regarding surgical treatment.<sup>7</sup> In this article, we mainly focused on surgical intervention for late-stage Freiberg's disease.

## Methods

The authors conducted research using PubMed searches under the MeSH keywords "Freiberg" and "surgery". Language limits were set to English only. Since there were few results, the authors expanded the search to 1991. The majority of the papers were from 2004 or later. The authors found 50 articles that were related to the subject. The authors also searched through specific journals such as Foot & Ankle International and found 35 articles, including some that were published within the past three years. The 17 articles included in this review are ones that discussed outcomes of different surgical techniques for the treatment of late-stage Freiberg's Disease. The authors excluded articles that discussed more general metatarsal pathologies and conservative treatment options.

## Results

There is currently no general consensus on which surgical procedure is optimal for treating late-stage Freiberg's disease. When considering post-operative recovery length, range of motion, and severity of complications, the authors determined that the dorsiflexion osteotomy with an external mini-fixator is the best procedure to treat Freiberg's disease.

## Discussion

### *Diagnosis:*

Avascular necrosis of the second metatarsal head is the fourth most common osteochondrosis, or necrosis and recalcification of the bone, in the body.<sup>8</sup>

Risk factors include trauma, vascular insufficiency and systemic disorders such as diabetes mellitus, systemic lupus erythematosus, and hypercoagulability conditions which can cause an increase in intraosseous pressure.<sup>9</sup> Repetitive dorsal metatarsophalangeal joint movement due to a relatively long second metatarsal bone has been suggested as a significant factor in the development of Freiberg's.<sup>10</sup> The second metatarsal has the least mobility due to the cuneiform mortise formed around its base, causing the head to receive greater stress relative to the other metatarsals. Malalignments such as hallux rigidus and hallux valgus can cause increased loading forces on the second metatarsal head.<sup>11</sup> Other suspected risk factors include high-heeled shoes which results in increased weight-bearing to the forefoot and repetitive dorsiflexion at the metatarsophalangeal joint.<sup>2</sup> A hypothesized genetic component has been found in a limited number of cases.<sup>12</sup>

Patients generally present with pain localized to the metatarsal head region that worsens with walking, especially when barefoot. Patients may describe the sensation as if they were walking on a hard surface. The foot may be edematous at the affected joint. In more severe cases, sagittal and/or coronal plane malalignments may be present. Range of motion will be significantly decreased, and as a result, there may be a callus found on the plantar pad of the affected metatarsal. In Stages I and II, generalized tenderness in the joint region may be the only symptom.<sup>2</sup> During the physical examination, a Lachman test can be used to examine the joint integrity. If the joint subluxes dorsally, it will reproduce the patient's pain and is considered an abnormal positive finding. This test must also be performed on the contralateral foot. The patient's pain may or may not coincide with a traumatic event, and palpation of the region will usually cause pain.<sup>9</sup>

Differential diagnoses for Freiberg's disease may include metatarsal stress fracture, metatarsophalangeal joint synovitis or capsulitis, extensor or flexor tendinitis, collateral ligament injury, fracture, dislocation, juvenile rheumatoid arthritis (Still's disease), and inflammatory periostitis.<sup>13</sup>

Several different imaging studies have been used to help diagnose Freiberg's disease. The consensus is that the lateral oblique radiograph



Table 1: Smillie Classification <sup>5</sup> (1967)	
Stage I	A narrow fracture develops in the ischemic epiphysis.
Stage II	Central collapse and flattening of the metatarsal head. Plantar cartilage remains intact.
Stage III	Depression and further flattening of the metatarsal head. Plantar cartilage remains intact.
Stage IV	Loose body formation from fractured peripheral projections and plantar cartilage is no longer intact causing separation of the distal fragment.
Stage V	End-stage degenerative joint disease, with marked flattening and widening. The shaft of the metatarsal is thickened and dense.

is the most important.<sup>2</sup> The lateral oblique view allows the physician to see abnormalities that are unapparent in the anterior-posterior view, such as the flattening of the dorsal metatarsal head. The earliest radiographic finding is joint space widening. In later stages one can see central joint depression, loose body formation, and sclerosis of the metatarsal shaft as a response to abnormal stress.<sup>2</sup> Magnetic resonance imaging has been used for early detection of Freiberg's disease. The MRI will show changes in marrow intensity and thus can show the onset of osteonecrosis. It will display a hypointense signal with T1-weighted images and mixed hypointense and hyperintense signals with a T2-weighted image.<sup>9</sup> Bone scans have been used in a limited number of cases and can detect early signs of avascular necrosis. There are a very limited number of studies that have used it. Computerized tomography has been used to demonstrate the degree of separation of the distal osteochondral fragment from the head and loose body formation using transverse and sagittal plane views.<sup>6</sup>

Several authors have suggested various staging methodologies for Freiberg's disease. The most widely used classification system is the one proposed by Smillie in 1967.<sup>5</sup> Smillie described the progression of the disease in five phases, as shown in Table 1 (adapted from <sup>6</sup>). Stages I and II are considered early-stage and Stages III-V are considered late-stage.

#### *Treatment:*

For early-stage Freiberg's disease (Stages I and II of Smillie's classification), non-operative therapy should be the primary approach of treatment. It is generally accepted that surgical treatment should be used for patients with late-stage Freiberg's disease who have failed to respond to conservative therapy. However, there is no consensus or set of guidelines regarding which surgical interventions should be applied to the patient to relieve symptoms and prevent progression of the disease. Therefore, there are numerous procedures reported in the literature. Freiberg, in his original article, described the removal of loose bodies in the affected joint.<sup>1</sup> Smillie described elevating the depressed articular fragment with a cancellous bone graft.<sup>5</sup> Some authors have suggested resection of the metatarsal head or the base of the proximal phalanx. Gauthier and Elbaz described a dorsiflexion osteotomy of the metatarsal head.<sup>4</sup> More recently, Hayashi et al described the new surgical technique of osteochondral plug transplantation for late-stage Freiberg's disease.<sup>7</sup>

The primary surgeries for late-stage Freiberg's disease that are presented in this section include the following: arthroplasty with cheilectomy, dorsiflexion osteotomy, arthroscopic interpositional arthroplasty, autologous osteochondral transplantation with external fixation, osteochondral plug transplantation, titanium hemi-implant and amputation.

Although patients with early Freiberg's disease should initially be treated with non-invasive measures such as shoe modifications,

anti-inflammatory medications, continuous skeletal traction and core decompression, they can also undergo surgical procedures via arthroplasty and cheilectomy of the affected MTPJ. Resection of affected cartilage and subchondral microfracture or fenestration to facilitate neoangiogenesis is typically performed. It is best for limited involvement of the joint articular surface and is unlikely to be successful in end stage Freiberg or in isolation in joints with signs of sagittal or transverse plane instability.<sup>14</sup>

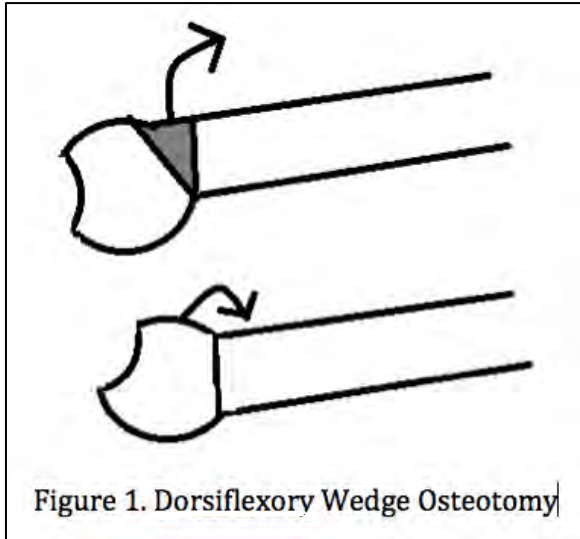


Figure 1. Dorsiflexory Wedge Osteotomy

Advanced degenerative changes caused by late-stage Freiberg's disease may be approached with a dorsiflexory metatarsal osteotomy.<sup>14</sup> There are several slight variations as to how to implement this surgical procedure. Patrick Kinnard and Richard Lirette carried out dorsiflexion osteotomy (Figure 1)<sup>15</sup> on 13 women

and two men with symptomatic Freiberg's disease after failure to respond to conservative treatment. Their surgical techniques were comprised of a wide metatarsophalangeal arthrotomy to expose the metatarsal head (Figure 2)<sup>15</sup>. After joint debridement, an intra-articular dorsal wedge osteotomy was performed through the distal metaphysis with sufficient bone removal to bring the unaffected plantar region of the metatarsal head up. All patients were reviewed clinically. Pain relief was complete and all patients were able to enjoy sporting activities not possible before the surgery. However, some negative consequences were observed as well: patients experienced reduced metatarsophalangeal flexion by 15 degrees (range 0-30) and metatarsophalangeal extension by 10 degrees (range 0-30) and the metatarsal was shortened by 2.5mm (range 0 to 4 mm).<sup>15</sup> Though this classic measure can bring out satisfactory outcomes, complications such as delayed union and limitation of motion at the MPJ may occur.<sup>16</sup>

Xuetao Xie et al presented a modification to the traditional dorsal wedge osteotomy. In his approach, the joint is distracted by an external mini-fixator.<sup>16</sup> The distracted joint is believed to enhance cartilage self-repair and prevent joint contracture. On average, a space of 4 to 5mm was maintained after removal.<sup>16</sup> Since reliable fixation can still be achieved even with a large portion of the metatarsal head being resected, this technique seems to be appropriate for late-stage Freiberg's disease.<sup>16</sup> From April 2009 to May 2011, 12 female patients with stages IV and V Freiberg's disease underwent the dorsal wedge

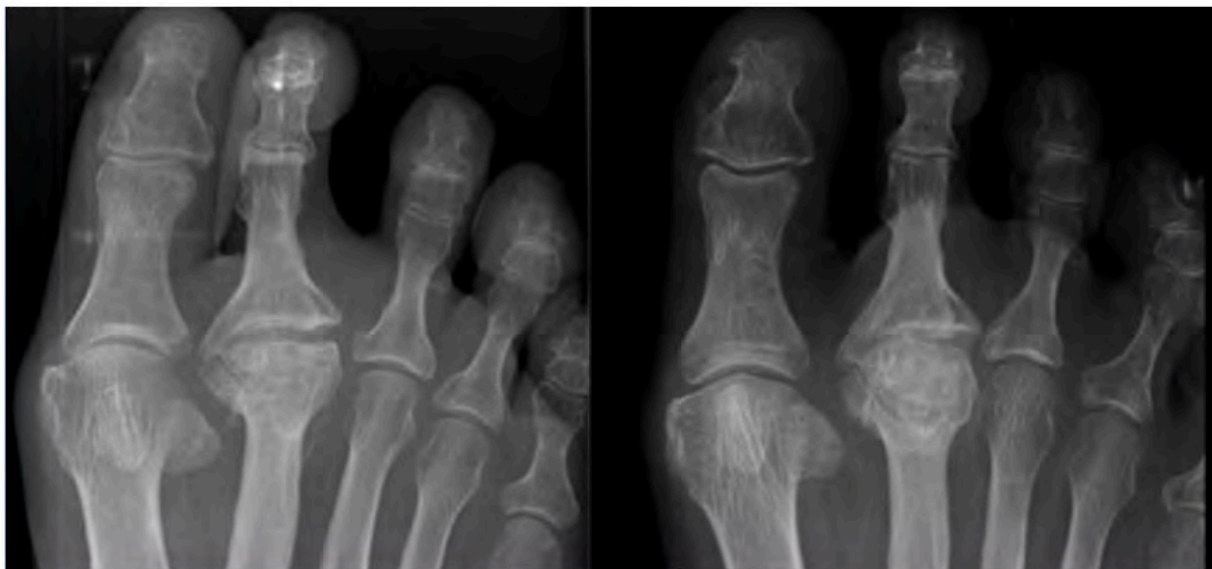


Figure 2. Late Stage Freiberg's Disease

osteotomy combined with the MTP joint distraction.<sup>16</sup> Prior to the surgery, most patients exhibited severely restricted plantarflexion of the second MTP joint while the metatarsal head and the proximal phalanx were severely degenerated with abundant inflammatory tissue. Postoperatively, the mean follow-up was 18 (range: 11 to 33) months.<sup>16</sup> All patients had uneventful bone union. Pain on a visual analog scale improved significantly from an average of 8.2 to 2.2 ( $p < 0.05$ ) and range of motion of the involved MTP joints increased by an average of 37 degrees (range: 25 to 70 degrees).<sup>16</sup>

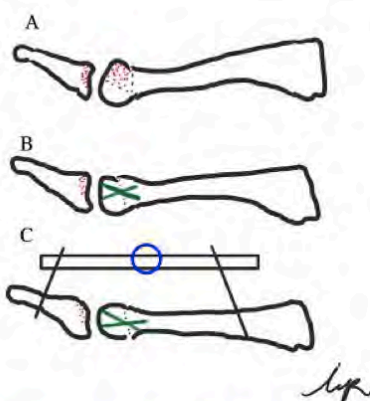


Figure 3. Diagram showing the dorsal wedge osteotomy and joint distraction arthroplasty. (A) Illustration of the diseased portion of bone (dotted area) and the area to be osteotomized (the portion between the dotted lines) in the late-stage Freiberg's disease with degeneration of the MTP joint. (B) After osteotomy, the metatarsal head was fixated with two absorbable pins. (C) The MTP joint was then distracted axially with an external mini-fixator.

In comparison to the dorsal edge osteotomy alone, the addition of MTP joint distraction arthroplasty yields several theoretical benefits. First, the necrotic portion can be resected maximally and osteotomy can be fixed with only two absorbable pins. Instead of the conventional short leg cast, a pair of comfortable forefoot relief shoes can be used. Second, by avoiding placement of multiple pins (more than two), patients do not need to be concerned about further damage to the articular cartilage. Third, joint distraction can be maintained for the treatment of MTP degeneration during the bone healing process.<sup>16</sup>

Tun Hing Lui introduces arthroscopic interpositional arthroplasty, which is widely applied in the treatment of degenerative joint disease, in joints such as the sternoclavicular and trapeziometacarpal joint.<sup>17</sup> It is shown that the technique was extended for the management of Freiberg's disease. Metatarsophalangeal arthroscopy is performed with dorsolateral and dorsomedial portals.<sup>17</sup> Loose bodies are removed and joint surfaces

are debrided. Extensor digitorum brevis tendon graft is harvested, rolled and brought into the joint.<sup>17</sup> According to his case illustration, arthroscopic interpositional arthroplasty was performed on a 60-year-old woman with Freiberg's disease of her right second and third metatarsal heads. Upon a follow-up appointment at 26 months, her right second toe pain was resolved and there was mild plantarflexion of the second metatarsophalangeal joint which was asymptomatic.<sup>17</sup> Radiographs showed the joint space of her right second metatarsophalangeal joint still preserved.<sup>17</sup> Another case involved a 45-year-old woman with progressive right second toe pain for two years. She had a similar result after 19 months of follow-up.<sup>17</sup> This arthroscopic technique offers the potential advantage of a detailed examination and debridement of the joint with preservation of the capsule and surrounding soft tissue.<sup>17</sup> Furthermore, this technique is relatively easy and can be performed on an outpatient basis.<sup>17</sup>

Osteochondral autologous or allogeneic transplant grafting, initially popularized in the knee and ankle, may also be applied to the second MTPJ.<sup>14</sup> J. George DeVries et al described the use of an external fixation device for distraction of the joint in combination with transplantation of an autologous osteochondral graft for a 15-year-old female with Freiberg's disease.<sup>6</sup> This surgical procedure can be distinguished from other techniques due to the incorporation of the knee as a source for a graft. In this particular case, the degenerated osteochondral tissue was removed from the second metatarsal head. An 8x15 mm plug of osteochondral graft was retrieved from a site on the femoral condyle of the ipsilateral knee with a contour similar to the second metatarsal head.<sup>6</sup> The graft was then tamped flush into place in the metatarsal head and the operative sites were closed.<sup>6</sup> At 15 months post-operatively, an MRI revealed excellent graft incorporation.<sup>6</sup> There was mild increased uptake near the second metatarsal head at 19 months. The patient had no complaints of pain with athletic activities despite presenting with dorsal capsular tightness, reduced plantarflexion, and mild pain with forced movement.<sup>6</sup> Just as Xuetao Xie et al<sup>16</sup> emphasize the benefits of utilizing an external fixation with the dorsal wedge osteotomy process, George DeVries et al<sup>6</sup> assert that it enhances preservation procedures for osteochondral autologous transplant grafting as well.

Osteochondral plug transplantation, a surgical technique that appears to be similar to

the DeVries technique, yet displays subtle differences, was introduced by Watatu Miyamoto et al.<sup>7</sup> He treated four female patients (average age 12) with late-stage Freiberg's disease using osteochondral plug transplantation. A plug of bone was harvested from a non-weight-bearing site of the upper lateral femoral condyle of the ipsilateral knee (Figure 5).<sup>7</sup> One important difference in their technique is that the cartilaginous surface of the harvested single plug lies approximately 70 degrees in relation to the long axis of the plug, creating a smooth convex configuration of the affected second metatarsal head after transplantation.<sup>7</sup> Conventionally, surgeons used two plugs 3.5 mm in diameter. But in this technique, the authors used a single plug with a diameter of 8.5 mm.<sup>7</sup> Applying this method, the authors were able to avoid creating a gap between two cylindrical transplanted plugs. This minimized the incongruity of the uncovered articular surface post-operatively.<sup>7</sup> As a result, clinical evaluation using the American Orthopaedic Foot and Ankle Society (AOFAS) revealed the excellent result at final follow-up at a mean average of 52 months of postoperative care.<sup>6</sup>

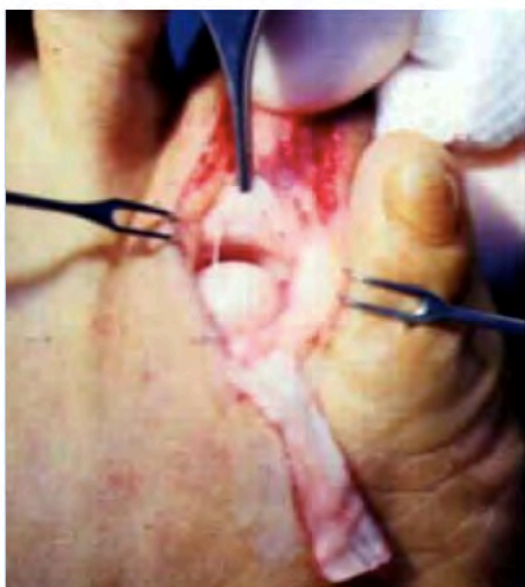

Fig. 4 Intraoperative findings. Exposed second metatarsal head in which the bone graft will be incorporated into.

Alan Shih and Richard Quint present yet another surgical procedure, the titanium hemi-implant technique.<sup>13</sup> They presented a case report of a 24-year-old woman with late-stage Freiberg's disease. The authors clarify that the titanium hemi-implant is not necessarily the procedure of choice for the treatment of Freiberg's disease.<sup>13</sup> However, it is beneficial in a way that allows for more aggressive surgical procedures to be performed in the future if necessary. This is

possible since the metatarsal parabola is not affected, thus minimizing the likelihood of a transfer lesion.<sup>13</sup>

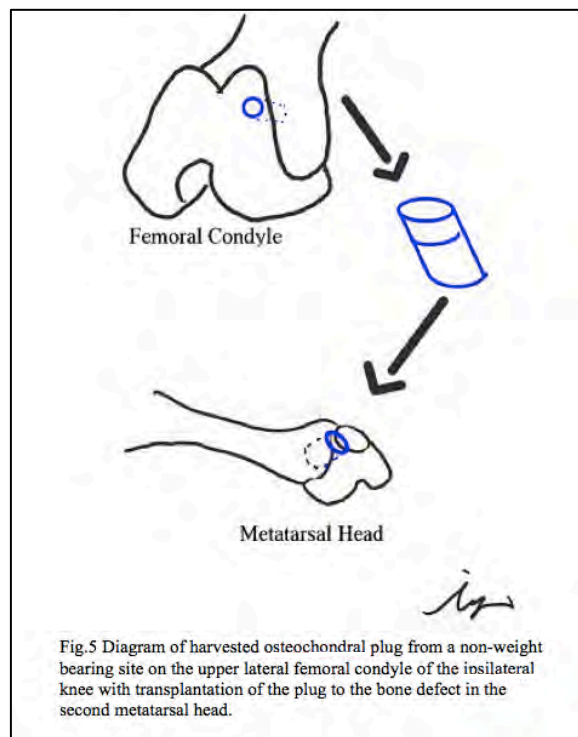


Fig.5 Diagram of harvested osteochondral plug from a non-weight bearing site on the upper lateral femoral condyle of the ipsilateral knee with transplantation of the plug to the bone defect in the second metatarsal head.

Lastly, amputation may also be considered as a surgical treatment for late-stage Freiberg's disease. Although not often considered first-line therapy, in certain patient populations with Freiberg's and severe crossover toe deformity, amputation of the second toe may be a treatment option.<sup>14</sup> In these cases, the patient's morbidities, activity level, age, or personal preference should be considered when making the final decision.<sup>14</sup>

Considering post-operative recovery length, range of motion, and severity of complications, the authors determined that the dorsiflexion osteotomy with an external mini-fixator is the best surgical procedure to treat Freiberg's disease.

### Conclusion:

The authors decided that length of post-operative recovery, post-operative range of motion, and complications were the three most important factors in determining the best surgical procedure. Based on these criteria, the dorsiflexion osteotomy with an external mini-fixator is the best option. It has the least amount of complications, increases the range of motion, and maintains the length of the ray. It is also easy to fixate and the patient does not require a leg cast during post-operative recovery. In contrast the traditional dorsiflexion osteotomy shortens the metatarsal and has complications

of delayed union. Osteochondral transplant grafting has similar results to the dorsiflexion osteotomy with external mini-fixation, but it requires another invasive procedure to acquire the graft and results in reduced range of motion. The osteochondral plug transplantation has the same issues, and in addition it also has the longest recovery time of 52 months. If the surgeon believes further aggressive procedures will be required in the future, the titanium hemi-implant is a good option. As a last resort, an amputation may be performed.

Currently, the sample sizes are too small to reach a definitive conclusion on the success or failure of their outcomes. Further research should be conducted in the form of randomized clinical trials in order to determine the effectiveness of surgical procedures depending on the patients' severity of disease. Once several randomized clinical trials have been carried out, a meta-analysis of the resulting data can be performed and the most optimal treatment for late-stage Freiberg's can be deduced.

### Author's Contributions

All authors contributed equally to this article.

### Statement of Competing Interests

The authors of this systematic review declare that they have no competing interests.

### References

1. Freiberg AH. Infraction of the second metatarsal bone. *Surg. Gynecol. Obstet.* 1914;19: 191-193

2. Cerrato RA Freiberg's disease. *Foot Ankle Clin.* 2011;16:647-658
3. Mandell GA, Harcke HT. Scintigraphic manifestations of infarction of the second metatarsal (Freiberg's Disease). *J Nucl Med* 1987;28:249-251
4. Gauthier G, Elbaz, R. Freiberg's infraction: a subchondral bone fatigue fracture. A new surgical treatment. *Clin. Orthop.* 1979;142:93-95
5. Smillie IS. Treatment of Freiberg's infraction. *Proc R Soc Med* 1967;60:29-31.
6. DeVries JG, et al. Freiberg's infraction of the second metatarsal treated with autologous osteochondral transplantation and external fixation. *J Foot Ankle Surg.* 2008;47(6):565-570
7. Miyamoto W, et al. Late-stage Freiberg Disease treated by Osteochondral plug Transplantation: A case series. *Foot&Ankle Int.* 2008;29:950-955
8. Omer GE, Primary articular osteochondroses. *Clin orthop* 1981;158:33
9. Carmont MR, et al. Current concepts review: Freiberg's disease. *Foot Ankle Int* 2009;30:167-76
10. Stanley D, et al. Assessment of etiologic factors in the development of Freiberg's disease. *J Foot Surg* 1990;29:444-7
11. McMaster MJ. The pathogenesis of hallux rigidus. *J Bone Joint Surg Br* 1978;60:82-7
12. Blitz NM, Yu JH. Freiberg's infraction in identical twins. *J Foot Ankle Surg.* 2005;44:218-21
13. Shih AT, et al. Treatment of Freiberg's infraction with the titanium hemi-implant. *JAPMA.* 2004;94:590-3
14. Capobianco CM. Surgical treatment approaches to second metatarsophalangeal joint pathology. *Clin Podiatr Med Surg.* 2012;29:443-449
15. Kinnard P, Lirette R. Freiberg's disease and dorsiflexion osteotomy. *J Bone Joint Surg.* 1991;73:864-865
16. Xie X, et al. Late-stage Freiberg's disease treated with dorsal wedge osteotomy and joint distraction arthroplasty: technique tip. *Foot & Ankle Int.* 2012;33:1015-1017
17. Lui TH. Arthroscopic interpositional arthroplasty for Freiberg's disease. *Knee surg Sports Traumatol arthrosc* 2007;15:555-559

# Common Injuries in Contact Sports: A Systematic Review

Sameep Y. Chandrani, M.B.S.†; Timothy J. Miller, B.A.†

## Abstract

### Introduction:

The ankle and foot are susceptible to injury during athletic competition. Common injuries occur at various parts of the foot and ankle, specifically at the ankle joint, the Lisfranc joint, and around the hallux at the metatarsophalangeal joint.

### Study Design:

Qualitative Systematic Review of the Literature

### Methods:

All PubMed searches were performed limiting the criteria to the English language and free full text availability. 500 articles were found for the various topics of which a total of 14 articles were selected based on their relevance to athletics and mechanism of injury

### Results:

The authors found that common injuries of the foot and ankle due to contact sports can occur in various locations due to multiple etiologies: trauma, excessive motion, improper loading, and structural abnormalities. Treatment found for these various injuries consist of both non-operative and operative methods, depending on the severity and nature of the injury.

### Conclusion:

This systematic review concludes that there are various mechanisms, symptoms and treatments for common foot and ankle injuries that occur in athletes and other active individuals. The purpose of this paper is to make clinicians aware of these components when treating patients with foot and ankle injuries so methods of prevention can be discussed or an effective treatment plan can be setup for better patient recovery and prevent future injury.

**Key Words:** fractures, ankle joint, lisfranc joint, turf toe, sand toe

**Level of Evidence:** 4

## Introduction

It is common for athletes to present to physicians with a variety of lower extremity injuries while participating in contact sports. Contact sports are usually defined as athletic activities in which the athlete is obligated to engage in physical contact with their opponent, such as American Football, but contact sports don't necessarily require physicality between players as a component. An example of this is sand volleyball, in which it is common to see contact between individuals and also forceful contact between an individual and the ground. It is common for a podiatric practice to see a wide range of injuries dealing with the foot and ankle, with certain injuries presenting more frequently than others. The ability for the podiatric physician to optimally manage the care of these individuals may be dependent upon the understanding of the mechanisms of injury and knowledge of the most effective treatments.

When considering the ankle joint mortise, the most common injury occurs as a result of trauma to the anterior talofibular

ligament.<sup>1</sup> In present-day athletes, these lateral ankle injuries have been observed to occur from a forced inversion and plantarflexion of the rearfoot on the tibia.<sup>2</sup> Since the anterior talofibular ligament is the weakest of the lateral collateral ligaments at the talocrural joint, these injuries are very common in active individuals and even athletes. Other structures may also be injured during a lateral ankle sprain such as: the peroneal tendons and the lateral joint capsule. There are many ways to classify a lateral ankle sprain, however, the major classification is based solely on the severity of damage to the ligaments. These sprains are graded on a scale from 1 - 3, one being the least severe to three being the most severe type of ankle sprain. It is with all this information, along with recognition of various signs and symptoms presented by the patient that initiation of a proper care plan can hasten the recovery process and help the athlete resume activities.

Further distally, common injuries among athletes are midfoot injuries. A common and debilitating midfoot injury is the Lisfranc



injury. These occur as a result of trauma to the tarsometatarsal articulation of the midfoot.<sup>5</sup> These injuries have been observed to occur in athletes when an axial force is driven down through the calcaneus while the foot is plantarflexed.<sup>5</sup> The historical basis of this injury dates back to the French surgeon Jacques Lisfranc de St. Martin. Lisfranc reported midfoot injuries of soldiers in Napoleon's army who fell from their horses while their foot remained plantarflexed in the stirrup (circa 1800).<sup>5</sup>

Along with these, many athletes present with injuries to the first metatarsophalangeal joint (MTPJ). Two specific injuries occur here and are common among athletes in different sports. The first is called "turf toe." As the name implies, this injury is common among athletes who participate on artificial surfaces, but can happen in a multitude of sports with different surfaces. Deemed a hyperextension injury, it typically occurs when the toes are dorsiflexed and a force is applied to a raised heel, resulting in tearing of the surrounding ligaments.<sup>10</sup> This injury is commonly seen in American football.<sup>12</sup> The other common injury to occur at the same joint is known as "sand toe," and typically occurs to athletes who participate in sports played on sand, particularly volleyball.<sup>13</sup> This injury occurs due to hyperflexion of the first MTPJ, typical of a player diving for a ball and the sand giving way underneath the toes. This results in dorsal capsule rupture and injury to the extensor tendons of the muscles surrounding it.

The purpose of this study was to compare ankle and foot injuries to athletes in contact sports to see which specific injuries occurred most often. A secondary aim was to compare the methods of treatment of the most common injuries to see which yielded the most effective outcomes.

## Methods

The database used to obtain literature sources on this topic was PubMed Central. A PubMed search was performed, limited to the English language and free full text availability, using the term "ankle sprains" with no immediate inclusion or exclusion criteria. 308 articles were found, and abstracts were reviewed. From these, nine articles were picked and read thoroughly, and finally four were selected based on their specificity towards the lateral ankle sprain criteria.

This was repeated with the term "Lisfranc injuries" with no inclusion or exclusion criteria. Abstracts were reviewed of the 91 articles present. 8 articles were picked for review and five were selected based on details

about injuries in contact sports. Another search was done with the term "turf toe," where 69 articles were present. Upon further review 3 were selected based on their relevance to the topic and their specificity of common mechanisms of turf toe injuries. Finally, a search was conducted using the term "sand toe." From the 32 articles present two were selected based on their relevance to athletics and the research of mechanisms of the injury (Figure 1).

## Results

Common Injuries	Location of Injuries	Common Signs & Symptoms	Treatment Available
Lateral Ankle Sprains	Anterior Tibio-Fibular Ligament is torn.	Swelling, stiffness, pain and muscle weakness	Non-operative and operative.
Lisfranc Injury	Medial cuneiform and base of second metatarsal	Bruising of plantar foot, swelling, pain, and a loss of arch	Non-operative and operative.
Turf Toe	MTPJ	Swelling with ecchymosis, pain, and misaligned hallux	Non-operative
Sand Toe	MTPJ	Pain with weight bearing. Weak dorsiflexion and swelling	Non-operative.

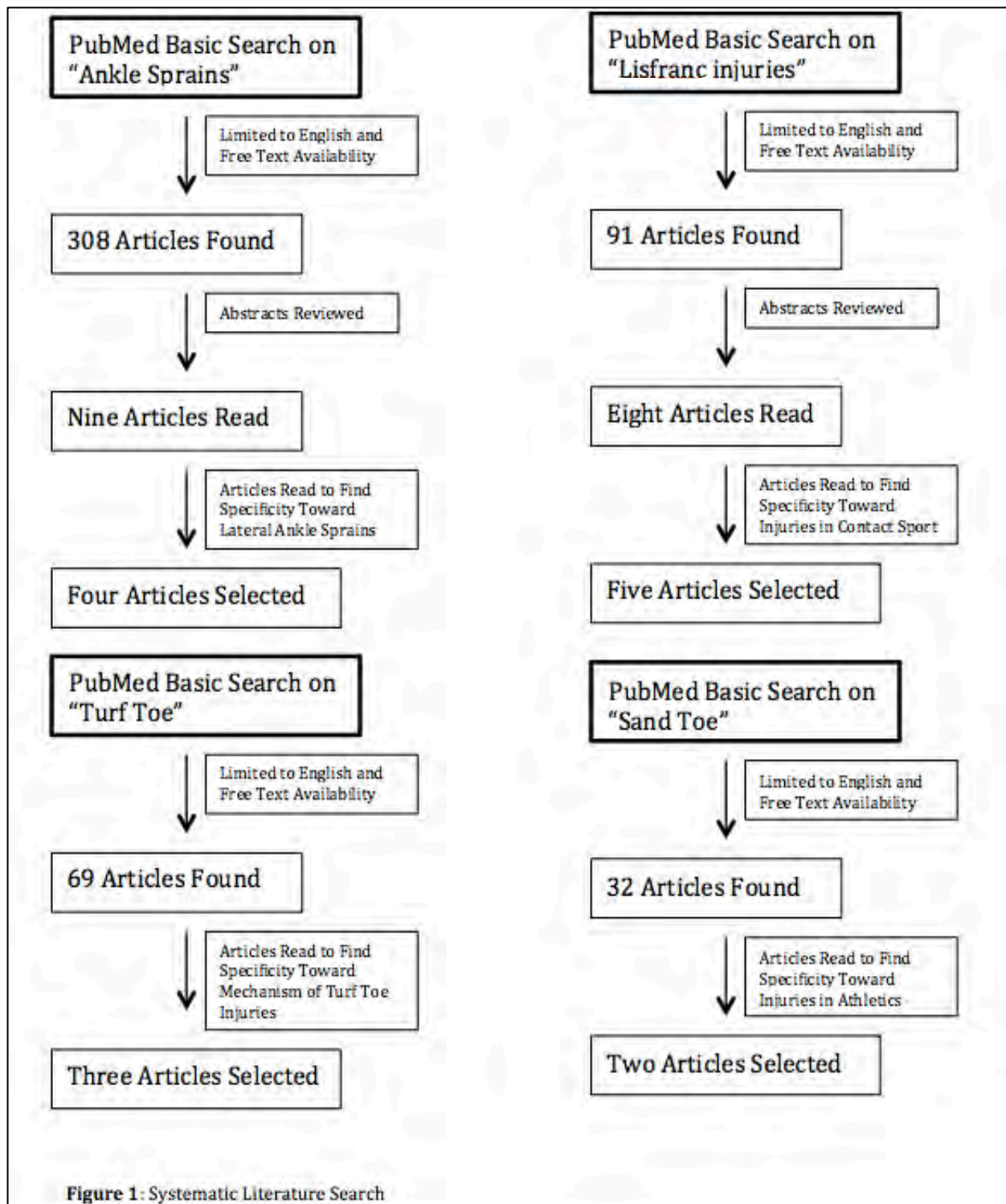
## Discussion

### Lateral Ankle Sprains

### Anatomy

On March 13<sup>th</sup>, 2013, basketball player Kobe Bryant of the Los Angeles Lakers suffered a lateral ankle sprain on his left foot. Due to the common occurrence of this injury in athletes, the anatomy of the ankle joint is important to know to correctly diagnose and treat this injury. The ankle joint connects the leg (tibia and the fibula) to the foot (talus). This joint, also known as the talocrural joint (TCJ), is essentially an ankle mortise with articulation between the distal portion of the tibia and fibula to the trochlear surface of the talus. The ankle joint functions together with the help of ligaments and tendons that encapsulate and protect it.

The main ligaments of the ankle are the medial (deltoid ligaments) and lateral ligaments

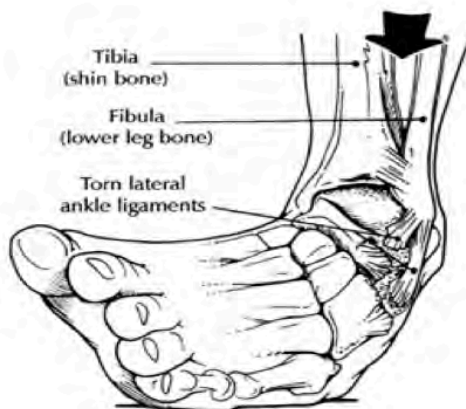


of the talocrural joint (lateral collateral ligaments). The deltoid ligament consists of the tibiocalcaneal, tibionavicular, and the posterior tibiotalar superficial branches, and the anterior tibiotalar and the posterior tibiotalar deep branches. Ligaments that support the ankle laterally include “the anterior talofibular (ATFL), calcaneofibular (CFL), and posterior talofibular (PTFL). The ATFL and the CFL are the primary stabilizers of the lateral side of the ankle,”<sup>2</sup> and

play an important role in lateral ankle sprains. Ligaments connect one bone to another and are made up of dense parallel bundles of collagen fibers. Ligaments provide strength and alignment to a joint but also support the joint during excessive motion. The purpose of ligaments is to resist excessive motion while collagen fibers dissipate the internal forces. “However if the load surpasses the mechanical strength of the ligament and is applied at a fast



velocity that exceeds the speed of a corrective muscle reflex, it may lead to microscopic failure of the collagen fibers or a complete rupture of the ligament”<sup>1</sup>.



**Figure 2: Lateral Ankle Sprain Mechanism of Injury**  
<http://morphopedics.wikidot.com/lateral-ankle-sprain>

### Mechanism

Lateral ankle sprains are common among young active individuals and athletes whose “center of gravity is shifted over the lateral border of the weight bearing leg, causing the ankle to roll inward at a high velocity.”<sup>1</sup> Lateral ankle sprains occur during “excessive inversion and plantar flexion of the rear foot on the tibia in which the ATFL is most commonly torn.”<sup>2,3</sup> The ATFL, being the weakest lateral collateral ligament, is the first to be injured during talar inversion at “approximately 30 – 45 degrees within the ankle mortise (Figure 2). Other structures that may be injured during a lateral ankle sprain may include the peroneal tendons, lateral joint capsule, and the proprioceptive nerve endings found within these soft tissue structures. There are many symptoms typically seen with lateral ankle sprain such as “persistent ankle stiffness, swelling, and pain with delayed synovitis, tendinitis, and muscle weakness.”<sup>2</sup>

Ankle sprains are classified by the amount of damage that has occurred to the ligaments. “In a grade 1 sprain, there is stretching of the ligaments with little or no joint instability. A grade 1 ankle sprain usually entails microscopic tearing of the ATFL. Symptoms may include minimal swelling and point tenderness directly over the ATFL; however, there is no instability, and the [patient] can

ambulate with little or no pain. Grade 2 sprains involve microscopic tearing of a larger cross – sectional portion of the ATFL, which occurs with some tearing of ligamentous fibers and moderate instability of the joint. Pain and swelling are moderate to severe and often immobilization is required for several days. With a grade 3 sprain, there is total rupture of the ligament with gross instability of the joint. Pain and swelling is so debilitating that weight bearing is impossible for up to several weeks.”<sup>1,3</sup>

### Treatment

There are several ways to treat an ankle sprain, depending on the situation of the patient. Anatomically, the ligament goes through phases of healing, from an inflammatory phase that lasts a day to three days to a reparative phase of healing in which healthy cells replace damaged fibers and connective tissue. Finally the healing process ends at the remodeling phase. Here “the newly formed collagen fibers align themselves longitudinally, and cross-linkages form. By 3 weeks, as collagen maturation continues, the ligament may regain approximately 60% of its tensile strength. By 3 months, the ligament may regain its pre-injury strength.”<sup>1</sup> Healing begins immediately by the body; however, implementing a non-surgical approach can accelerate treatment. As described by Fong et al<sup>4</sup>, management could include various forms of braces, boards, and imagery such as ultrasounds and MRI’s. A semi-rigid ankle brace, an aircast ankle brace, allows for significant improvement in ankle joint function. This brace is “designed to fit against the medial and lateral malleoli of the ankle joint.”<sup>4</sup> They also believe that an elastic support bandage could be used to “improve single-leg-stance balance and might decrease the likelihood of future sprains.”<sup>4</sup> Fong et al believe that training on a wobble board in which the patient practices balancing on a rectangular or square platform with a single plane-rounded fulcrum underneath can better ones anteroposterior and mediolateral stability.<sup>3</sup> Another method mentioned by Chinn and Hertel<sup>3</sup> was with the help of a stationary bicycle, which can aid in dorsiflexion and plantar flexion motion in a controlled environment.”<sup>3</sup>

The initial purpose of treatment is to be able to control the swelling and the pain in order to increase the strength of exercises to further better the range of motion at the ankle. In order to do so, dorsiflexion and plantarflexion are the main ankle motions that are targeted initially by physical therapists. Once that motion has strengthened and “ligaments heal, inversion and

eversion strengthening should be added.”<sup>3</sup> In order to do so, ankle weights, resistance bands, and even hydrotherapy are considered viable options to treat in all planes. Once range of motion and strength are regained, functional activities are included. Functional rehabilitation exercises should begin with simple, uniplanar exercises; walking and jogging in a straight line. Once the athlete can perform these without a pain or a limp, hops, jumps, skips and change of direction can start to be added.”<sup>3</sup>

Treatment is determined in order to restore the patient’s complete range of motion and mechanical strength gradually and non-surgically, in order to protect the patient’s ligament from further injury.

### **Lisfranc’s Injury**

#### **Anatomy**

On September 30<sup>th</sup>, 2012, New York Jets football player Santonio Holmes suffered what was described as an injury to the Lisfranc joint. The Lisfranc joint divides the midfoot from the forefoot. The bony elements of the 3 metatarsals articulating with the cuneiforms, along with the fourth and fifth metatarsals articulating with the cuboid, provide most of the overall stability.<sup>6</sup> Ligaments are grouped according to anatomical placement, mainly dorsal, plantar, and interosseous. The strongest of these ligaments originates from the lateral side of the medial cuneiform and inserts on the medial side of the base of the second metatarsal. This ligament is known as Lisfranc’s ligament, an oblique interosseous ligament.<sup>6</sup>

#### **Mechanism**

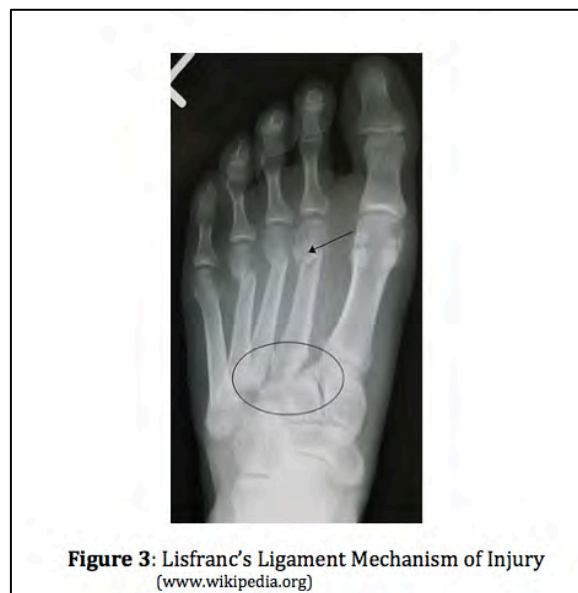A Lisfranc injury does not delineate a specific injury, but instead a spectrum of processes involving the tarsometatarsal joint complex. The Lisfranc joint promotes energy dissipation by allowing force to be transferred between the midfoot and the forefoot. Direct and indirect injuries can occur at this joint. Direct injuries occur in blunt force trauma to the foot and are clinically worse than indirect.<sup>7</sup> The more common injury with athletes is the indirect injury. As seen in football players, it occurs when one player falls onto the heel of another player while the foot is planted into the ground and in an equinus position.<sup>7</sup> Approximately 4% of professional football players sustain injuries to the Lisfranc joint each year.<sup>8</sup> These injuries also occur in gymnasts, soccer players and basketball players. These indirect injuries commonly involve failure of the weaker dorsometatarsal ligaments in tension

with subsequent dorsal metatarsal dislocation.<sup>8</sup>

The Lisfranc joint provides a stable axis for rotation due to the limited mobility of the joint, and allows for plantar flexion and dorsiflexion of the forefoot. The axis about which extension and plantar flexion occur, called the horizontal axis, and goes through the base of the second metatarsal.<sup>6</sup> Thus, with the lack of dorsal support and the immobility of the second metatarsal, placing the foot in extreme plantarflexion with an axial load can provide sufficient stress to cause dorsal displacement of the second metatarsal base.<sup>7</sup> Injuries can vary, from a simple injury that affects only a single joint to a complex injury that disrupts multiple different joints and includes multiple fractures (Figure 3). The severity of the injury depends upon the impact.

#### **Symptoms**

A key symptom indicative of a Lisfranc joint injury is bruising on the plantar surface of the foot.<sup>9</sup> Bruising on the dorsal aspect is also common. Included with bruising is pain and swelling on the dorsal portion of the foot.<sup>9</sup> Typically, the pain worsens with standing or walking, and may require crutches for mobilization.<sup>8</sup> Lisfranc injuries lead to degenerative arthritis, loss of arch and chronic instability, and pain at the midfoot-forefoot articulations.<sup>6</sup>



#### **Treatment**

If there are no fractures or dislocations in the joint and the ligaments are not completely torn, nonsurgical treatment may be all that is necessary for healing.<sup>9</sup> A nonsurgical treatment plan includes wearing a non-weight-bearing cast for 6 weeks.<sup>8</sup> This then progresses to weight bearing in a removable cast boot or an

orthotic. Surgery is recommended for all injuries with a fracture in the joints of the midfoot or with subluxation of the joints.<sup>6</sup> There are two types of surgery recommended for this injury. The first is the internal fixation procedure where the bones are positioned correctly and held in place with K-wire fixations or temporary screw fixation using closed or open reduction techniques.<sup>6</sup> If the injury is more severe and has damage that cannot be repaired, another procedure, fusion, may be recommended as the initial surgical procedure.<sup>6</sup> Fusion attaches the injured bones together in order to form one piece of bone, and is recommended in cases where internal fixation will not work.<sup>6</sup>

### **Turf Toe**

#### **Anatomy**

On December 3<sup>rd</sup>, 2012, Carolina Panthers football player Brandon LaFell suffered an injury that is commonly known as “turf toe.” Turf toe is an injury that is characterized with hyperextension of the first metatarsophalangeal joint with sprain and possible rupture of the plantar ligamentous complex.<sup>10</sup> The capsuloligamentous-sesamoid complex contributes most of the stability observed in the MTP joint.<sup>10</sup> This complex is made up of collateral ligaments, along with the plantar plate, flexor hallucis brevis, adductor hallucis, and abductor hallucis.

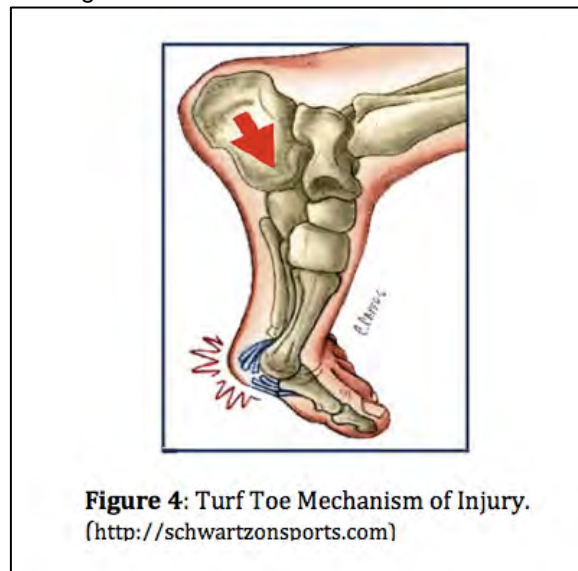
#### **Mechanism**

This injury typically occurs in combination of dorsiflexed toes and the foot in an equinus position with the heel raised, forefoot planted on the ground, and an axial load applied to the posterior heel.<sup>10</sup> (Figure 4) Usually with a hyperextension injury, the plantar portion of the ligament complex tears while the plantar plate becomes detached distal to the sesamoid bones.<sup>10</sup> Once the joint capsule is torn, unrestricted motion of the proximal phalanx results in severe compression of the articular surface of the metatarsal head.<sup>11</sup> This produces the potential for fracture or dislocation. The injury is classified in a grading scale: Grade I is micro-tearing of the capsuloligamentous complex, Grade II is partial tearing of the same complex, and Grade III is complete tearing of the capsuloligamentous complex.<sup>10</sup> The grading varies depending upon the severity of the injury and clinical evaluation needs to be done in order to determine severity of injury.

#### **Symptoms**

The risk factors for this injury are hard

playing surfaces, lack of ankle dorsiflexion, pre-existing restriction of the first MPJ motion, and wearing flexible, lighter shoes.<sup>11</sup> These patients present with swelling, ecchymosis, a misalignment of the structure of the hallux, weak plantarflexion strength, and pain on weight bearing and toe off.<sup>12</sup>



**Figure 4: Turf Toe Mechanism of Injury.**  
(<http://schwartzonsports.com>)

#### **Treatment**

Most cases of turf toe are treated conservatively. In the acute stages, treatment is centered on decreasing inflammation and promoting healing with rest, ice, compression, and elevation.<sup>10</sup> Nonsteroidal anti-inflammatory drugs (NSAIDs) may aid in minimizing pain and inflammation.<sup>10</sup> In higher grade sprains, crutches and a short leg cast with a toe spica in slight plantarflexion or a walker boot may be prescribed for the first week or more.<sup>10</sup>

### **Sand Toe**

#### **Mechanism**

One injury that is more commonly seen in sand sports such as volleyball occurs at the same joint as turf toe, but occurs via a different mechanism.<sup>13</sup> This injury, termed “sand toe,” is an injury that occurs during hyperflexion (Figure 5) of the first metatarsophalangeal joint.<sup>14</sup> This hyperflexion occurs with sprain and possible rupture of the dorsal capsule, along with injury to the extensor tendons.<sup>14</sup> This injury typically occurs when toes are in a plantarflexed position, and momentum of body weight continues over the joint, resulting in hyperflexion injury.<sup>13</sup>



**Figure 5: Sand Toe Mechanism of Injury.**  
(www.zimbio.com)

### Symptoms and Treatment

These injuries clinically present with weak dorsiflexion strength, pain on weight bearing and toe off, and swelling with ecchymosis.<sup>14</sup> This injury is usually self-limiting and, unlike turf toe, is not plagued with long-term morbidity. The most common form of this injury is a capsular sprain with minor tearing, and is manageable with stabilization by taping.<sup>14</sup> In addition, use of non-steroidal anti-inflammatories with rest, ice, compression, and elevation are recommended to expedite healing.

### Conclusion

Injuries are common when one is physically active, particularly in contact sports. Diagnosis of the most common ankle, Lisfranc, and hallux injuries requires knowledge of the mechanism of injury consistent with the appropriate physical findings. Knowledge of the most effective treatments can help speed the healing process. Knowing the most common ankle and foot injuries is important before participating in athletics in order to properly avoid injury. There are many lower extremity injuries that can occur when dealing with sports. The most common are highlighted here in order to provide knowledge of the mechanism and treatment options of high-yield injuries. Further research needs to be done in order to provide an entire spectrum of lower extremity injuries while participating in contact sports.

### Authors' Contribution

The authors, S.C. and T.M., equally contributed to the literature searches, reading of the literature material, and the design, the drafting, and the formatting of the manuscript. The symbol “†” denotes that both writers are considered primary authors due to the equal contribution.

### Statement of Competing interests

The authors, S.C. and T.M., declare no competing interests in regards to this research topic and systematic review.

### References

1. Dubin J., Comeau D., McClelland R., Dubin R., Ferrel E. "Lateral and Syndesmotic Ankle Sprain Injuries: A Narrative Literature Review". *Journal of Chiropractic Medicine*. 2011; 10, 204-219
2. Tre T., Handl M., Havlas V. "The Anterior Talo-Fibular Ligament Reconstruction in Surgical Treatment of Chronic Lateral Ankle Instability". *International Orthopaedics (SICOT)*. 2011; 34, 991-996.
3. Chinn L., Hertel J. "Rehabilitation of Ankle and Foot Injuries in Athletes". *Clin. Sports Med*. 2010; 29(1), 157-167.
4. Fong D., Chan YY., Mok KM., Yung P., Chan KM. "Understanding Acute Ankle Ligamentous Sprain Injury in Sports". *Sports Medicine, Arthroscopy, Rehabilitation, Therapy & Technology*. 2009; 1-14.
5. Haddix, B., Ellis, K., & Saylor-Pavkovich, E. "Lisfranc Fracture-Dislocation in a Female Soccer Athlete." *The International Journal of Sports Physical Therapy*. April 2012; 7(2), 219-225.
6. Rosenbaum, A., Dellenbaugh, S., DiPreta, J., & Uhl, R. "Subtle Injuries to the Lisfranc Joint." *Trauma Update*. November 2011; 14(11), 882-887.
7. Mantas J.P., Burks R.T. "Lisfranc Injuries in the Athlete." *Clin Sports Med*. 1994; 13(4), 719-730.
8. Nunley J.A., Vertullo C.J. "Classification, Investigation and Management of Midfoot Sprains: Lisfranc Injuries in the Athlete." *American Journal of Sports Medicine*. 2002; 30(6), 871-878.
9. Wilson D.W. "Injuries of the Tarso-Metatarsal Joints: Etiology, Classification and Results of Treatment." *The Bone and Joint Journal*. 1972; 54(4), 677-686.
10. McCormick J.J., Anderson R.B. "Turf Toe Anatomy, Diagnosis, and Treatment." *Sports Health: A Multidisciplinary Approach*. 2010; 2(6). 487-494
11. Mullen, J.E., O'Malley, M.J. "Sprains - Residual Instability of Subtalar, Lisfranc Joints, and Turf Toe." *Clinics in Sports Medicine*. 2004; 23(1), 97-121
12. Bowers K.D. Jr, Martin R.B. "Turf-Toe: A Shoe-Surface Related Football Injury." *Med Sci Sports*. 1976; 8(2), 81-83.
13. Vormittag, K., Calonje, R., Briner, W. "Foot and Ankle Injuries in the Barefoot Sports." *Current Sports Medicine Reports*. 2009; 8(5), 262.
14. Frey, C., Andersen, G.D., Feder, K.S. "Plantarflexion Injury to the Metatarsophalangeal Joint (Sand Toe)." *Foot & Ankle International*. 1996; 17(9), 576-581

# Methylglyoxal and osteoprotegerin down-regulation in patients with uncontrolled diabetes mellitus: A possible microvascular therapeutic approach to diminish lower extremity amputations

J. Adrian Wright, AM and Virginia Parks, BS

## Abstract

### Introduction:

When uncontrolled, the pathogenesis of DM almost always results in poor tissue perfusion as a result of microvascular complications. Recent research has elucidated additional mechanisms underlying the connection between microvascular complications and uncontrolled DM. Amongst such mechanisms is the aberrant regulation of the body's immune response. Analysis of these mechanisms could possibly yield alternative prevention methods, namely immunotherapy, to prevent microvascular complications and thus prevent amputations of the lower extremities that have been known to contribute to morbidity, and eventually, mortality.

### Study Design:

Qualitative Systematic Review of the Literature

### Methods:

A Pubmed advanced literature search was performed with the inclusionary terms "TNF- $\alpha$  AND peripheral vascular disease AND DM." The inclusionary criteria of TNF- $\alpha$ , DM, microvascular complications, peripheral vascular disease, poor tissue perfusion, and cytokine involvement were used to determine relevancy. An additional search was performed in the New England Journal of Medicine following the same criteria. Only articles published from 1998-current were utilized in the meta-analysis.

### Results:

Microvascular complications were found to be initiated by components of the innate immune response, namely methylglyoxal (MG) and osteoprotegerin (OPG), which contribute to increased duration of pro-inflammatory cytokines, such as TNF- $\alpha$ , leading to myointimal hyperplasia (MH). MH inevitably leads to stasis and poor tissue perfusion distal to the hyperplastic events.

### Conclusions:

Targeting the regulation of MG and OPG could alleviate the exacerbating inflammatory effects of proinflammatory cytokines such as TNF- $\alpha$ . Such targeted therapies could diminish the progression of myointimal hyperplasia, found to be one of many etiologies leading to ischemia in the lower extremities and consequential necrosis.

**Key Words:** diabetes, TNF- $\alpha$  AND diabetes

**Level of Evidence:** 4

## Introduction

Diabetes mellitus (DM) and cardiovascular disease (CVD) are the two leading conditions resulting in poor health and death amongst Americans.<sup>1</sup> The link between these two deleterious chronic diseases has been assessed by numerous studies suggesting a strong association between poorly controlled DM and the development of microvascular complications.<sup>2,3</sup> Regardless of the point at which the cardiovascular anomaly develops, the presence of reduced vascular perfusion of the lower extremities is inevitable.<sup>4,5,6,7</sup> The association between cardiovascular complications and the progression of uncontrolled DM has been marked by these

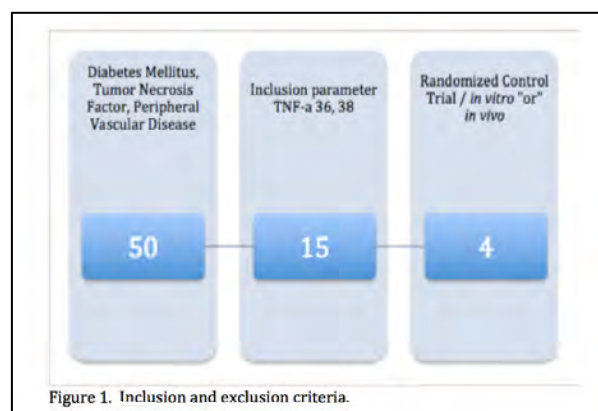
distal perfusion insufficiencies for years in the realm of clinical practice. Unfortunately, such microvascular complications could result in painful situations for the patient as a result of poor tissue perfusion, with the pain only subsiding as a result of loss of sensation from peripheral neuropathy.<sup>8</sup> Naturally, such conditions give rise to the increased risk of infection, necrosis, and even gangrene, currently yielding to inevitable amputation.<sup>9,10,11</sup>

Amputations, having been the solution for centuries for severe and irreconcilable states of tissue damage, only sustain the patient in a morbid condition from loss of ambulation. Such states eventually lead to physical decline and death with a 5-year survival rate of only 40-50%

following a major amputation.<sup>12,13</sup> For this reason, it has been the trend of modern medicine to avoid amputations unless absolutely necessary. For quite some time it has been known that loss of tissue perfusion was the culprit for necrosis within the distal parts of the extremities of the body.<sup>6,14</sup> However, current research endeavors have narrowed their focus to the underlying mechanisms contributing to loss of perfusion in the lower extremities as a result of severe uncontrolled DM, especially in patients with end stage renal disease and microvascular complications.<sup>6,15</sup> Recent discoveries in the realm of innate immunology, and hematopathology have elucidated numerous areas of further exploration that could provide better treatment options.<sup>16,17,18</sup> The purpose of this study, therefore, was to assess these novel findings that could contribute to a better prognosis for DM patients with microvascular complications by possibly diminishing the need for amputations in the lower extremity.

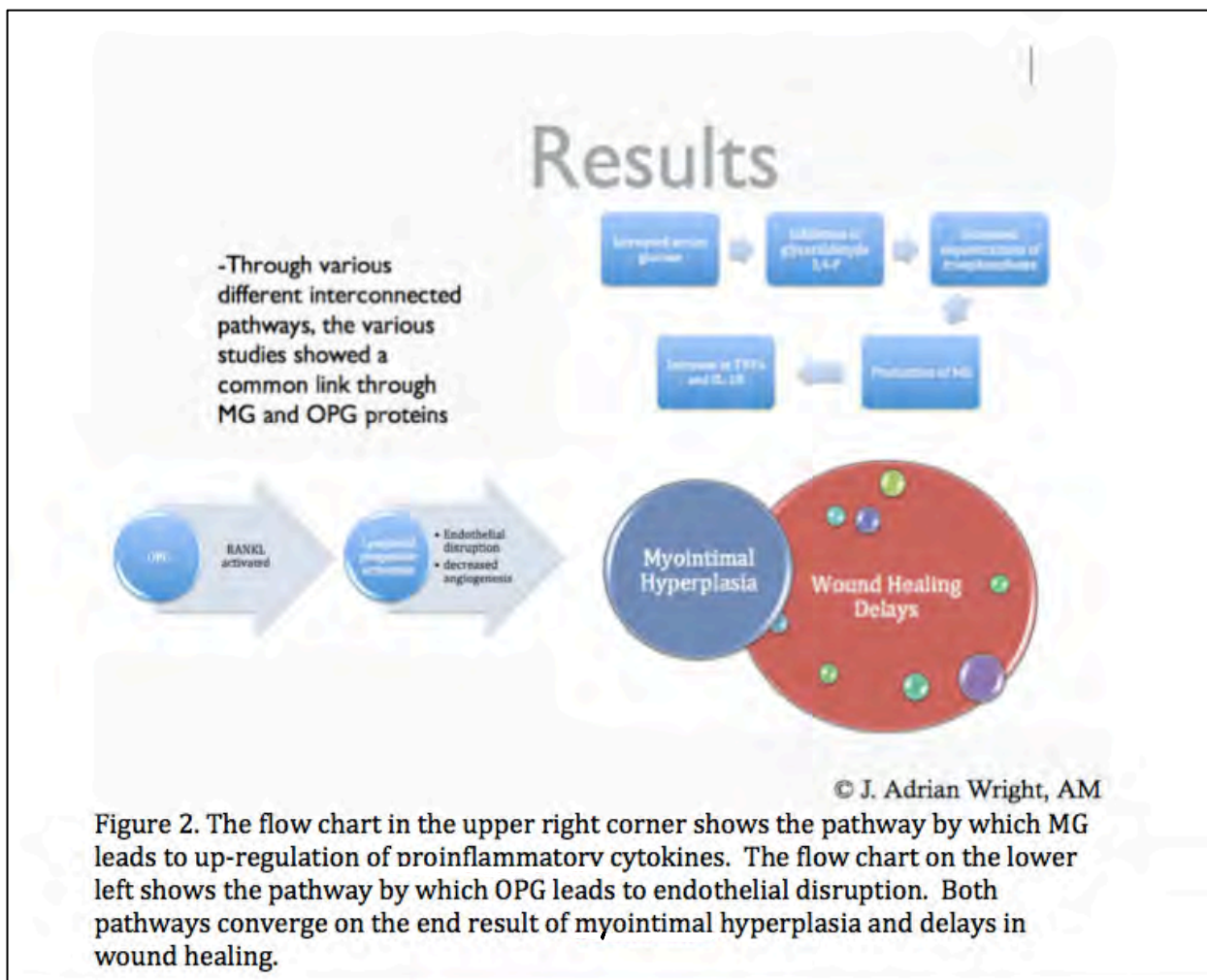
## Methods

Utilizing the MeSH advanced search building tool within the PubMed interface, the Boolean operator “and” was employed to include terms “TNF- $\alpha$ ”, “peripheral vascular disease”, and “diabetes” in the search fields. The “all fields” option was selected for each of the three corresponding terms. Particular attention was given to the search specificity of “TNF- $\alpha$ ” by utilizing the “show index list” option and selecting “tnf alpha 36 68”. A search of all databases yielded 50 articles that were assessed for content, validity, and appropriateness given the inclusion criterion of this study. Of the 50 articles, four articles were selected (Figure 1). An additional search of the New England Journal of Medicine for diabetes and peripheral vascular disease yielded 208 articles, which were narrowed down to 116 articles by specialty. Of the 116, 3 articles were chosen for background information in this study and were not included in the qualitative analysis, per inclusion principle guidelines.



## Results

Berlanga et al. (2005) performed a study on the prolonged effects of methylglyoxal (MG), a known effector of aberrant GLUT1 transporter disruption in diabetes, on male rats to assess the appearance of microvascular complications and delayed wound healing.<sup>19</sup> To accomplish this, MG was diluted in sterile water, and injected. The solution was carefully stored out of light to protect from any form of protein denaturation. All injections were given intraperitoneally over the course of five consecutive days for seven consecutive weeks with the initial dose being 50 mg per kilogram of body weight (mg/kg) for the first two weeks and the subsequent doses being 60 mg/kg for weeks 3 and 4 and finally 75 mg/kg for the last three weeks. This titration was employed based upon previous assessments yielding an induction of diabetic-like initiation of renal changes after five months of exposure. Serum glucose, cholesterol (total), triacylglycerols, and fructosamine concentrations were assessed to assure experimental conditions had been reached. At the sixth week, twelve rats under anesthesia received a full thickness wound (controlled and measured for consistency).<sup>19</sup> Four days after the wound was given, the granulation tissue was assessed for the presence and volume of polymorphonuclear cells, macrophages and presence of angiogenesis effects. Vasoregulatory effects were measured by administration of nitroglycerine, and tissue samples were taken for immunohistochemical assessment with anti-CTGF, anti-TGF- $\beta$ , PCNA, AGE, RAGE, TNF- $\alpha$ , and IL-1 $\beta$ . All samples were compared with human diabetes tissue samples. When cross-referencing the tissue samples from the control and experimental groups, the MG showed an initial immediate increase in body weight and an aged cutaneous phenotype revealed by thinner skin with numerous wrinkles.<sup>19</sup> Rats exposed to MG showed an inability to respond to



vasodilatory signals, impairment of wound healing, and the presence of pro-inflammatory cytokines, specifically TNF- $\alpha$  and IL-1 $\beta$ , in granulation tissue cells. Histochemical analysis of the glomerular basement membrane with congo red and PAS staining revealed the presence of amyloid material indicative of renal damage in MG exposed rats.<sup>19</sup>

Danielsson et al. (2005) endeavored to study the differences in peripheral vascular disease (PAD) in patients with diabetes and in patients without diabetes to assess if a disparity existed in the manifestation of PAD between the two groups using the inflammatory marker IL-6 polymorphism as a determinant.<sup>20</sup> To do this, five groups of twenty patients and one control group were enlisted in the study to give fasting blood samples in the morning. Hemoglobin, high sensitive CRP, cholesterol, low-density lipoprotein, high-density lipoprotein, triglycerides, glycated hemoglobin, and creatinine were assessed (by routine blood analysis) along with cell activation (by flow cytometry).<sup>20</sup> Cytokine analysis was specifically performed on serum concentrations of IL-6, IL-8,

and TNF- $\alpha$  by automated immunoassay. Analysis of IL-6 gene promoter polymorphisms was assessed by nested polymerase chain reaction. The routine blood tests revealed a statistically significant difference between the experimental and control groups with increased levels of hemoglobin ( $p < 0.001$ ), hsCRP ( $p < 0.001$ ), creatinine ( $p = 0.02$ ), triglycerides ( $p = 0.02$ ), and glycated hemoglobin ( $p < 0.001$ ).<sup>20</sup> Significant differences were also seen in the levels of cytokine production from cell activation: IL-6 (0.005) and TNF- $\alpha$  ( $< 0.001$ ), indicating an increased immune response in the experimental group.

The work of Sterpetti et al. (2008) focused on the correlation between the progression and regression of myointimal hyperplasia (MH) as a result of cytokine production in vein grafts, specifically addressing the effects on coronary and lower extremity circulation.<sup>21</sup> In this study, 172 male rats were given an arterial vein graft (AVG) or a reimplanted vein graft (RVG). Grafts were removed four (AVG) and two (RVG) weeks later, respectively. The grafts were opened

longitudinally, and washed to collect samples for a cytokine production assay where IL-1, TGF- $\beta_1$ , and TNF- $\alpha$  were assessed. Structural changes to the vein grafts showed marked rigidity as compared to the controls.<sup>21</sup> Platelet derived growth factor (PDGF), and IL-1 showed statistically significant increases between the control and experimental groups both with a p-value of less than 0.01. TNF- $\alpha$  (p<0.001) and TGF- $\beta_1$  (p<0.001) were also statistically significant from the control groups. Histochemical analysis revealed positive immunofluorescence staining for factor VIII-related antigen.

Secchiero et al. (2006) focused on the binding of serum osteoprotegerin (OPG) to receptor activator of nuclear factor  $\kappa$ B ligand (RANKL) in order to understand whether the binding of elevated OPG to RANKL occurs in a late stage or in an early stage of DM, and to therefore elucidate another initiating mechanism of lymphoid progenitor cell damage to the peripheral and central cardiovascular system in patients with diabetes mellitus.<sup>22</sup> To accomplish this task, human subjects, animal subjects, and cell cultures were employed to sustain the highest level of evidence with two *in vivo* assessments and one *in vitro* assessment. Human subjects: 88 patients were assigned to the experimental group (with diabetes) and 41 patients were assigned to a control group (no metabolic disease). Serum samples were attained from both groups. These serum samples were assessed for concentration of OPG, and RANKL levels via sandwich-type enzyme-linked immunosorbent assay (ELISA) individually specific for both bound and free levels of OPG yielding determinate information as to the state of OPG. Additionally, sixteen mice that were all apoE-null were divided into two groups of eight. One group received intraperitoneal injections of streptozotocin five times daily, rendering them diabetic (experimental group), while the other group received only citrate buffer alone (control group). After three months, the animals were anesthetized by an intraperitoneal injection of pentobarbital sodium, and submitted for histological assessment of the magnitude of atherosclerotic lesions in both experimental and control groups.<sup>22</sup> Cell cultures were also prepared from human umbilical vein endothelial cells to assess any differences between *in vitro* and *in vivo* expression. Supernatants from cell cultures were collected and assessed. The serum levels were found to be statistically higher (p<0.05) in diabetic patients when compared to

patients lacking a metabolic syndrome. Additionally, the serum levels of OPG were also found to be statistically higher in diabetic mice. The *in vitro* studies revealed that inflammatory cytokines, not high glucose levels, were responsible for the release of OPG by endothelial cells, and showed that OPG inhibits endothelial cell survival and angiogenesis by blocking intracellular signaling pathways induced by RANKL.<sup>22</sup>

## Discussion

From all of these studies, one can see an important and obvious role of the innate immune response in microvascular complications in DM patients that is directly linked to the development of poor vascular perfusion and poor wound healing in the lower extremities. From the work of Berlanga et al, we see that methylglyoxal (MG) is produced by an increased sequestration of triphosphates that arises from inhibition of glyceraldehyde-3,4-phosphate. When MG is released from the vascular endothelium, it results in microvascular complications that are linked to the biochemical dysfunction of glucose transporter GLUT1. Additionally, MG contributes to the retardation of wound healing by increasing the duration of pro-inflammatory cytokines, namely TNF- $\alpha$  and IL-1 $\beta$ . Further evidence of innate immune involvement in the pathogenesis of microvascular complications leading to poor wound healing and tissue perfusion was displayed by Danielsson and colleagues where the role of proinflammatory cytokines, specifically IL-6, TNF- $\alpha$ , significantly increased in patients with PAD and DM. This increase, although strongly supportive, was not definitive in the association between the two parameters of poor tissue perfusion and wound healing versus aberrant inflammatory control of the innate immune system. Further analysis from the work of Sterpetti and colleagues strengthened this association by demonstrating that modifications of cytokines in response to hemodynamic stimuli resulted in diminished stenotic changes in vein bypass grafts. This key observation came by discovering the direct role of cytokine production in myointimal hyperplasia.

The work of Berlanga et al., Danielsson et al., and Sterpetti et al. addressed the roles of aberrant cytokine production and/or regulation of various parts of vasculature healing or functioning, resulting in the conditions that we know as peripheral vascular disease (PVD). More specifically, these complications result in poor tissue perfusion and delayed wound



healing in uncontrolled states of diabetes. Secchiero et al, took a different approach to establish a direct link between DM and vascular complications, expounding on the underlying mechanisms. The work of Berlanga et al., Danielsson et al., and Sterpetti et al. displayed an increase in the TNF family of cytokines and the effects of these increased levels. Secchiero et al., however, addressed the RANK ligand and its receptor, one of the main effectors in the production of TNF family cytokines, and the source of TNF cytokine regulation. By addressing osteoprotegerin (OPG) levels released from endothelial cells, a known ligand of the RANK receptor, they were able to establish a mechanism for initiating factors of the immune response in vascular damage. RANK protein expression is normally distributed in endothelial cells, dendritic cells, CD4, and CD8 T-cells, however the pathways that it activates are respectively sophisticated. The RANK protein receptor in endothelial cells supports endothelial cell survival and angiogenesis, both notably important in wound healing (shown to be disrupted by TNF- $\alpha$  and IL- $\beta$  by Berlanga et al). Additionally, the RANK protein in dendritic cells, CD4 and CD8 T-cells holds a role in the immune response indirectly up-regulating pro-inflammatory cytokine production. Therefore the discovery of OPG interactions with the RANK receptor by Secchiero and colleagues strongly supports a direct role of uncontrolled glucose states as seen in diabetics with immune response up-regulation and diminished vascular regeneration. This suggests a direct link between the aberrant modifications of the immune response by diabetes to the development and exacerbation of vascular complications.

## Conclusions

DM and CVD are the two leading conditions resulting in poor health, and death amongst Americans.<sup>1</sup> When uncontrolled, the aberrant levels of glucose seen in diabetes can stimulate OPG release that contributes to delayed wound healing and activation of immune responses that inevitably lead to the up-regulation of pro-inflammatory cascades mostly responsible for vascular noncompliance as seen in myointimal hyperplasia. These levels of vascular noncompliance contribute to peripheral vascular disease, especially in the lower extremities, leading to states of poor tissue perfusion and necrosis. If untreated, such states can lead to the necessity for amputation. Amputations within the lower extremities, regardless of the

extent, hold some bearing on an individual's ability to ambulate. These effects lead to morbid states that may possibly result in mortality. Recent studies have suggested that, even in advanced stages of poorly controlled diabetes, immunosuppressive therapy may yield plausible and even lifesaving effects by inhibiting one or more of the intrinsic pathways previously mentioned. It is noted that patients with DM already have states of diminished immune function.<sup>11</sup> The target of immunosuppression described in this article is restricted to pro-inflammatory cytokine production and should not be confused with a diminished immune response in other sectors, such as T-cell mediated response. Further research in the realm of immunoregulation and immunotherapy could yield dramatic results capable of revolutionary changes in the management, treatment, and prognosis of individuals with DM prior to, or with, vascular complications.

## Authors' Contributions

JW developed the design of the study, linking the surrogate proinflammatory cytokine pathways. VP assessed articles from the literature for content and validity.

## Statement of Competing Interests

The authors declare that they have no competing interests.

## References

- Centers for Disease Control and Prevention. Ten great public health achievements--United States, 1900-1999. 1999 MMWR Morb Mortal Wkly Rep. 48:241-243.
- Duckworth W, Abraira C, et al. Glucose Control and Vascular Complications in Veterans with Type 2 Diabetes. New England Journal of Medicine. 2009; 360: 129-139.
- UK Prospective Diabetes Study (UKPDS) Group. Intensive blood-glucose control with sulphonylureas or insulin compared with conventional treatment and risk of complications in patients with type 2 diabetes (UKPDS 33). Lancet. 1998;352: 837-853.
- Bazari H, Jaff M, et al. Case 7-2007: A 59-year-old woman with diabetic renal disease and nonhealing skin ulcers. New England Journal of Medicine. 2007; 356: 1049-1057.
- Fontaine VR, Kim M, Kieny R. Surgical treatment for peripheral vascular disease. Helvetica Chirurgica Acta 1954; 6:499-533.
- Kant KS, Glueck HI, Coots MC, Tonne VA, Brubaker R, Penn I. Protein S deficiency and skin necrosis associated with continuous ambulatory peritoneal dialysis. Am J Kidney Dis 1992;19:264-71.
- Twine CP, McLain AD. Graft type for femoro-popliteal bypass surgery. Cochrane Database of Systematic Reviews 2010, Issue 5. [DOI: 10.1002/14651858.CD001487.pub2]
- Brand FN, Abbott RD, Kannel WB. Diabetes, intermittent claudication, and risk of cardiovascular events. Diabetes. 1989;38:504-509.
- Langan SM, Powell FC. Vegetative pyoderma

gangrenosum: a report of two new cases and a review of the literature. *Int J Dermatol* 2005; 44:623-629.

11. Mehta RL, Scott G, Sloand JA, Francis CW. Skin necrosis associated with acquired protein C deficiency in patients with renal failure and calciphylaxis. *Am J Med* 1990; 88:252-257.
12. Kadukammakal J, Yau S, Urbas W. Assessment of Partial First-Ray Resections and Their Tendency to Progress to Transmetatarsal Amputations: A Retrospective Study. *JAPMA* 2012; 102:412-416.
13. Game, F. (2012), Choosing life or limb. Improving survival in the multi-complex diabetic foot patient. *Diabetes Metab. Res. Rev*, 28: 97–100.
14. Bakker K, Apelqvist J, Schaper NC. Practical guidelines on the management and prevention of the diabetic foot 2011. *Diabetes Metabolism Research and Reviews*. 2012;28(Suppl 1):225–231.
15. Creager MA, Kaufman JA, Conte MS. Acute Limb Ischemia. *New England Journal of Medicine*. 2012; 366:2198-2206.
16. Reda A, Hurton S, Embil JM, et al. Effect of a preventive foot care program on lower extremity complication in diabetic patients with end-stage renal disease. *Foot Ankle Surgery*. 2012; 18: 283-286.
17. Elsasser A, Mollmann H, Nef HM, Hamm CW. How to revascularize patients with diabetes mellitus: bypass or stents and drugs? *Clin Res Cardiol*. 2006; 95: 195-203.
18. Geraghty A, Welch K. Antithrombotic agents for preventing thrombosis after infrainguinal arterial bypass surgery. *Cochrane Database of Systematic Reviews* 2011, Issue 6. Art. No: CD000536
19. Elsasser A, Mollmann H, Nef HM, Hamm CW. How to revascularize patients with diabetes mellitus: bypass or stents and drugs? *Clin Res Cardiol*. 2006; 95: 195-203.
20. Berlanga J, Cibrian D, et al. Methylglyoxal administration induces diabetes-like microvascular changes and perturbs the healing process of cutaneous wounds. *Clinical Science*. 2005; 109: 83-95.
21. Danielsson P, Truedsson L, et al. Inflammatory markers and IL-6 polymorphisms in peripheral arterial disease with and without diabetes mellitus. *Vascular Medicine*. 2005; 10: 191-198.
22. Sterpetti AV, Cucina A, Lepidi S, et al. Formation of myointimal hyperplasia and cytokine production in experimental vein grafts. *Surgery*. 1998; 123: 461-469.
23. Secchiero P, Corallini F, et al. Characterizes the early onset of diabetes mellitus and may contribute to endothelial cell dysfunction. *The American Journal of Pathology*. 2006; 169: 2236-2244.

# Relapsing polychondritis with pedal manifestations: a case report

Danielle Mercado, BS, and Chelsea Viola, BS

## Abstract

In this case we present a patient with inflammation of the ears, nose and joints complete with redness, local tenderness and swelling. The initial diagnosis was cellulitis, but the symptoms did not subside upon administration of antibiotics. As a result, the differential diagnosis had to be changed to include relapsing polychondritis. Upon administration of steroids, the patient's symptoms started to improve. When methotrexate therapy was included into the treatment regimen, symptoms almost completely subsided. Although rare, relapsing polychondritis must be included in the differential diagnosis upon presentation with clinical findings similar to those found in this patient. The purpose of this case study is to raise awareness on the clinical presentation of relapsing polychondritis, in hopes of keeping these patients from being subject to multiple rounds of unnecessary antibiotics.

**Key Words:** Polychondritis

**Level of Evidence:** 4

## Introduction

Relapsing Polychondritis (RP) is a rare, episodic and progressive inflammatory disease of connective tissue and cartilaginous structures of the auricular area, nose, laryngotrachea and peripheral joints.<sup>1</sup> RP also affects the proteoglycan-rich tissues, such as heart, blood vessels, eyes, inner ears and kidneys. RP was first described as polychondropathia in 1923 by Jaksch-Wartenhorst.<sup>2</sup> In 1960, Pearson, et al introduced the term "relapsing polychondritis".<sup>3</sup> RP is also known as chondromalacia, diffuse perichondritis, chronic atrophic polychondritis and diffuse chondrolysis.<sup>1</sup> RP is relatively rare, therefore there are only about 600 cases reported worldwide.<sup>1</sup> The average age of diagnosis is 44 to 51 years, but symptoms can appear at any age. The male to female ratio is equal.

## Case Report

A 76-year-old retired psychology professor first experienced redness and swelling with some pruritis in his left ear in March of 2010. This complaint was taken to his primary care doctor, who placed him on amoxicillin and clindamycin for twelve days. There was some initial improvement; however, the symptoms recurred three days after finishing the course of antibiotics. At this time, the patient consulted his ENT, who had followed him as a patient since 2004 for hearing loss. During the initial visit, this ENT prescribed ciprofloxacin, by mouth and

topical; however, this treatment did not relieve symptoms and the patient was then admitted to Lenox Hill Hospital for four days and was seen by Infectious Disease. Zyvox was prescribed and the patient remained on antibiotics for the next two months.

In May, despite antibiotic treatment, the patient began to experience swelling and redness now in his right ear. At this point in time, the patient sought treatment from Mt. Sinai Hospital, and was seen by Ear, Nose, and Throat/Otolaryngology. Along with the ongoing bilateral ear pain, he noted occasional "laryngitis and hoarseness" since March. In addition, the patient had a longstanding saddle deformity of his nose. After a consultation with Rheumatology, the patient was started on prednisone.

The first visit with Rheumatology took place on June 23<sup>rd</sup>, 2010 for an evaluation and consultation with possible diagnosis of relapsing polychondritis. At the time of the consultation, the patient was not experiencing any joint pain. There was also no family history of a known connective tissue disease or of relapsing polychondritis.

The physical examination revealed the following abnormalities:

1. Chondritis was noted to both external auricles. The external auricular cartilage showed signs of inflammation, including swelling, redness, and pain.
2. Deformation of the bridge of the nose, consistent with a saddle deformity. Tenderness was elicited upon palpation but no redness was present.
3. Bilateral crural +1 pitting edema with varicose veins was present.

Laboratory findings revealed:

1. Increased inflammatory markers: ESR – 120, C-reactive protein – 45.18, IgG – 2193, IgA – 1148, IgM – 112.
2. Rheumatoid factor – negative.

Radiographic imaging was performed:

1. CT showed no external ear abnormalities.
2. Upon bone scan, degenerative disease of the right knee and tarsal area of the left foot was noted.
3. Chest/neck CT showed tracheobronchial thickening with calcified lymph nodes consistent with granulomatous disease, minimal ear calcification and a 0.8cm lesion in the right parotid gland. Upon needle aspiration this was found to be consistent with a Warthin's tumor.
4. Chest CT also showed calcified mediastinal and hilar nodes with bilateral calcified pulmonary nodules consistent with prior granulomatous disease.

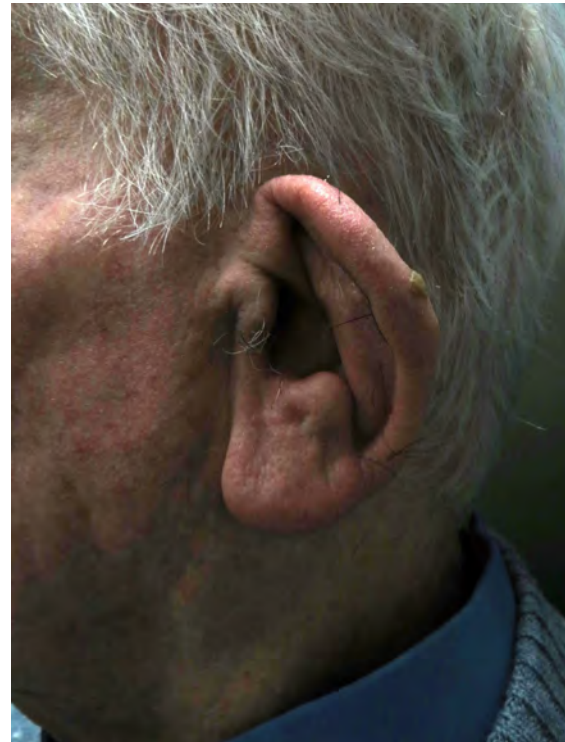Upon follow-up in 2011, the patient began to experience bilateral knee pain and swelling. Concurrent with the knee swelling, "sharp pains" involving the great and second toes, with the right being more painful than the left, became a complaint. In regards to the patient's bilateral forefoot pain, new physical findings were noted via treatment at the Foot Center of New York:

1. Hyperkeratotic lesions under plantar metatarsal heads 1-5 on the right foot and plantar medial first metatarsal on the left foot.
2. Lesser digit contractures including "claw toes" digits 2-5 on the right foot.

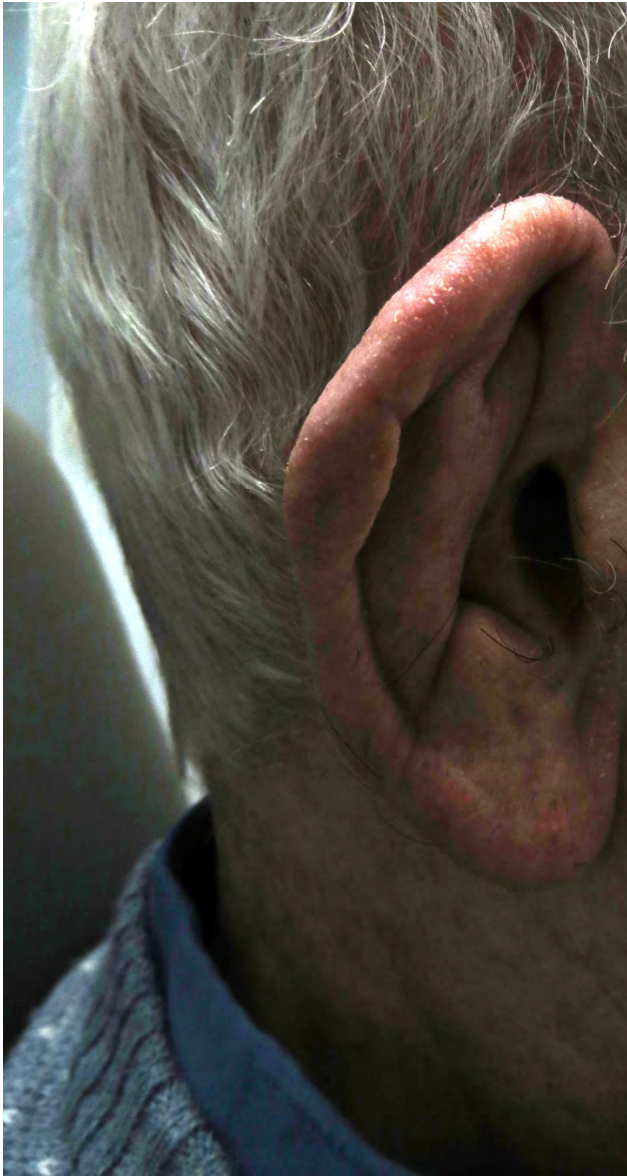3. Swelling and tenderness to bilateral first metatarsophalangeal joint, right greater than left.

With a new chief complaint of joint pain, magnetic resonance imaging was performed and revealed the following:

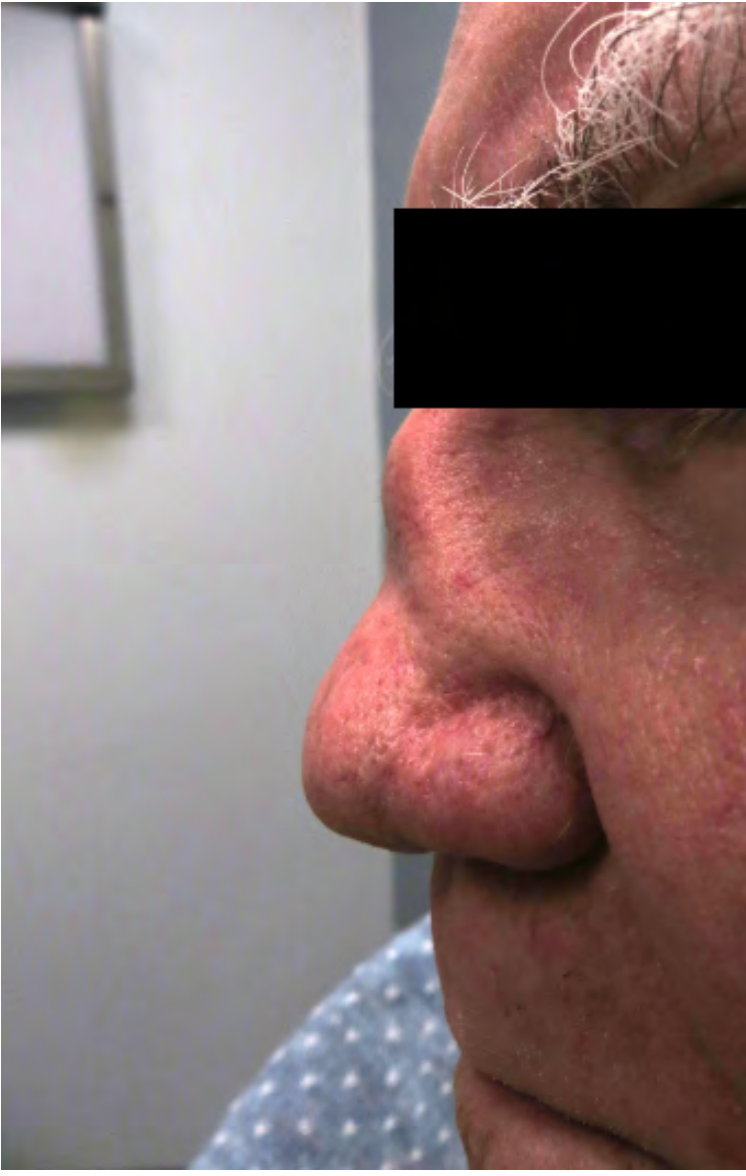1. Bilateral MR images were ordered for the knees and ankles. The left knee revealed a tear of the medial meniscus, moderate degenerative change medial meniscus, and a small effusion. The right knee revealed degenerative tearing of the medial meniscus, generalized mild to moderate chondromalacia, marrow changes in the distal femur, proximal tibia and patella, with a mild sprain of the anterior cruciate ligament.
2. The MR images of the ankles revealed multiple midfoot erosions, including plantar cuboid erosions "consistent with relapsing polychondritis."



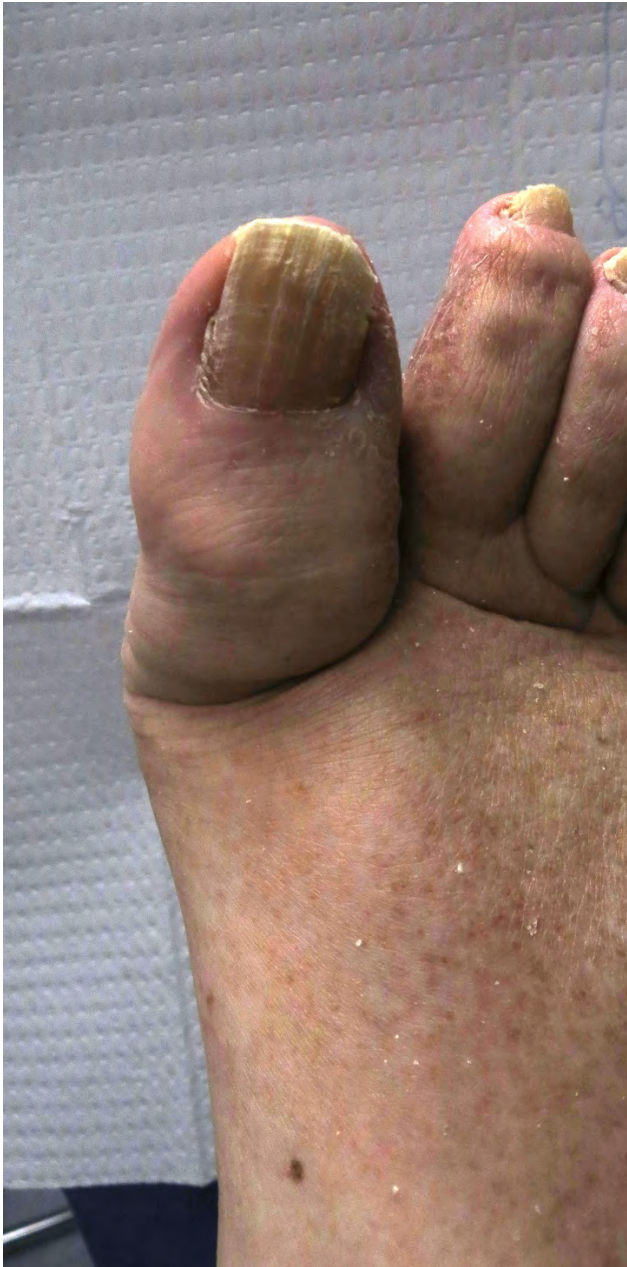*Figure 1: Left external auricle. Deformity of external auricle with residual edema consistent with chondritis.*



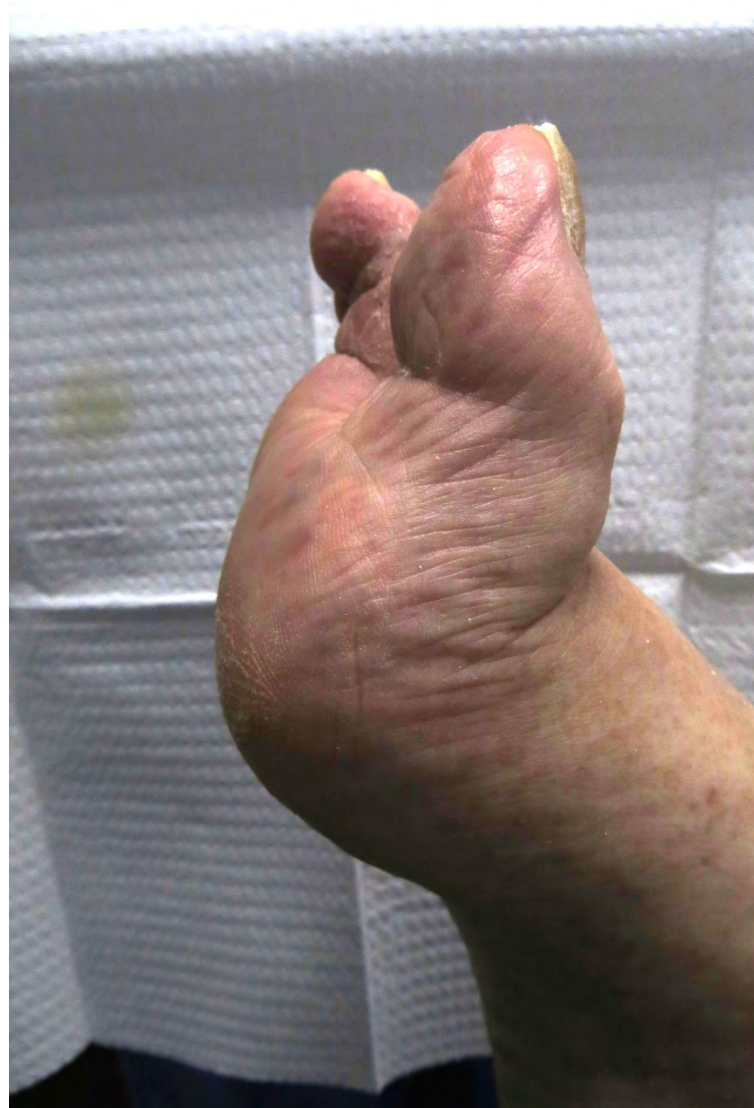*Figure 2: Right external auricle. Deformity of external auricle with residual edema consistent with chondritis.*



*Figure 3: Sagittal view of nose. Saddle deformity of bridge.*



*Figure 4: Dorsal aspect of right foot at rest. Flexion contractures of digits on right foot with sausage appearance deformity. Mild hallux abductovalgus deformity. Nails are dystrophic.*



*Figure 5: Medial aspect of right foot at rest. Right foot has a rigid cavus deformity with an anterior equinus. Flexion contractures of the lesser digits visible. Plantarflexed first metatarsal and flexion contracture of hallux at the proximal interphalangeal joint. Increase in soft tissue inflammation visible.*

Overall, the patient had typical features of relapsing polychondritis, which manifested as auricular chondritis. This was initially diagnosed as cellulitis, but since has been responsive to steroid therapy. Prior to diagnosis, the patient did have a nasal deformity and nasal bridge tenderness; however, nasal chondritis was not established. Even though he reported hoarseness, tracheal involvement and chondritis were not established. Throughout the course of the disease, he did develop arthropathy involving his knees, fingers, ankles, and forefoot, specifically the first metatarsophalangeal joints.

The patient was initially treated with prednisone, but there was some concern regarding his diabetes. At that time, there was discussion of treatment with Humira, but this option was abandoned due to CT findings of granulomatous disease and a history of DVT that required anticoagulation therapy. Methotrexate was considered as a treatment option in 2011 which would allow for tapering off prednisone. Within a month of treatment with methotrexate, the patient reported alleviation of pain and swelling. Palliative care including debridement of hyperkeratotic lesions, and custom shoe modification, have helped to relieve the patient of his forefoot pain.

## Discussion

The etiology of RP is unknown, but it is believed that the pathogenesis is an immunologic reaction to type II collagen, which is present in cartilage and the sclera of the eye.<sup>4</sup> Patients suffering from RP have presented with immune reactions to type II collagen by lymphocyte transformation and macrophage migration inhibition. Although there is not much evidence to determine pathogenesis of RP, the formation of antibodies to type II collagen may be a preliminary diagnostic factor of RP.<sup>4</sup> Disease activity is also assessed by an increase of acute phase reactants such as C-reactive protein (CRP) during the initial phase of RP.

### *Clinical Manifestations*

1. Auricular chondritis and vestibular dysfunction: The patient presents with red, swollen and painful ears.<sup>3</sup> The patients' ears may be inflamed for days to months. The cartilaginous structure of the ear lobe and pinna may droop. Patient also presents with symptoms of nausea, vomiting, and dizziness. The patient in this case study presented

- primarily with the initial signs of auricular chondritis and vestibular dysfunction.
2. Nasal chondritis: The patient may present with sudden, painful nasal chondritis. Nasal inflammation may destroy the cartilage, forming a saddle nose deformity with a flat nasal tip.<sup>1</sup> The patient in this case study currently suffers from nasal chondritis.
3. Laryngotracheal disease: The patient may present with hoarseness, difficulty breathing, wheezing, and pain over the thyroid cartilage.<sup>3</sup> The patient's symptoms may progress to complete aphonia or death secondary to pulmonary infections. The patient in this case study complained of laryngotracheal discomfort and hoarseness several months following his initial signs of auricular chondritis.
4. Primary Relapsing Polychondritis arthropathy (Arthritis): This is typically nonerosive but can affect all synovial joints.<sup>4</sup> The most commonly affected joints are metacarpophalangeal, proximal interphalangeal, and knee joints. Patient's condition may also involve erosive rheumatoid polyarthritis, nonerosive lupus polyarthritis, and spondyloarthropathy.<sup>1</sup> However, arthritis is the initial presenting symptom in a third of patients with RP. Arthritis typically presents asymmetrically, migratory oligoarthritis that lasts for weeks to months, rheumatoid factor negative and nonerosive. The patient in this case study was diagnosed with degenerative disease of the right knee and tarsal area of the left foot.
5. Renal disease: Patients rarely present with renal disease but it is fatal. Patients presenting with renal disease typically have necrotizing glomerulonephritis, glomerulosclerosis, IgA nephropathy and tubulointerstitial nephritis.<sup>1</sup>
6. Cardiovascular disease: Patients presenting with RP may also present with a broad variation of cardiovascular disorders such as cutaneous leukocytoclastic vasculitis, large-vessel vasculitis, aneurysms, and valvular heart disease
7. Dermatologic disorders: Patients presenting with RP may also present with a broad variety of dermatological disorders such as aphthosis, nodules, and purpura.<sup>1</sup> However, these

dermatological disorders are nonspecific for RP.

8. Neurologic abnormalities: Patients who present with RP may also present with headaches, encephalopathy, seizures, hemiplegia, and cerebral aneurysms.<sup>1</sup> However, these neurological disorders are nonspecific for RP.

#### *Treatment*

Currently, there is not a standard regimen for treating Relapsing Polychondritis because it is a rare disease. However, several drugs are prescribed to treat symptoms of the disease. Nonsteroidal anti-inflammatory drugs are prescribed for inflammation of joints and inflammation of the nasal area.<sup>5</sup> Long-term use of steroids such as methotrexate or azathioprine are indicated for chronic inflammation.<sup>5</sup> In addition, systemic corticosteroids are typically prescribed for acute exacerbations, or when relapsing occurs.<sup>5</sup> As seen in this case study, the patient was treated initially with prednisone but was stopped due to the diagnosis of diabetes. The patient was treated with Humira but was terminated due to the patient's history of DVT. The patient was finally treated with methotrexate, which benefited the relief of pain. However, unfortunately, long-term therapy is not successful in terminating the disease or preventing fatality.

#### **Conclusion**

Relapsing Polychondritis follows a relapsing and remitting course without a steady progression of the disease. The prognosis varies dependent on which and how many systems are involved in the disease. With early detection and optimal treatment, the survival rate of an individual diagnosed with RP is higher. Due to the rarity of

this disease, research for treatment is not extensive. Future research for RP should focus on multisystem treatments and pharmaceutical intervention. In addition, early detection of RP alongside of extensive research could prevent the severity of multisystem degeneration.

#### **Acknowledgements**

We would like to thank Dr. Mark Kosinski for introducing us to the patient and for his help in organizing and directing this study.

#### **Authors' Contributions**

All authors contributed equally to this study.

#### **Statement of Competing Interests**

The authors declare that they have no competing interests.

#### **References**

1. Letko E, Zafirakis P, Baltatzis S, et al. Relapsing Polychondritis: A Clinical Review. *Seminars in Arthritis and Rheumatism*. 2002; 31: 384-395
2. Diamantino F, et al. Sweet's Syndrome and relapsing polychondritis signal myelodysplastic syndrome. *An Bras Dermatol*. 2011; 86
3. Herrera I, Mannoni A, Altman R. Relapsing polycondritis: commentary. *Reumatismo*. 2002; 54: 301-306
4. Hansson, A, Holmdahl, R. Cartilage-specific autoimmunity in animal models and clinical aspects in patient-focus on relapsing polychondritis. *Arthritis Research and Therapy*. 2002; 4: 296-301
5. Pol K, Jarosz M. Relapsing Polychondritis: case report and literature review. *Polskie Archiwum Medycyny Wewnetrznej*. 2009; 119 (10)
6. Lekpa F, Kraus V, Chevalier X. Biologics in Relapsing Polychondritis: A Literature Review. *Seminars in Arthritis and Rheumatism*. 2012; 41: 712-719