

# Podiatric Medical Review

Volume 25

2016-2017

<p><b>The Efficacy of Platelet-Derived Growth Factor Compared to Other Non-Surgical, Conservative Modalities in the Treatment of Diabetic Foot Ulcers</b> 4  <i>Diltaj Singh, BS, Sonia M Simon, BS, MS, Basil Rafiq, BS, Brian M Wolff, BA</i></p>	<p><b>A Systematic Qualitative Literature Review on the Surgical Management of an Acute Achilles Tendon Rupture</b> 119  <i>Kenny Luong, BA, Wesley Nesbit, BA, Jones Thomas, BS</i></p>
<p><b>Arthroscopic Treatment of Talar Dome Osteochondral Defects Using Chondralfix Osteochondral Allograft: A Case Report</b> 15  <i>Matthew D'Angelo, BS, Ginette Illuzzi, BS, Michael Warren, BS, Thomas Vitale, DPM</i></p>	<p><b>Surgical Correction of Bilateral Postaxial Polydactyly in a Six-Year-Old Female with Polydactyly of the Hands and Feet: A Case Report</b> 133  <i>Victoria Solomon, BA, Joseph Waterhouse, BS, Asher Wiederkehr, BS</i></p>
<p><b>Botulinum Toxin for the Treatment of Chronic Plantar Fasciitis: A Review of the Literature</b> 21  <i>Thomas Ehlers, BA, Amber Kavanagh, BS, Jennifer Grzesik, BA, Josh Ouellette, BS</i></p>	<p><b>Current Surgical Interventions in the Treatment of Symptomatic Type II Accessory Navicular</b> 141  <i>Brittany Hervey, BS, Kevin Yee, BA, Grace Tsai, BSN</i></p>
<p><b>Review of New and Innovative Direct Plantar Plate Surgical Interventions via Dorsal and Plantar Surgical Approaches</b> 36  <i>Shalanda L Hall, RN, BSN, Chengcheng Tu, MPH, BS, Nader F Ghobrial, MBBCH, MS</i></p>	<p><b>Comparison of Modified Chrisman Snook and Modified Brostrom Technique for Chronic Lateral Ankle Instability: A Literature Review</b> 156  <i>Mustafa Ahmed, BS, Shadi Aouad, BS, Mazin Sadik, MBCHB, Rahman Majid, BA</i></p>
<p><b>The Efficacy of the Ilizarov Technique in Children with Recurrent Clubfoot Deformities: A Qualitative Systematic Review</b> 48  <i>Lauren Murphey, BA, Priam Sandilya, MBS, Ronika Sethi, BS</i></p>	<p><b>An In-Depth Comparison of Various Surgical Treatments for Haglund's Deformity</b> 165  <i>Wade Chimerofsky, BS, Ashima Choudhary, BS, Angelica Emeakoroha, BS, Thi Pham, BS, MS, Ying Shao, BS</i></p>
<p><b>Soft Tissue Sarcomas of the Distal Lower Extremity: A Literature Review of Case Series</b> 59  <i>Sara Stachura, BS, BA, Lauren Kuenzi, BS, Adenike Sonaike, BS</i></p>	<p><b>The Classification, Diagnosis, Treatment &amp; Prevention of Turf Toe Injuries</b> 177  <i>Jennifer Kuinov, BS, Estelle Raad, BS, MS</i></p>
<p><b>Surgical Correction of Bilateral Rigid Equinovarus Deformity in a Young Adult Following a Motor Vehicle Accident: A Case Report</b> 70  <i>Amanda Siegel, BS, Petrina Yokay, BS, Thomas Vitale, DPM</i></p>	<p><b>Comparison of Surgical Techniques for Charcot-Marie-Tooth</b> 188  <i>Mohammed Gheith, BA, Rowan Mahmoud, BS</i></p>
<p><b>Arthroscopic Brostrom Repair Versus Open- Brostrom for Lateral Ankle Instability: Current Literature Review</b> 85  <i>Charles Hu, BS, Caroline Tippett, BS, Hesam Naenifard, BS, MPH, Fawzy Ibrahim, BA</i></p>	<p><b>A Comparison of Traditional and Novel Conservative Treatments for Plantar Fasciitis: A Literature Review</b> 206  <i>Grace Tsai, BSN, Gavin Tsuchida, BS, Darren Doi, BS, Lucian Feraru, BS</i></p>
<p><b>Treatment of Cystic Osteochondral Lesion of the Talus: A Literature Review</b> 101  <i>HyunJi Boo, BS, Michelle Diaz, BS, Hussain Hussain, BS</i></p>	<p><b>Surgical Management of a Malignant Marjolin's Ulcer: A Case Report</b> 222  <i>Mai T. Pham, BS, Kevin Yee, BA, Gabrielle Lee, BA, Munjed S. Salem, DPM, Sharon R. Barlizo, DPM</i></p>

# P M R

---

## STUDENT JOURNAL OF THE NEW YORK COLLEGE OF PODIATRIC MEDICINE

---

***Editors-in-Chief***  
***Djavlon Khakimov, BS***  
***Sang Hyub Kim, BA***

---

***Senior Editors***  
Diltaj Singh, BS  
Sara Stachura, BS, BA  
Shadi Aouad, BS

***Editor***  
Brittany Hervey, BS

---

***Student Peer Reviewers***

Mustafa Ahmed, BS  
HyunJi Boo, B.Sc.  
Wade Chimerofsky, BS  
Karla De La Mata, BS  
Michelle Diaz, BS  
Jonathan Fung, BS  
Mohammed Gheith, BA  
McKenna Green, BS  
Charles Hu, BS  
Hussain Hussain, BS  
Rahman Majid, BS  
Tyrone Mayorga, BA  
Raymond Morales, BS  
Olesya Palko, BS  
Sanjna Sanghvi, BS  
Ilona Stoyko, BS  
Brian M. Wolff, BA

***Faculty Reviewers***

Sharon Barlizo, DPM  
Jeffrey J. Cusack, DPM  
Matrona Giakoumis, DPM  
Johanna Godoy, DPM  
Anthony Jabra, DPM  
Kristina Karlic, DPM  
Mark Kosinski, DPM  
Danielle McNeil, DPM  
Barbara Resseque, DPM  
Susan Rice, DPM  
Thomas Vitale, DPM  
Russell Volpe, DPM

---

***Faculty Advisor***  
Anthony Iorio, DPM

***Communications Director***  
Ellen Lubell, Editor

# A Note from the Editors



*T*hrough continuous research, we are able to demonstrate our relentless dedication to the practice of evidence-based medicine. It is our duty to stay current with the latest development in the podiatric medical literature in order to deliver optimal patient care.

It is with immense pride and honor that we present the twenty-fifth volume of the Podiatric Medical Review (PMR). From the day of its inception, this journal has been compiling superior papers written by students who seek groundbreaking techniques and innovative therapeutic options within podiatric medicine.

This was a record-breaking year of manuscript submissions as a result of our research presentations and guided mentorship in seeking novel research ideas. We carefully curated highest quality manuscripts that exhibited innovation and unique approaches towards treatment methods via thoroughly designed and well-conducted research.

Finally, we would like to express our utmost appreciation to the senior editors, editors, and peer reviewers. With endless research coupled with a commitment to advancement within podiatric arena, the publication of this journal was made possible. We hope you are inspired by the myriad of topics presented and that you continue to quench your thirst for knowledge. It is our mission to pursue cutting-edge research and improve the level of care we provide to our patients.

**Sang Hyub Kim, BA**  
Editor-in-Chief

**Djavlon Khakimov, BS**  
Editor-in-Chief

# The Efficacy of Platelet-Derived Growth Factor Compared to Other Non-Surgical, Conservative Modalities in the Treatment of Diabetic Foot Ulcers

*Diltaj Singh, BS, Sonia M. Simon, BS, MS, Basil Rafiq, BS, & Brian M. Wolff, BA*

## Abstract

### Introduction

Diabetic foot ulcers (DFUs) are defined as full-thickness skin wounds that appear anywhere below the level of the ankle by the International Consensus on the Diabetic Foot. The current standard of care (SOC) for DFUs consists of four components: off-loading, infection control, use of wound dressings, and debridement. Platelet-derived growth factor (PDGF) is the only type of growth factor that has been approved by the United States Food and Drug Administration for the treatment of chronic, non-healing DFUs. The objective of this paper is to conduct a reproducible, qualitative systematic review of literature comparing PDGF therapy to other non-surgical, conservative modalities used for the treatment of DFUs.

### Study Design

Qualitative Systematic Review of Literature

### Methods

Two independent English PubMed searches were conducted using MeSH terms and Boolean Operators. The first search was conducted using: ((platelet derived growth factors) OR pdgf) AND diabetic foot ulcers. This yielded 118 articles. The second search was conducted using: (((pdgf) OR platelet derived growth factors) AND other treatment options) AND diabetic foot ulcers. This yielded 1 article. Inclusion criteria mandated studies that only used human subjects pertaining to the subject of this paper. Exclusion criteria consisted of papers not written in English and papers published prior to 2012. After employing the inclusion/exclusion criteria, a total of 11 articles were chosen for final review.

### Results

Six out of the eleven papers used in this qualitative systematic review were further analyzed. The study design, sample size, intervention, and conclusion for each of these references were summarized.

### Conclusion

One study concluded that recombinant human (rh) PDGF therapy was unsuccessful at treating Wagner grade 1 DFUs; another study found that rhPDGF significantly improved wound healing in Wagner grade 2 and grade 3 ulcers. Treatment of DFUs requires aggressive management and care. SOC in the form of offloading, debridement, and antibiotics are all essential first steps in the treatment of DFUs. PDGF therapy adjuvant to SOC is the best approach to DFU treatment. Many limitations were noted in the form of publication bias, small sample size, and competing interests. Further high quality, unbiased research is needed to determine the efficacy of PDGF in the treatment of DFUs.

### Key Words

Platelet-derived growth factor (PDGF), recombinant human platelet-derived growth factor (rhPDGF), recombinant human platelet-derived growth factor-BB (rhPDGF-BB), growth factor (GF), diabetic foot ulcer (DFU), becaplermin gel, good wound care (GWC), standard of care (SOC)

*Level of Evidence: 4*



## INTRODUCTION

### *Diabetic Foot Ulcers and Wound Healing*

Peripheral neuropathy, foot deformity, peripheral vascular disease, trauma, and peripheral edema are a few of the most common causes of diabetic foot ulcers (DFUs).<sup>1</sup> The International Consensus on the Diabetic Foot defines a foot ulcer as a wound anywhere below the ankle that encompasses the full thickness of the skin. It is important to note that the ulcer can spread and damage the underlying muscle, tendon, and bone.<sup>2</sup> Normal wound healing occurs through a series of events described as: thrombosis and inflammation, cell migration and proliferation, contraction, and remodeling of structures.<sup>3</sup> An understanding of wound healing has aided the use of

different therapeutic agents to encourage wound healing.<sup>4</sup> There are currently many DFU-grading systems used: the Wagner-Meggitt wound classification system (**Table 1**), the International Association of Enterostomal Therapy classification (**Table 2**), the PEDIS system, and the University of Texas Wound Classification System are a few of the most popular ones.<sup>2</sup>

### *Statistics and Epidemiology*

It is projected that as many as 366 million people will have diabetes by the year 2030. Studies assert that lower extremity disease is an estimated two times more likely in people with diabetes compared to people without.<sup>2</sup> Approximately 15-25% of diabetic patients will acquire a foot ulcer sometime in their life.<sup>6</sup> Of those patients who develop a

<b>Grade 0</b>	Preulcerative lesion.
<b>Grade 1</b>	Partial thickness wound up to but not through the dermis.
<b>Grade 2</b>	Full thickness wounds extending to tendons or deeper subcutaneous tissue but without bony involvement or osteomyelitis.
<b>Grade 3</b>	Full thickness wound extending to an involving b
<b>Grade 4</b>	Localized gangrene.
<b>Grade 5</b>	Gangrene of whole foot.

**Table 1:** Wagner-Meggitt classification by Khandelwal et al. is licensed under CC BY-NC 3.0.<sup>5</sup>

<b>Stage I</b>	Non-blanchable erythema of intact skin; the heralding lesion of skin ulceration.
<b>Stage II</b>	Partial thickness skin loss involving epidermis and/or dermis. Ulcer is superficial and presents clinically as an abrasion, blister, or shallow crater.
<b>Stage III</b>	Full thickness skin loss involving damage or necrosis of subcutaneous tissue that may extend down to, but not through, underlying fascia. The ulcer presents clinically as a deep crater with or without undermining of adjacent tissue.
<b>Stage IV</b>	Full thickness skin loss with extensive destruction, tissue necrosis or damage to muscle, bone, or supporting structures ( <i>viz.</i> tendon or joint capsule).

**Table 2:** International Association of Enterostomal Therapy classification by Khandelwal et al. is licensed under CC BY-NC 3.0.<sup>5</sup>

DFU, 12% will require an amputation.<sup>7</sup> Additionally, only 2/3 of ulcers ever heal with or without surgery.<sup>3</sup> Foot amputations are preceded by DFUs in 85% of diabetic patients and are a major complication of DFUs.<sup>2</sup> Thus, the quality of life can significantly decrease in patients with DFUs if not managed appropriately. Treatment of DFUs costs approximately \$20,000 per patient annually.<sup>7</sup> Shortening healing time stands to greatly reduce the cost of treatment of DFUs. DFUs are strongly correlated with mortality rates of 16.7% at 12 months and 50% at 5 years.<sup>8</sup>

#### *Platelet-Derived Growth Factor*

Growth factors (GFs) are regulatory peptides that are made and secreted by many cell types involved in the wound healing process. They function to cause cells to migrate, proliferate, differentiate, and synthesize different

compounds.<sup>4</sup> There are many types of GFs, such as epidermal growth factor (EGF), platelet-derived growth factor (PDGF), and fibroblast growth factor (FGF).<sup>6</sup> PDGF includes five homodimers: AA, AB, BB, CC, and DD.<sup>9</sup> In a double blind, placebo-controlled multicenter study, 118 patients with chronic full-thickness diabetic neuropathic ulcers were treated for 20 weeks or until complete healing. Of the 61 patients treated with recombinant human platelet-derived growth factor-BB (rhPDGF-BB), 48% found complete wound healing compared with 25% of the 57 patients in the placebo group.<sup>4</sup> This study led to the approval of rhPDGF-BB for the treatment of chronic, non-healing DFUs in 1997 by the United States Food and Drug Administration.<sup>6</sup> RhPDGF can increase collagen production through fibroblasts and can promote angiogenesis by stimulating migration.<sup>4</sup>

### *Current Standard of Care Options*

PDGF treatment is not a substitute for good wound care (GWC).<sup>7</sup> The current treatment protocol, also referred to as GWC or standard of care (SOC), for DFUs typically consists of four requirements: off-loading, infection control, use of wound dressings, and debridement.<sup>2</sup> For a neuropathic foot ulcer, the pressure must be redistributed as seen with off-loading. The highest healing rates come from using a total contact cast (TCC), which is considered the gold standard. However, it is not commonly used because TCC requires a trained staff and is contraindicated with infections, contralateral foot ulcers, significant arterial insufficiencies, and balance problems. Additionally, because TCC can limit daily activity, it also leads to poor patient compliance. Another requirement of the SOC for DFUs is the use of wound dressings. Dressings create a moist environment, prevent infections, and absorb wound fluids. There are many advanced dressings, but significant comparisons have only been made for hydrogel dressing, which improves healing more so than basic dressings. Although there are many forms of debridement, surgical debridement is the gold standard for DFUs. Surgical debridement stimulates GF production allowing for more responsive healing. If healing does not take place, adjunctive therapies are considered (i.e. rhPDGF).<sup>8</sup> Even with SOC for DFUs, many ulcers fail to heal, which

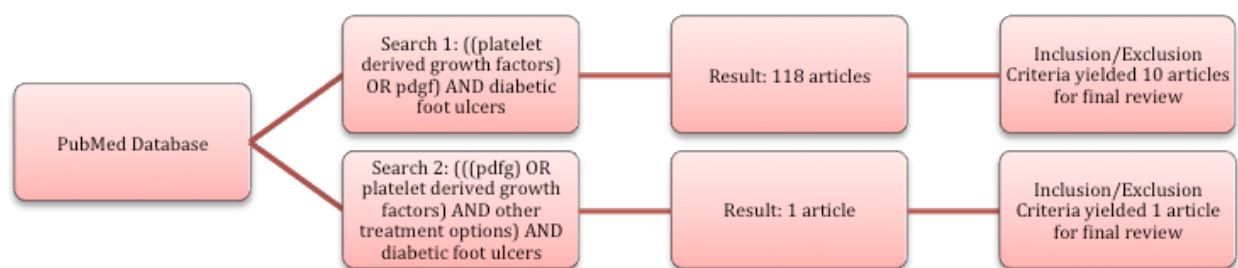
increases both the risk of amputations and the development of infections.<sup>6</sup>

### *Objective and Hypothesis*

The objective of this paper is to conduct a systematic review of the literature regarding the efficacy of PDGF in the treatment of DFUs compared to other conservative, non-surgical treatment modalities. We hypothesized that PDGF application is an innovative and effective approach to the treatment of DFUs, and should be considered as a first line therapy in the conservative management of DFUs prior to surgical intervention.

## METHODS

Two independent English searches were conducted on the PubMed database. Both independent searches employed MeSH terms and Boolean Operators (AND, OR, & NOT). The first search was established by: ((platelet derived growth factors) OR pdgf) AND diabetic foot ulcers. This resulted in 118 articles. The second search was established by: (((pdgf) OR platelet derived growth factors) AND other treatment options) AND diabetic foot ulcers. This resulted in 1 article. Inclusion criteria involved studies that used only humans as subjects to test the efficacy of PDGF therapy for the treatment of DFUs. Exclusion criteria involved papers not written in English and papers published prior to 2012. After applying the inclusion and exclusion criteria, the first search yielded 10 articles for final review and the



**Figure 1:** Flow chart depicting summary of methods

second search yielded 1 article for final review for a total of 11 articles used in this qualitative systematic review of literature. A summary of the methods employed in this paper is depicted in **Figure 1**.

## RESULTS

In a prospective randomized controlled trial (RCT) involving 60 subjects with either stage III or stage IV DFUs (according to the International Association of Enterostomal Therapy classification; **Table 2**), Khandewal et al. found that PDGF therapy was significantly more effective in achieving complete wound contracture than either hyperbaric oxygen therapy (HBOT) or the antiseptic dressing (control) with a P-value equal to 0.0348. The use of PDGF therapy was anecdotally found to be more convenient and less costly for patients than HBOT.<sup>5</sup>

Ma et al. enrolled 46 male diabetic participants in their study, with 23 participants randomly assigned to one of two treatments groups. Eligible patients had to have a Wagner grade 1 DFU for at least 1 month. They

received placebo hydrogel dressing (control group) or rhPDGF gel (test group). Additionally, all participants received a short leg walking cast with a window applied at the site of the ulcer. Patient and wound characteristics were compared in each group. Each subject was educated on how to perform proper daily care for DFUs and was instructed on a uniform method of dressing application. The study lasted for 4 months, with a final follow-up visit 6 months after complete healing or at 10 months if the wound was not healed at the 4-month mark. Based on intention-to-treat, not excluding participants who dropped out, it was determined that there was no significant difference in healing rates at 4 months between the control and test groups for Wagner grade 1 DFUs (57% and 52%, respectively).<sup>10</sup>

Dumville et al. performed a qualitative systematic review in the Cochrane library with the objective of comparing the effectiveness of hydrogel dressing to various other conservative treatment modalities, including PDGF, in the treatment of DFUs. The PDGF used in the study

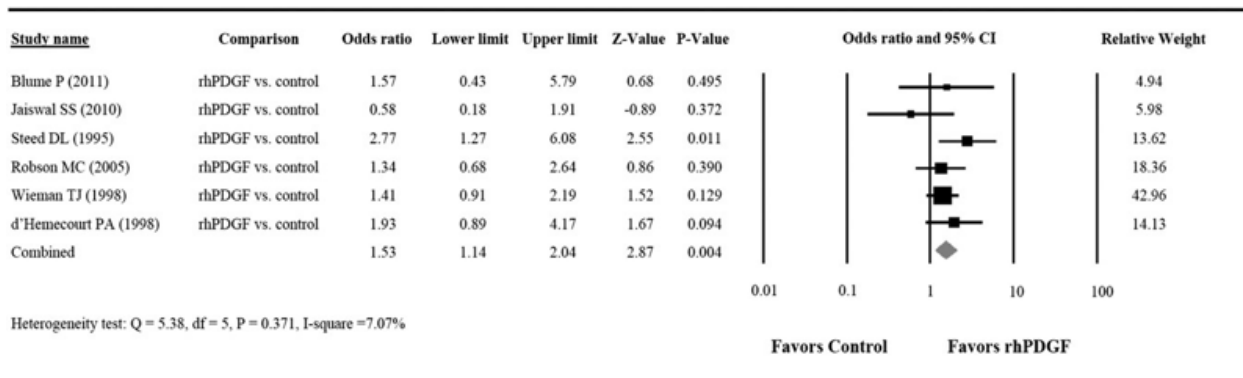


was in the form of 100 µg/g of becaplermin gel. A three-arm study by D’Hemecourt, 1998 assessed 104 total participants in 1 trial, with a maximum follow up of 20 weeks. This study concluded that no statistical difference was noted between the healing rates of hydrogel dressed DFUs (25/70; 36%) compared to becaplermin gel treated DFUs (15/34; 44%).<sup>2</sup>

Braun et al. assessed systematic reviews and performed a meta-analysis to evaluate the effectiveness of GFs for DFUs. The GFs studied included rhPDGF, recombinant human epidermal growth factor (rhEGF), and basic fibroblast growth factor (bFGF). It was found that rhPDGF significantly increased the amount of healed ulcers while also decreasing healing times ( $p < 0.05$ ).<sup>8</sup> However, many of the studies included in this systematic review had several methodological limitations, including the lack of blinding.

Zhao et al. performed a meta-analysis of 6 RCTs that had a total of 992 participants in 173 identified studies. The objective of this study was to compare rhPDGF therapy plus SOC versus SOC plus placebo versus SOC alone. This study concluded that topical treatment with rhPDGF plus SOC was more effective in treating diabetic lower-extremity ulcers when compared to SOC plus placebo or SOC alone (**Figure 2**). A p-value equal to 0.004 was noted. No publication bias was noted as evidenced by the symmetry of the funnel plot analysis for publication bias. An Egger intercept test also supported no significant evidence for publication bias ( $t = 0.195$ ,  $df = 4$ ,  $p = 0.428$ ).<sup>6</sup>

In a large retrospective cohort study of 24,898 participants, Gilligan et al., found that PDGF significantly increased healing rates of DFUs ( $p = 0.0001$ ) and significantly reduced amputations as a result of DFUs ( $p = 0.0001$ ). Gilligan et al. estimated the cost of treatment of a DFU with

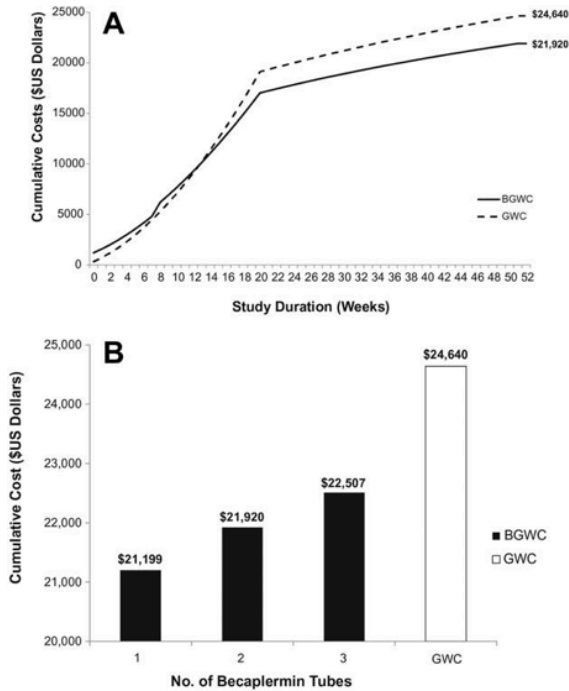


**Figure 2:** Meta-analysis for complete healing rate of diabetic lower-extremity ulcers between rhPDGF and control groups from Zhao et al. reprinted with permission from Elsevier and the Copyright Clearance Center.<sup>6</sup>

References:	Study Design:	Sample Size:	Intervention:	Conclusions:
Khandelwal et al. <sup>5</sup>	Prospective RCT	60 total participants divided between three groups	PDGF vs. HBOT vs. antiseptic dressing (control) in stage III and IV ulcers ( <b>Table 2</b> )	PDGF therapy was significantly more effective than the control group, but not significantly different from HBOT
Ma et al. <sup>10</sup>	RCT	46 total participants	Topical PDGF	PDGF does not appear to significantly improve healing rates when compared to placebo hydrogel dressing of Wagner grade 1 DFUs that are also treated with off-loading
Dumville et al. <sup>2</sup>	Intervention Qualitative Systematic Review of Literature	1 trial with 104 total participants	Hydrogel dressing compared with PDGF	No statistically significant difference in hydrogel dressing ulcer-healing rate (25/70 or 36%) versus Becaplermin gel ulcer-healing rate (15/34 or 44%)
Braun et al. <sup>8</sup>	Literature Review	34 studies	rhPDGF vs. rhEGF vs. bFGF	rhPDGF significantly decreases healing time of ulcers when used with SOC
Zhao et al. <sup>6</sup>	Qualitative Systematic Review & Meta-Analysis of RCTs	6 RCTs with 992 total participants from 173 studies	rhPDGF treatment with SOC vs. placebo with SOC vs. just SOC alone	rhPDGF therapy had significantly greater amount of complete ulcer healing rates when compared to a placebo or SOC alone
Gilligan et al. <sup>7</sup>	Retrospective Cohort Study between 1998-2004	24,898 total participants	BGWC vs. GWC only	PDGF reduces the economic burden of DFUs and significantly reduces amputation rates

**Table 3:** Summary of Results for Each Reference

GWC alone to be 12% higher than in patients receiving GWC plus becaplermin gel (BGWC) (**Figure 3**).<sup>7</sup>



**Figure 3:** A: anticipated annual cost of DFUs; B: cumulative cost of treatment from Gilligan et al. is licensed under CC BY-NC-ND 4.0.<sup>7</sup>

## DISCUSSION

The International Working Group on the Diabetic Foot concluded in 2007 and 2011 that the use of GFs is not well established in the clinical management of DFUs.<sup>6</sup> However, the evidence collected in this systematic review of literature suggests a role for GFs, and particularly rhPDGF, in the treatment of DFUs.<sup>5, 6, 9, 11</sup>

Not all of the papers analyzed supported the effectiveness of

rhPDGF therapy for DFUs. Dumville et al. concluded no significant difference in ulcer healing rate between hydrogel dressing and Becaplermin gel dressing.<sup>2</sup> Ma et al. hypothesized that there should be better healing rates when using more than one conservative treatment modality, but this was not the case. This study concluded that rhPDGF therapy does not significantly improve healing rates and does not significantly decrease time to healing of Wagner grade 1 ulcers when compared to the placebo and used in combination with well padded short leg windowed casts. Regression analysis performed on the many patients and wound characteristics of all of the participants revealed that healing duration rates were only significantly correlated with initial wound size and excessive wound drainage. The differences in these factors could account for the results of the study, which concluded that exceptional healing rates were seen when using casting alone.<sup>10</sup>

In contrast to the conclusion of Dumville et al. and Ma et al., the study by Khandelwal et al. asserted that stage III and stage IV DFUs, according to the International Association of Enterostomal Therapy classification (**Table 2**), healed significantly better with PDGF therapy when compared to HBOT or placebo. Stage III and stage IV ulcers can be converted to Wagner grade 2 and grade 3 ulcers based on **Table 2** and **Table 1**, respectively.<sup>5</sup> Comparably, Goudie et al. determined

that rhPDGF is effective in stimulating the growth of granulation tissue on the calcaneus following a partial calcanectomy as a result of DFUs complicated by osteomyelitis. This study defended this assertion with a proposed limb salvage multimodal therapy algorithm evaluated on a 5-year retrospective cohort study of a specific diabetic population. Patient criteria included having a heel ulcer greater than 4 cm in diameter with a bone infection and requiring revascularization.<sup>11</sup> This study concluded that a multimodal aggressive approach that included distal venous bypass surgery to obtain adequate perfusion, a partial calcanectomy and intra-operative negative pressure wound therapy (NPWT) placement, and treatment with rhPDGF led to a total limb salvage rate of 76% at 2 years for this specific patient population.<sup>11</sup> Thus, both of these studies assert the usefulness of PDGF therapy for wound healing, contradicting the results of Dumville et al. and Ma et al.

Additional studies analyzed also supported the conclusions of Goudie et al., and Khandelwal et al. For example, Zhao et al. concluded that rhPDGF therapy plus SOC was better at healing DFUs than SOC plus placebo or SOC alone.<sup>6</sup> Moreover, Friedlaender et al. concluded that PDGF was useful in treating DFUs by utilizing specific products such as rhPDGF-BB.<sup>9</sup> Furthermore, the use of rhPDGF in a meta-analysis of 5 trials by Martí-Carvajal et al. reported increased complete wound healing

(205/428; 47.89%) when compared to the placebo (109/335; 32.53%).<sup>1</sup> However, more research is needed to determine which patients may benefit from PDGF therapy and which patients may not.

The field of podiatry could benefit from a large RCT aimed at determining which patients would benefit most from rhPDGF therapy since there is a lack of good quality, empirically-based studies.<sup>8</sup> Zhao et al. stated that it was important to do a cost-benefit analysis of rhPDGF therapy in developing countries in addition to the analysis already done in developed countries as asserted by Gilligan et al.<sup>6, 7</sup> This is necessary in order to have a global perspective and to determine if rhPDGF therapy can be fiscally used in developing countries that also suffer from DFU related complications. Understanding this global perspective could reduce the amount of amputations and save lives in the process.

## LIMITATIONS

There were many limitations noted in the references used for this systematic review. A limitation of the Zhao et al. meta-analysis included the emphasis of comparing rhPDGF with a placebo and SOC only, without the comparison to other conservative, non-surgical treatment modalities.<sup>6</sup> Additionally, Gilligan et al. showed evidence of selection bias. The control group not receiving PDGF was an older population with larger wounds



on average. Also, two of the authors of this study were employees of Smith & Nephew, a company that produces becaplermin gel (a topical rhPDGF-BB).<sup>7</sup> Ma et al. reported a small sample size, possibly concealing the 30-35% increased healing rate of DFUs from topical PDGF therapy as seen in previous, larger RCTs.<sup>10</sup>

Goudie et al. discussed the use of PDGF in therapy for heel ulcers in diabetic patients, but there was no comparison to a control group that did not receive the PDGF therapy. In spite of the good patient outcomes observed in this study, there was no definitive evidence for or against the use of PDGF, as it was only one aspect of the overall treatment plan. Rather, this study offered a new multimodal limb salvage algorithm applied to a specific diabetic population.<sup>11</sup> Limitations according to Marti-Carvajal et al. included not knowing the possible side effects from PDGF therapy and bias introduced from sponsored trials. Also, according to the authors the study was underpowered.<sup>1</sup> Although there was evidence that rhPDGF therapy was not significantly better at healing DFUs than other conservative treatment options, there were no contraindications noted by any of the papers and more research is needed to determine if rhPDGF therapy can be harmful in certain patient populations.

## CONCLUSION

This study rejects the hypothesis that PDGF should be used as a first choice option in the conservative care

management of all DFUs. Rather, DFUs require aggressive management and care. Offloading, debridement, and antibiotics are all essential to SOC for DFUs. Currently rhPDGF is the first and only FDA approved GF in the treatment of DFUs.<sup>8</sup> PDGF therapy adjuvant to SOC may improve outcomes and prevent further complications such as amputations.

Furthermore, PDGF may be ineffective in some patients. Evidence for PDGF therapy was stronger for Wagner grade 2 and grade 3 ulcers, but did not significantly improve healing rates in Wagner grade 1 ulcers.<sup>5, 10</sup> The field of podiatry and diabetic wound care would benefit from further high quality, unbiased research on PDGF therapy.

## AUTHORS' CONTRIBUTIONS

Four authors contributed equally to the construction of this paper. DS conceived the topic. All authors performed the initial literature reviews, evaluated abstracts, and collaborated on each section of this paper. All authors drafted, read, reviewed, and agreed upon the final manuscript before publication.

## STATEMENT OF COMPETING INTERESTS

The authors declare that they have no competing interests associated with this manuscript.

## REFERENCES

1. Martí-Carvajal, A.J., Gluud, C., Nicola, S., Simancas-Racines, D., Reveiz, L., Oliva, P., and Cedeño-Taborda, J. Growth Factors for Treating Diabetic Foot Ulcers. *Cochrane Database of Systematic Reviews*. 2015; 10. DOI: 10.1002/14651858.CD008548.pub2.
2. Dumville, J.C., O'Meara, S., Deshpande, S., and Speak, K. Hydrogel Dressings for Healing Diabetic Foot Ulcers. *Cochrane Database of Systematic Reviews*. 2011; 9. DOI: 10.1002/14651858.CD009101.pub2.
3. Jeffcoate, W.J. & Game, F.L. Evidence for the Use of Biological Therapies in Ulcers of the Foot in Diabetes. *BioDrugs*. 2014; 28: 1. DOI: 10.1007/s40259-013-0052-3.
4. Kiwanuka, E., Junker, J., and Eriksson, E. Harnessing Growth Factors to Influence Wound Healing. *Clinical Plastic Surgery*. 2012; 39(3): 239-48. DOI: 10.1016/j.cps.2012.04.003.
5. Khandelwal, S., Chaudhary, P., Poddar, D.D., Saxena, N., Singh, R.A.K., and Biswal, U.C. Comparative Study of Different Treatment Options of Grade III and IV Diabetic Foot Ulcers to Reduce the Incidence of Amputations. *Clinics and Practice*. 2013; 3(1): e9. DOI: 10.4081/cp.2013.e9.
6. Zhao, X.-H., Gu, H.-F., Xu, Z.-R., Zhang, Q., Lv, X.-Y., Zheng, X.-J., and Yang Y.-M. Efficacy of Topical Recombinant Human Platelet-Derived Growth Factor for Treatment of Diabetic Lower-Extremity Ulcers: Systematic Review and Meta-Analysis. *Metabolism: Clinical and Experimental*. 2014; 63(10): 1304-1313. DOI: <http://dx.doi.org/10.1016/j.metabol.2014.06.005>.
7. Gilligan, A.M., Waycaster, C.R., and Motley, T.A. Cost-effectiveness of becaplermin gel on wound healing of diabetic foot ulcers. *Wound Rep and Reg*. 2015; 23: 353-360. DOI: 10.1111/wrr.12285.
8. Braun, L.R., Fisk, W.A., Lev-Tov, H., Kirsner, R.S., and Isseroff, R.R. Diabetic Foot Ulcer: An Evidence-Based Treatment Update. *Am J Clin Dermatol*. 2014; 15: 267. DOI: 10.1007/s40257-014-0081-9.
9. Friedlaender, G.E., Lin, S., Solchaga, L.A., Snel, L.B., and Lynch, S.E. The Role of Recombinant Human Platelet-derived Growth Factor-BB (rhPDGF-BB) in Orthopaedic Bone Repair and Regeneration. *Current Pharmaceutical Design*. 2016; 22(46): 3384-3390. DOI: 10.2174/1381612811319190005.
10. Ma, C., Hernandez, M.A., Kirkpatrick, V.E., Liang, L.J., Nouvong, A.L., and Gordon I.I. Topical Platelet-Derived Growth Factor vs. Placebo Therapy of Diabetic Foot Ulcers Offloaded with Windowed Casts: A Randomized, Controlled Trial. *Wounds*. 2015; 27(4): 83-91.
11. Goudie, E.B., Gendics, C., and Lantis, J.C. Multimodal Therapy as an Algorithm to Limb Salvage in Diabetic Patients with Large Heel Ulcers. *International Wound Journal*. 2012; 9: 132-138. DOI: 10.1111/j.1742-481X.2011.00869.x.

# Arthroscopic Treatment of Talar Dome Osteochondral Defects Using Chondralfix Osteochondral Allograft: A Case Report

*Matthew D'Angelo, BS, Ginette Illuzzi, BS, Michael Warren, BS, & Thomas Vitale, DPM*

## Abstract

### Introduction

Osteochondral lesions can occur in various joints throughout the body. Osteochondral lesions of the talus (OLT) may result in chronic ankle pain, which may hinder gait, exercise, or sports-related activities. In recent years, various treatment options have been attempted to correct these talar defects. The purpose of this case report is to investigate the effectiveness of Chondralfix osteochondral allograft in the treatment of a talar dome osteochondral defect in a 62-year-old HIV positive male.

### Study Design

Case Report

### Methods

A 62-year-old African American male presented with recalcitrant left ankle pain. The patient had been evaluated by other physicians in the past for their ankle pain. He denied therapeutic injections as conservative therapy, but received treatments including ankle arthroscopy with talar dome microfracture. The patient had been evaluated by other physicians in the past and received treatments including ankle arthroscopy. The patient was scheduled at Metropolitan Hospital for further operative treatment. The procedure began with arthroscopic identification of partially degenerated talar dome with fibrocartilage formation along the anterolateral surface. The osteochondral defect was identified, as well as large amounts of inflamed synovial tissue along the anterior aspect of the tibial plafond. After removal of devitalized tissue, articular cartilage, and fibrocartilage from the talus and tibia, the subtalar joint was released laterally to allow exposure to the joint itself. Exophytic bone was then removed from the lateral aspect of the talus and tibial plafond using a rongeur. The osteochondral defect was then removed, and a 9mm diameter Chondralfix osteochondral allograft plug was then pressed into the area until it became flush with the surrounding articular surface.

### Results

Ankle range of motion was assessed intraoperatively after arthroscopy and incorporation of allograft, and had immediately improved. After the operation, the patient reported much satisfaction with his procedure and noted improved left ankle range of motion (ROM) with little tenderness one month post-op. The patient also had similar pain in his right ankle, and now describes his left ankle as far less symptomatic than his right ankle following this procedure.

### Conclusion

Osteochondral lesions of the talus are a common cause of ankle pain and functional disability. While the pathophysiology is not fully understood, advances in imaging and arthroscopy techniques have enhanced the ability for diagnosing osteochondral lesions in the ankle joint. In this case report, application of the subchondral allograft plug appears to have successfully treated the osteochondral lesion of the talus with improvements in pain and function.

### Key Words

Osteochondral lesions of the talus (OLTs), osteochondral defects (OCDs), osteochondral lesions (OCLs), Chondralfix osteochondral allograft, Microfracture

*Level of Evidence: 4*

## INTRODUCTION

OLTs are abnormalities of the talar articular cartilage and subchondral bone that can result in a partial or complete detachment of the lesional defect.<sup>1</sup> Historically, osteochondral defects (OCDs) have been described for over a 100 years, but controversy still exists regarding their etiology and morphology.<sup>2</sup> Although acute trauma is implicated as the primary causative agent of osteochondral lesions (OCLs), vascular abnormalities, repetitive microtrauma, genetic predisposition, ossification abnormalities, and endocrine dysfunction are also suspected to play a role in its pathogenesis.<sup>3</sup>

OLTs are a common cause of activity-exacerbated ankle pain and result in a functional disability. On physical examination, the patient may demonstrate tenderness, decreased range of motion, pain on inversion or dorsiflexion, and joint effusion.<sup>4</sup> The acute clinical presentation and progression of these lesions depends on the integrity of cartilage injury and associated subchondral bone injury. Advances in imaging and arthroscopy techniques have enhanced the ability for diagnosing and characterizing OCLs in the ankle joint. The characterization of OCLs by size, depth, stability, displacement, and location aids in selecting an appropriate treatment modality.<sup>3,5</sup> However, lesion characteristics do not reliably predict the outcome of the

treatment intervention or the degree of improvement in a patient's symptoms.

Treatment options for OCDs of the ankle have increased over the last decade. Various techniques exist to address OCDs based on size and depth of lesion, fragment stability, and physeal status. The options for symptomatic OCLs include non-operative treatments such as rest or cast immobilization, as well as surgical intervention.<sup>1</sup> Surgical interventions include debridement, loose body removal, microfracture, arthroscopic reduction and internal fixation, subchondral drilling, osteochondral autograft or allograft transplantation, and autologous chondrocyte implantation. Indicators for operative intervention include: large lesion size, unstable fragment, and clinical symptomatology.<sup>5</sup> While a variety of surgical options exist, there is not one method that has been classified as the standard of care for OCLs. The aim of this study was to evaluate the application of a subchondral allograft plug as one of several surgical treatment options for OLTs.

## CASE PRESENTATION

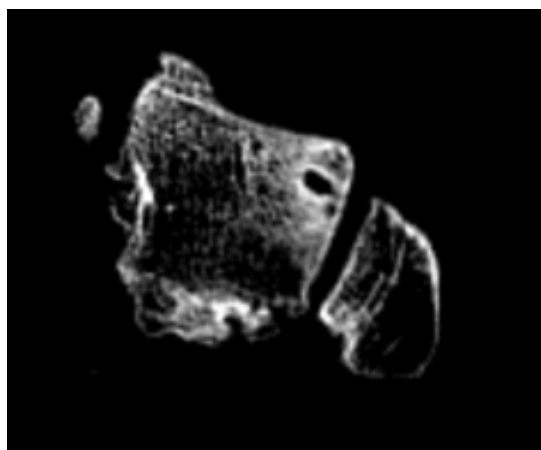
A 62-year-old African American male presented to Metropolitan Hospital with recurrent left ankle pain. He is an avid smoker, the pack-year was unknown, and his medical history includes HIV, COPD, GERD, peripheral neuropathy, and chronic back pain. This patient was treated by



other physicians via ankle arthroscopy but still experienced pain on weight bearing and ambulation. This pain showed little improvement following physical therapy. A CT scan of the left ankle revealed an OCL measuring approximately 9.6mm x 11mm in transverse and AP dimensions (Figure 1). Also noted on CT scan were prominent osteophytes at the anterior talus with opposing osteophytes at the distal anterior tibia. The patient was evaluated and booked for a left ankle arthroscopy, OCD filling, and tibial exostectomy. Following identification of the anteromedial and anterolateral ankle joint portals, a cannulated passer was then introduced into the anteromedial portal for ankle joint examination under arthroscope. The talar dome was noted to be partially degenerated with fibrocartilage formation along its anterolateral surface in addition to the presence of large amounts of inflamed synovial tissue along the anterior aspect of the tibial plafond. Attention was then directed at the anterolateral aspect of the joint. The joint capsule and soft tissue were reflected off the talus and the subtalar joint was inspected, revealing intact articular cartilage and mild hypertrophy of bone on the lateral aspect. A rongeur was then used to resect the exophytic bone at the joint margins. Improved range of motion was noted upon debridement.

Dissection continued at the superior aspect of the incision where the ankle joint was identified. Soft tissue and ligamentous attachments were released laterally allowing joint

exposure. The anterior surface of the tibia impinged upon the talar surface, and a rongeur was used to resect the exophytic bone at the joint margins while a sagittal saw was used to resect the exophytic bone at the lateral aspect of the talus. The foot was then inverted and plantar flexed to better visualize the talar dome and OCD along the lateral margin. The Chondralfix osteochondral allograft implant was measured by drilling and using plug sizers. This was based on the diameter and depth of the defect. The defect was removed and a 9mm diameter plug was then pressed into the punch area until it became flush with the surrounding articular surface. Improvement of the ankle range of motion was noted after examination. Three weeks post-operative radiographic imaging revealed no evidence of intrinsic osseous abnormalities, degenerative changes, erosions, or soft tissue swelling. Upon physical examination, the patient was noted to have improved left ankle range of motion with little tenderness.



**Figure 1:** CT scan of the Anterolateral talar dome lesion of the patient's left ankle (Acquired from the Podiatric Surgery Department at Metropolitan Hospital 2016)

## DISCUSSION

OLTs represent a problematic clinical entity to surgeons. Although the morphology and etiology of these lesions has been controversial, OLTs are being recognized as primarily caused by traumatic ankle sprains. The shearing and compression forces from the trauma results in cartilage contusion that often transmits to the subchondral bone and causes microfractures.<sup>6</sup> Establishing the location and size of the talar lesion is essential for operative planning as well as monitoring the post-operative outcomes of the approach. Raikin et al. designed a nine-grid system to be used intraoperatively as a guide for localizing and characterizing such lesions.<sup>5</sup> It was reported that medial talar dome lesions were significantly more frequent and larger in surface area and depth in comparison to lateral lesions. These findings supported the theory that many OCLs are caused by the impaction of medial talar dome on the medial tibial plafond in inversion ankle sprain injuries.

The options for surgical management of talar cartilage defects have increased substantially over the last decade and continue to evolve as we gain a greater understanding of this challenging pathology. Selection of the most appropriate surgical strategy for OLTs remains complex and controversial. While there are many treatment options, there is no single best technique for treating any given

OCL. Selection of treatment is largely dependent upon size, shape, location, and extent of the lesion.

Surgical treatment options are categorized as either reparative techniques or restorative techniques. Reparative treatments, which include drilling, microfracture, excision curettage, and arthroscopy, aim to replace the hyaline cartilage with fibrocartilage through debridement and bone marrow stimulation.<sup>7</sup> Restorative techniques such as osteochondral autografts or allografts and autologous chondrocyte implantation attempt to replace the hyaline cartilage from the damaged fragment.

### *Surgical Reparative Technique*

Of the reparative techniques, microfracture and drilling stimulates the bone marrow and leads to the development of fibrocartilaginous repair tissue within the defect site. In order to accomplish this, the subchondral plate must be perforated in order to recruit chondroprogenitor cells to the site of the lesion. While it has been found to be successful in smaller lesions, there has been noted to be a higher failure rate in lesions greater than 150 mm<sup>2</sup>.<sup>6</sup> There is also concern over whether this newly formed fibrocartilaginous tissue can withstand normal mechanical loads applied to the talar dome and protect the underlying bone over time.<sup>8</sup>

### *Surgical Restorative Technique*

Autologous chondrocyte transplantation is a restorative technique used to stimulate a hyaline-like repair tissue using viable and cultured chondrocyte-like cells which are transplanted into the defect site. With this technique, one can achieve nearly perfect repair of the entire lesion space. This treatment option tends to be reserved for larger lesions  $> 2 \text{ cm}^2$ .<sup>6,8</sup>

Another restorative treatment option used in the treatment of osteochondral lesions is autologous osteochondral transplantation. This strategy involves the transplantation of viable hyaline cartilage and bone from a less weight-bearing part of the femur of the ipsilateral knee to resurface the defect in moderate lesions measuring 2-4  $\text{cm}^2$ . The size of the defect determines whether one or more cylindrical osteochondral plugs are needed, and if more than one plug is needed they are arranged in a side-by-side fashion within the site of the lesion. This technique aims to recreate the biomechanical and structural characteristics of the primary hyaline talar cartilage. This strategy, however, may prove unsuccessful if there are any differences in size and shape between the donor graft and the defect, leading to surface incongruity or irregularity.<sup>6</sup>

In the case of this particular patient presented in this report, the restorative technique in osteochondral allograft transplantation was looked at. This

treatment option is indicated for large-volume cystic lesions or salvage procedures and ultimately reconstructs large osteochondral defects. A single unit of viable articular cartilage and subchondral bone from a donor or cadaver is matched to size, shape, and surface curvature to resurface the lesion with no limitations based on size of the defect itself. When considering the high congruity of the ankle joint, the customization of the allograft to perfectly match the recipient proves to be a major advantage of this treatment option.<sup>6,8</sup>

## LIMITATIONS

However, one of the major limitations of the osteochondral allograft transplant procedure is the viability of the chondrocytes after a graft has been obtained. It takes roughly one month for the graft to go through a screening process at tissue banks to minimize any transmission of disease. While no viral transmission has been recorded in such allografts, it may pose a problem considering it has been found that there is a 30% decrease in viable chondrocytes after 28 days, with decreased viability, cell density, and metabolic activity noted after just only 14 days of graft procurement and storage. Between this, immunologic reaction to the graft, limited availability of such grafts, and cost, there are multiple disadvantages to counter the previously mentioned benefits of this restorative treatment option for osteochondral lesions.<sup>8</sup>

## CONCLUSION

In conclusion, a variety of operative techniques exist to address OLTs. In this case report, application of the subchondral allograft plug appeared to successfully treat an OLT by showing improvements in both pain and function. This therapeutic treatment resulted in a decrease of symptoms with an increase in activity level for the patient. The clinical relevance of this study identifies that there is no superior corrective procedure for the treatment of OLTs. At this time, further research is necessary to appropriately indicate the most effective treatment for any given OCD. The literature suggests that procedure selection should be dependent on location, size, and depth of lesion. With the collection of more clinical data, physicians will be better able to treat patients suffering from OCLs with a higher clinical success rate in the future.

## AUTHORS' CONTRIBUTIONS

GI wrote the introduction, MD wrote the case presentation, MD prepared figure 1, and MW and GI wrote the discussion and conclusion.

## STATEMENT OF COMPETING INTERESTS

The authors of this case report have no conflicting interests.

## REFERENCES

1. Zegnerink M, Struijs PA, Tol JL, Niek van Dijk, C. Treatment of osteochondral lesions of talus: a systematic review. *Knee Surg Sports Traumatol Arthrosc.* 2010; 18: 238-246.
2. Nagura S. The So-called Osteochondritis Dissecans of König. *Clin Orthop Res.* 2011; 469: 2975-2976.
3. McGahan PJ, Pinney SJ. Current concept review: osteochondral lesions of talus. *Foot and Ankle International.* 2010; 31: 90-101.
4. Erickson BJ, Chalmers PN, Yanke AB, Cole BJ. Surgical management of osteochondritis dissecans of the knee. *Curr Rev musculoskelet Med.* 2013; 6: 102-114.
5. Raikin SM, Elias I, Zoga AC, Morrison WB, Besser MP, Schweitzer ME. Osteochondral lesions of the talus: localization and morphologic data from 424 patients using a novel anatomical grid scheme. *Foot & Ankle International.* 2007; 28:154-61.
6. Baums MH, Schultz W, Kostuj T, Klinger HM. Cartilage repair techniques of the talus: An update. *World J Orthop.* 2014; 5: 171-179.
7. Grady JF, Zager E, Trotter K, Nagesh D. A closer look at drilling and cartilage replacement. *Podiatry Today.* February 2015. <http://www.podiatrytoday.com/closer-look-drilling-and-cartilage-replacement-talar-dome-lesions>. Accessed December 15, 2016.
8. Murawski CD, Kennedy JG. *Journal of Bone & Joint Surgery.* 2013; 95:1045-1054.

# Botulinum Toxin for the Treatment of Chronic Plantar Fasciitis: A Review of the Literature

Thomas Ehlers, BA, Amber Kavanagh, BS, Jennifer Grzesik, BA, & Josh Ouellette, BS

## Abstract

### Introduction

Plantar Fasciitis (PF) is one of the most common foot pathologies treated by podiatrists today. The purpose of this study is to assess the current literature for indications, contraindications, and the effectiveness of botulinum toxin injections as a treatment option to alleviate chronic plantar fasciitis pain. A literature review was conducted to evaluate the available evidence for botulinum toxin type A (BTX-A) injections in the treatment of chronic plantar fasciitis.

### Study Design

Qualitative Systematic Review of the Literature

### Methods

Two literature searches were conducted using the PubMed database. Inclusion criteria consisted of all articles that were either prospective, observational follow-up studies, randomized controlled trials, or randomized single and double-blind studies consisting of a history of plantar fasciitis pain for at least three months where conservative therapies have failed. Exclusion criteria consisted of review articles, articles with studies using combined therapies, diagnosis of inflammatory arthritis, prior surgery, bony abnormalities, studies not specific to human subjects, or trauma to the heel region.

### Results

A total of 34 potential articles were assessed for screening. Twelve articles fit the inclusion criteria and were assessed for significantly measurable outcomes with the use of BTX-A in treating plantar fasciitis. The measurable outcomes that proved to be significant in the assessed articles were: pain relief, improved gait, improved foot function, and reduced plantar fascia thickness.

### Conclusion

Local injection of botulinum toxin to the plantar fascia in patients who are suffering from chronic plantar fasciitis resulted in significant reduction in pain and disability for as long as one year. Based on preliminary data, this could potentially be a mainstay in the future for treating such a condition. Subsequent research should conduct larger scale trials to compare botulinum toxin to corticosteroids and placebo with various quantities and numbers of injections to test for the optimal dose.

### Key Words

Plantar fasciitis, Botox, botulinum toxin A, corticosteroid injection, steroid, musculoskeletal pain

*Level of Evidence:* 4

## INTRODUCTION

The plantar fascia is a thick ligamentous band of connective tissue found on the plantar surface of the foot as part of the deep fascia. It is made up of three longitudinal portions (medial, central, and lateral), with the central band or aponeurosis being the key functional component. This central band attaches proximally to the medial calcaneal tubercle and extends distally where it divides into five fascicles or slips that insert into several soft tissue structures associated with the metatarsophalangeal joint (MTPJ). These fascicles send connective fibers to the dermis, superficial fascia, MTPJ capsule, and the deep transverse metatarsal ligaments.<sup>1,2</sup>

The plantar fascia plays a major role in foot function during the gait cycle. It is a crucial longitudinal arch supporter at the sole of the foot in the stance phase.

Since the plantar fascia is the primary longitudinal arch support structure in the foot, it is easily strained with high forces and tension during the gait cycle. When the loading of forces onto this structure during heel lift surpass the volume of forces it is designed to hold, an inflammatory reaction induced by microtrauma at the calcaneal insertion known as plantar fasciitis (PF) can be induced.<sup>3</sup> This musculoskeletal disorder has been found to affect at least 1 million Americans and is one of the most

common reasons for a patient's visit to a podiatric practitioner.

The diagnosis of PF can be made based on the patient's medical history, physical examination to check for areas of tenderness, and imaging tests such as x-rays. The x-ray may reveal a calcaneal spur that can be related to the condition. The pathologic findings associated with PF include: plantar fascia contracture, fibrosis or periostitis at the calcaneal origin, a shortened quadratus plantae muscle, and shortened toe flexors.<sup>4</sup> It is important to perform a thorough investigation as heel pain can also be caused by a number of other conditions including nerve entrapment, osteoarthritis, Reiter's syndrome, and calcaneal fracture.

While there are a number of treatment modalities for chronic PF used in podiatric practice today, there is no current "gold standard" recommended for care.<sup>2,4</sup> The more conservative options include exercise or walking modifications, stretching regimens, night splinting, orthotics, and non-steroidal anti-inflammatories (NSAIDs). After these options have failed, corticosteroid injections are currently the most common non-conservative treatment method available. Some other progressive techniques include extracorporeal shockwave therapy, protein rich plasma, and botulinum toxin injections.<sup>1</sup>

Botulinum toxin is a neurotoxin produced by a Gram-positive, spore-

forming bacterium, known as *Clostridium botulinum*. There have been found to be eight serotypes of botulinum toxin (A, B, C<sub>1</sub>, C<sub>2</sub>, D, E, F, and G) made by the organism that all have a targeted effect to block the release of the neurotransmitter Acetylcholine (ACh) in the neuromuscular junction, resulting in a flaccid paralysis.<sup>5</sup> The U.S. Food and Drug Administration (FDA) has only approved the medical use of type-A (BoNT-A) and type-M (BoNT-B) to this date for a limited degree of conditions including cervical dystonia, hyperhidrosis, urinary incontinence, muscle spasticity, and cosmetic improvement of the appearance of glabellar lines.<sup>6,7</sup> This makes its use for PF still considered “off-label”.<sup>4</sup> The FDA has also issued a black box warning for botulinum toxin injections due to the possibility of the toxin spreading systemically from the injection site. While the risk is very low, there is a chance of serious adverse effects, such as: life threatening breathing and swallowing difficulties from muscle paralysis, diplopia, dysarthria, and general muscle weakness.<sup>6,7</sup>

The mechanism of action on the neuromuscular junction is linked to the toxin’s ability to cleave soluble N-ethyl-maleimide-sensitive factor attachment receptor (SNARE) proteins. The toxins are produced by the bacterium as single polypeptide chains of 150 kDa. This chain is cleaved into two smaller portions, a light chain of 50 kDa and a heavy chain of 100 kDa, which remain

linked by a disulfide bond. Once injected, the heavy chain functions as the binding domain to receptors on the cholinergic nerve terminal, ensuring the toxin is taken up by endocytosis so the light chain can then act to cleave the SNARE proteins once inside. Since these SNARE proteins (synaptobrevin, syntaxin, and synaptosomal-associated protein-25) are necessary for the formation of vesicles and release of neurotransmitters from the nerve terminal, the necessary signals cannot be passed on to induce muscle contraction. This results in a flaccid paralysis of the nearby muscles, which may ease the stretching of the plantar fascia in PF. SNARE proteins have also been found to play a role in the release of pain mediating substances from vesicles such as substance-P, calcitonin-gene-related peptide, and glutamate.<sup>4</sup> This is another explanation for why BoNT can be so effective at decreasing pain in musculoskeletal conditions. The toxin requires about 24-72 hours to take effect in disrupting various neurotransmitter processes and has been shown to last as long as six months to a year for the relief of symptoms.<sup>5</sup>

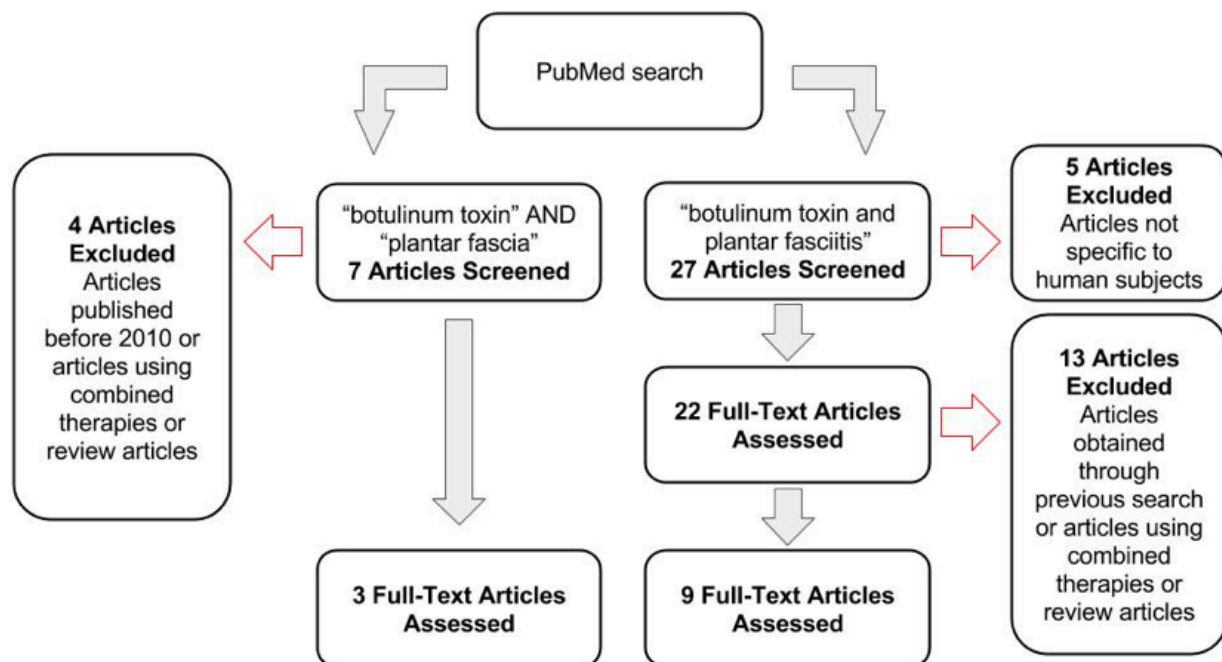
There are three preparations of BoNT-A and one preparation of BoNT-B available for use today. The BoNT-A formulas consist of Botox® (Allergan, Irvine, California), Dysport® (Ipsen, Slough Berkshire, United Kingdom), and Xeomin® (Merz, Frankfurt, Germany). The BoNT-B is known as Myobloc® (Elan Pharmaceuticals,

South San Francisco, California). Botox® is the most common one used in the United States today. Botox® is manufactured in vials containing 100 units (U) of BoNT-A, 0.5 mg of human albumin, and 0.9 mg of sodium chloride. Saline solution is required to reconstitute the BoNT-A preparation.<sup>5</sup> Injections to the plantar fascia are given in the fascia and periosteum (25 U in 0.5 mL of saline solution) and in the quadratus plantae and short toe flexors (75 U in 1.5 mL of saline solution).<sup>4</sup>

## METHODS

Two English language literature searches were conducted using Pubmed databases. The first search was completed using the Boolean

operator “and” for the terms “botulinum toxin” AND “plantar fascia”. This search obtained seven results. Inclusion criteria included articles published in 2010 or afterward, treatment of plantar fasciitis, intramuscular injection or injection into the plantar fascia, and a system to evaluate intensity of pain before and after treatment (pain VAS, pressure algometry, Maryland foot score). Exclusion criteria included review articles, articles published before 2010, or articles with studies using combined therapies. After review of seven articles, three articles were selected for further review based on the abstract summary and the inclusion/exclusion criteria. Four were excluded.



**Figure 1**—Summary of search results from PubMed Database



The second search was completed using the Boolean operator “and” for the terms “botulinum toxin” AND “plantar fasciitis”. This search obtained 27 results. Inclusion criteria included treatment of plantar fasciitis, intramuscular injection or injection into the plantar fascia, a system to evaluate intensity of pain before and after treatment (pain VAS, pressure algometry, Maryland foot score). Exclusion criteria included articles not specific to human subjects, review articles, articles obtained through previous searches, and articles using combined therapies. After review of the 27 articles, nine articles were selected for further review based on abstract summary and the inclusion/exclusion criteria. 18 articles were excluded.

## RESULTS

A PubMed literature search yielded a total of 34 articles for screening. Of the 34 articles, only 12 fit the inclusion criteria and were assessed. The outcomes of nine articles are illustrated in Table 1. The outcomes of the other three (Peterlein et al., Zhang et al., and Tsikopoulos et al.) are not illustrated because either the outcomes were not significant or the article itself was a systematic review and/or meta-analysis.

Chou et al. conducted a case study of a 43-year-old patient, who presented with a chief complaint of right subcalcaneal heel pain.<sup>8</sup> A total of 70U of BTX-A were injected in 2

Study	Initial Number of Subjects	Pain Relief	Improved Gait	Improved Function	Reduced Plantar Fascia Thickness	No Change
Chou et al.	1	✓*			✓	
Babcock et al.	27**	✓				(placebo group)
Huang et al.	50	✓	✓		✓	(control group)
Placzek et al.	9	✓				
Díaz-Llopis et al.	56	✓		✓		
Elizondo-Rodriguez et al.	36	✓		✓		
Ahmad et al.	50	✓		✓		(placebo group)

\* Pain recurred progressively posttreatment

\*\*27 patients were studied at the 3-week follow-up but 7 patients did not report for the 8-week follow-up

**Table 1**—Outcomes of Patients Using Botulinum Toxin A for PF Treatment

**List of Abbreviations**

BTX-A	Botulinum Toxin A
BoNT-A	Botulinum Toxin A
PF	Planter Fasciitis
VAS	Visual Analog Scale
PPT	Pressure Pain Threshold
FAAM	Foot and Ankle Ability Measures
EMG	Electromyography
AOFAS	American Orthopedic Foot and Ankle Society
FADI	Foot and Ankle Disability Index
MPSS	Mainz Pain Staging System
SMD	Standard Mean Difference
CI	Confidence Interval
PRP	Platelet-Rich Plasma

**Table 2**—List of common Abbreviations used in the 12 studies

individual doses: 40U (0.4 mL) into the heel and 30U (0.3 mL) into the foot arch. Ultrasonographic examination was implemented bilaterally. At 1 week posttreatment, there was a decrease in the patient's VAS from 8 to 2.2 and there was a further decrease to 1.5 at 3 weeks posttreatment. Also, there was a decrease in plantar fascia thickness at 1 week and 3 weeks posttreatment; this decrease correlated with a decrease in clinical symptoms. Furthermore, there was an increase in the patient's PPT from 8.1 to 10.4 at 3 weeks posttreatment. However, after seven weeks, there was a recurrence of pain symptoms along with a slight decrease in PPT – the value still remained higher than baseline.

Babcock et al. conducted a prospective, randomized, double-blinded, placebo-controlled study.<sup>2</sup> 27 patients with PF were randomly divided into a treatment or placebo group. The treatment group was given a total of 70U (0.7 mL) of BTX-A in 2 divided doses: 40U (0.4 mL) into the medial aspect of the calcaneal tuberosity and 30U (0.3 mL) into the foot arch. In contrast, the placebo group was injected with a similar volume of saline at the same locations. Compared to the placebo group, the treatment group at 3 weeks had significant changes in all measured outcomes: a 39% decrease in Pain VAS ( $P<0.005$ ), a 34% improvement in the Maryland foot score ( $P<0.001$ ), a 40% increase in pressure algometry ( $P<0.003$ ), and an increase in pain relief ( $P<0.005$ ). At 8 weeks

posttreatment, the treatment group again showed significant results: a 56% decrease in Pain VAS ( $P < 0.005$ ), a 47% improvement in the Maryland foot score ( $P < 0.001$ ), a 56% increase in pressure algometry ( $P < 0.003$ ), and an increase in pain relief ( $P < 0.005$ ).

Huang et al. conducted a randomized, double-blinded control study.<sup>9</sup> 50 patients with chronic unilateral PF were randomly assigned to the experimental group or the control group. The experimental group was injected with 50U of BTX-A into the plantar fascia while the control group was injected with the same volume of saline; both groups received injections under ultrasonographic guidance. Compared to the control group, the experimental group showed a significant decrease in pain VAS ( $P < 0.001$ ) and plantar fascia thickness ( $P < 0.001$ ). The experimental group also showed an improvement in gait and an increase in the center of pressure velocity during the loading response; however, these measured outcomes were not significant. Both control and experimental groups had no change in fat pad thickness. Lastly, the control group had no change in pain scores.

Placzek et al. conducted a pilot study and 1 year follow-up in an open series.<sup>10,11</sup> Nine patients with chronic PF were treated with one injection of BTX-A. 200U (2.0 mL) of BTX-A were injected subfascially at the origin of the plantar fascia. One puncture site was made, but four different directions were used when injecting

the BTX-A. At 2 weeks posttreatment, the patients had a significant decrease in pain VAS at rest ( $P < 0.015$ ). At 6 weeks posttreatment, there was significant reduction of 50% in pain VAS on weight-bearing ( $P < 0.015$ ). At 52 weeks posttreatment, there was a decrease from 1.56 to 1.00 in the MPSS.

Díaz-Llopis et al. conducted a randomized controlled study.<sup>12</sup> 56 patients with chronic PF were randomly divided into the BTX-A group or the corticosteroid group (28 patients in each). The BTX-A group was injected with 70U (0.7mL) of BTX-A in 2 divided doses: 40U (0.4 mL) into the medial aspect of the calcaneal tuberosity and 30U (0.3 mL) between what the authors describe as the talar insertion of the plantar fascia and the plantar arch. In contrast, the corticosteroid group was injected with 2 mL of corticosteroid betamethasone 6mg/mL (as acetate and disodium phosphate) plus local anesthetic (0.5 mL of 1% mepivacaine) near the calcaneal tuberosity; in addition, the corticosteroid group was injected with a placebo in the middle, medial side of the fascia so as to keep the number of injections between both groups equal. At 1 month posttreatment, both groups showed clinical improvement; however, there was a significance difference ( $P = 0.069$ ) in pain for the BTX-A group. At 6 months posttreatment, the BTX-A group had continued improvement whereas the corticosteroid group did not. Overall, the BTX-A group showed

improvement in pain ( $P=0.001$ ), function ( $P<0.001$ ), footwear ( $P=0.004$ ), and self-perceived foot health ( $P<0.001$ ).

Díaz-Llopis et al. conducted an observational follow-up study on 24 patients who had received the BTX-A injection in the randomized study a year prior.<sup>13</sup> Compared to 6 months posttreatment, 1-year posttreatment showed significant improvements in foot pain ( $P=0.001$ ) and foot function ( $P=0.047$ ). Although there was improvement in pain VAS, it was not significant.

Elizondo-Rodriguez et al. conducted a prospective, experimental, randomized, double blinded, controlled clinical trial comparing BTX-A and intralesional steroids for PF treatment.<sup>14</sup> 36 patients were randomly divided into the BTX-A group (19 patients) or the steroid group (17 patients). The BTX-A group was injected with a total of 250U (1 mL): 100U (1.0 mL) into each muscle belly of the gastrocnemius and 50U (0.5 mL) into the soleus. The steroid group was injected with a combination of 2% lidocaine (2ml) and 8 mg of dexamethasone (2mL). Both groups started plantar fascia stretching exercises 7 days posttreatment. Compared to the steroid group, the BTX-A group showed: a significant decrease in pain VAS starting from visit 3 (a total of 6 visits), a statistical difference in the Wilcoxon rank test for pain between visits, and a statistical improvement in the

Maryland Foot and Ankle, AOFAS, and FADI scores starting from visit 2.

Ahmad et al. conducted a prospective, randomized, controlled study that included a blinded trial.<sup>15</sup> 50 patients with acute or chronic PF were randomly assigned into the BTX-A group or the placebo group. The BTX-A group was injected with 100U (1 mL) of BTX-A into the medial aspect of the calcaneus where the plantar fascia was proximal. The control group received the same volume of saline injected into the same location. Both groups received injections under EMG guidance. All patients started a supervised physical therapy program for at least 6 weeks after the injection. At 6 months posttreatment, the BTX-A group had an increase in FAAM scores from 36.3 to 73.8 and a decrease in VAS pain score from 7.2 to 3.6. Compared with the placebo group, the BTX-A group had scores that were significantly better ( $P=0.01$ ) at 6 months posttreatment. At 12 months posttreatment, the BTX-A had a further increase in FAAM score to 79.5 and a further decrease in VAS pain score to 2.9. Both measure outcomes were significant ( $P=0.01$ ) when compared to the placebo group, but not significantly different when compared to 6 months posttreatment.

Peterlein et al. conducted an 18-week, prospective, placebo-controlled, double-blind, phase II study in multiple centers.<sup>16</sup> 40 patients with refractory PF were randomized in a double-manner into the BoNT-A group or the saline placebo group. The

BoNT-A group received 200U (2 mL) in 2 mL 0.9% saline solution in a fan-shaped manner into the origin of the plantar fascia. The saline placebo group received the same volume of saline placebo in the same manner. At 6 weeks posttreatment, both groups had a decrease in pain intensity scores on both rest and movement; this decrease went from the initial injection through the end of the study. At 18 weeks posttreatment, the mean decrease in pain intensity for the BoNT-A group was slightly greater than that of the placebo group. However, there was no statistical difference in pain intensity scores between the groups. MPSS scores remained unchanged for a majority of patients in both groups. Additionally, there was no statistical difference between groups in mean change from baseline pain, pressure threshold, dorsal extension, and plantar flexion scores. Also, there were mild to moderate adverse effects experienced by 9 patients in the BoNT-A group and 8 patients in the placebo group. Severe adverse effects presented in 2 patients of the BoNT-A group; however, these adverse effects were concluded to be unrelated to the study's treatment. Lastly, there was no change in muscular strength in both groups.

Zhang et al. conducted a systematic and meta-analysis to analyze the efficacy of BoNT-A in reducing chronic musculoskeletal pain.<sup>17</sup> Studies were considered if they met the inclusion criteria: 1) were randomized controlled trials and 2)

evaluated the efficacy of BoNT-A in reducing pain in the following: PF ( $n=1$ ), tennis elbow ( $n=2$ ), shoulder pain ( $n=1$ ), whiplash ( $n=3$ ), and myofascial pain ( $n=8$ ). 706 patients were included: 390 in the BoNT-A group and 316 in the control group. There was significant reduction in pain in the BoNT-A group over the control group (SMD = -0.27, 95% CI: -0.44 to -0.11). In the PF group ( $n=27$ ), BoNT-A was shown to be effective in reducing pain associated with PF (SMD = -1.04, 95% CI: -1.68 to -0.40). The meta-analysis revealed that those who received 25U (0.25 mL) or more of BoNT-A benefited (SMD = -0.57, 95% CI: -0.92 to -0.22). Additionally, studies with short-term follow-up had no significant pain decrease with BoNT-A (SMD = -0.15, 95% CI: -0.50 to 0.2). The most significant pain decrease with BoNT-A occurred in studies that had 5-8 weeks follow-up (SMD = -0.94, 95% CI: -1.49 to -0.39).

Tsikopoulos et al. conducted a systematic review and meta-analysis to examine the efficacy of injection therapies for PF.<sup>18</sup> Studies were considered if they met the inclusion criteria: 1) were randomized controlled trials and 2) compared the effects of 2 different injection treatments for PF. 22 randomized controlled trial studies were ultimately selected for analysis. The 22 studies yielded a total of 1216 patients, but only 1197 patients were used in the meta-analysis. The meta-analysis revealed that at 0-2 months

posttreatment, the dehydrated amniotic membrane, PRP and BTX-A injections were significantly better than corticosteroids. Furthermore, BTX-A intervention had a significant pain relief compared to placebo groups at 0-6 months.

## DISCUSSION

### *Botulinum toxin vs. Placebo (saline)*

In a randomized, double blinded, placebo controlled study by Ahmad et al, it was found that there was significant improvement with injecting IncobotulinumtoxinA (IBTA) versus placebo<sup>17</sup>. The IBTA injection was 1 mL of 100U of IBTA and the placebo was saline. These were injected into the affected plantar fascia at the flexor digitorum brevis, under EMG guidance. Both groups underwent physical therapy for 6 weeks and were instructed to wear off the shelf arch supports as well.

The pre and post injection pain and disability was measured with both the Foot and Ankle Ability Measures and a visual analog scale (VAS) of 0-10. The patients presented at 6 weeks, 12 weeks, 6 months, and 12 months after the injection, and throughout the entire monitoring period, the IBTA group maintained significant improvement ( $P=0.01$ ) whereas the control group did not have significant improvement in pain at any point ( $P=0.32$ ).<sup>17</sup>

Not only was the pain and function significantly increased in the IBTA group, but the need for surgery was also significantly less. In the placebo group, 12% of the patients underwent surgery to correct their pain and dysfunction as it was remarkably severe, whereas none of the patients in the IBTA group underwent surgery ( $P=0.005$ ). The inherent safety from the potential prevention of surgical procedures and their possible sequelae is one of the major benefits to using botulinum toxin as a treatment.

Although this was done with a treatment versus a placebo, it is quite clear from the results that the toxin fared significantly better than a saline injection and the pain reduction and improvement in quality of life is dependent on the toxin itself being injected.

### *Botulinum toxin vs. corticosteroid*

Botulinum toxin compared to corticosteroids also yielded positive results. In a study by Diaz-Llopis et al, a total of 70U of BTX-A total was used (40U injected into the point of maximal tenderness and 30U injected between one inch distal to the authors' description of the talar insertion of the plantar fascia and the midpoint of the plantar arch).<sup>12</sup> The corticosteroid group received 12 mg of betamethasone acetate and disodium phosphate in the same area near the calcaneal tuberosity and a small subcutaneous injection of saline performed in the middle of the medial fascia to keep the number of

injections between both the Botulinum toxin group and the steroid group identical. In both the Botulinum toxin and steroid groups, pain was evaluated at one month after treatment (one therapeutic dose of the Botulinum toxin and one therapeutic dose of the corticosteroid, respectively), and both groups had a significant improvement in pain and disability. At this stage, the patients in the Botulinum toxin group reported lower pain: 63.30 (an increase from 29.06 before treatment) on the pain Foot Health Status Questionnaire (FSHQ) with a SD of 21.90, whereas in the corticosteroid group, they reported a 53.73 (an increase from 31.61 before treatment) on the FSHQ with a SD of 31.18, both of these values reported a  $P < 0.001$ . There was a similar improvement in foot function (70.98 with a SD of 26.41 for the BTX-A group and 63.62 with a SD of 24.12 for the corticosteroid group,  $P < 0.001$ ). However, at 6 months, only BTX-A had significant improvement in pain and disability ( $P < 0.001$ ). At 6 months, the BTX-A group reported a 75.71 score on the pain FHSQ (with a SD of 24.14) and 84.37 (with a SD of 23.95) on the foot function FHSQ, both of these with  $P < 0.001$ . The corticosteroid group reported a 54.61 (SD of 33.11) for the pain FHSQ and 56.82 (SD of 30.73) for the foot function FHSQ. At this point, BTX-A was significantly more effective than the corticosteroid ( $P = 0.001$ ) in terms of foot pain reduction and foot function improvements.

There were more therapeutic failures (self-reported by patients who had no improvement in pain one month after their injection) in the group that received the betamethasone (35%) than BTX-A (14%) ( $P < 0.001$ ).<sup>12</sup>

Another study, done by Elizondo-Rodriguez et al, studied the effects of BTX-A compared to 8mg of dexamethasone isonicotinate. However, in this case, the BTX-A was injected into the gastrocnemius-soleus complex, whereas the steroid was injected into the medial plantar surface of the foot.<sup>14</sup> There was 250U of BTX-A total injected, 100U into the lateral and medial muscle belly and 50U into the soleus. There was 8mg of dexamethasone used.

At the first visit, 15 days after the injections, there was an equal decrease in pain and disability in both groups, however, at the 1-month post-treatment evaluation, there was a statistically significant ( $P = 0.004$ ) decrease in pain in the BTX-A group (VAS score: 1.9 +/- 1.51) as compared to the steroid group (VAS score: 3.4 +/- 1.24). The 2<sup>nd</sup> month, 4<sup>th</sup> month, and 6<sup>th</sup> month follow ups showed a similar trend, with the BTX-A group being more pain free and with less disability. There was still improvement at the conclusion of the study in both groups, which was statistically significant for the BTX-A group ( $P = 0.0005$ ) but with the steroid group, it was not significant ( $P > 0.05$ ). At the end of the study, the differences in pain reported by the

subjects is as followed: BTX-A VAS: 1.1 +/- 1.5, steroid VAS: 3.8 +/-1.15.<sup>14</sup>

Both of these studies imply that one injection of botulinum toxin compared to one injection of various steroids is more effective at reducing pain, disability, stress, and increasing quality of life.

#### *Botulinum toxin with no control group*

When compared to no control group, Placzek et al found that patients who experienced chronic PF which did not respond to conservative treatment saw a significant reduction in pain 6 weeks after the injection of Botulinum Toxin A (BTX-A), which was maintained to the 1 year-post injection mark.<sup>11</sup> The injections were done with 200U of BTX-A in a 2.0 mL saline solution. This was injected subfascially in 4 directions through one injection puncture

A significant reduction in pain was noted during weight bearing (to 50% of what it was pre injection) at the 6-week mark ( $P<0.015$ ).<sup>11</sup> There were no adverse events reported. Patients were satisfied with the results and none pursued further treatment of any sort.

What this study and follow-up show, is that a single BTX-A injection can reduce pain in chronic PF patients to a significant degree. This can be a cost effective method, as it is less expensive than extracorporeal shockwave therapy and only requires one injection, and thus, one doctor's

visit. Unfortunately, this level of evidence is not particularly high, but the good results show promise for a potential much larger study.

#### *Adverse Events*

In all of the studies where botulinum toxin was used to treat PF, there were no serious adverse effects reported, though there is an FDA mandated black box warning associated with the use of botulinum toxin. This warning "highlights the possibility of experiencing potentially life threatening distant spread of toxin effect from the injection site after local injection"<sup>6,7</sup> There have been serious side effects from systemic spread of local BTX injections such as paralysis, dysphagia, respiratory tract infections, or potentially death. There have been mild to moderate adverse events reported when BTX is used for other treatment modalities, therefore, these could happen to potential patients who have chronic PF. There can be mild post-injection pain, erythema, ecchymosis, and transient numbness around the site. There have also been reports of temporary paralysis of nearby musculature, however this usually resolves fairly quickly.<sup>6,7</sup>

The application of BTX is also contraindicated in patients who have any preexisting motor neuron disease, myasthenia gravis, neuropathies, a history of reaction to toxin or albumin, or infection at the injection site. There are also several medications, which can potentiate or inhibit the effects of



the toxin. Aminoglycosides increase the effect and fluoroquinolones may reduce the effect.

## CONCLUSION

Based on available data, botulinum toxin has the potential to be an effective treatment for patients with chronic PF. The preliminary results show the potential to be a very successful treatment modality, though there needs to be more data collected in larger scale trials. However, there is an FDA black box advisory which physicians should be aware of before using it as a treatment modality. Though this risk is very low for the dosage and number of injections for treating PF, one must use caution when administering botulinum toxin. These systemic side effects can be as mild as generalized muscle weakness or can be potentially fatal.<sup>20</sup>

Further studies should include a control group that receives multiple corticosteroid injections, spaced out four to six weeks apart, as it is commonly accepted that steroids lose their efficacy after four to eight weeks and numerous injections could enhance the clinical efficacy.<sup>19</sup> There should also be comparisons of injecting different amounts of BTX to different sites (the gastrocnemius-soleus complex versus the plantar aspect of the foot) to see if one site is more effective than the other. The last limitation found was that each study used different scales to analyze pain and disability; though several did use

the VAS 1-10 scale, it would be more consistent to use comparable methods.

After this thorough literature review, the use of botulinum toxin for treating chronic PF seems promising and relatively safe, despite the FDA's mandated boxed warning. After more trials take place to cement its efficacy, perhaps botulinum toxin will be a mainstay treatment for PF in the future and can be another conservative option before needing surgery to correct the condition.

## AUTHORS' CONTRIBUTIONS

The authors contributed equally to the production of the article. All conceived the topic, performed initial literature reviews, evaluated abstracts, authored introduction, results, discussion, and conclusions. All authors drafted, read, reviewed and agreed upon the final manuscript.

## STATEMENT OF COMPETING INTERESTS

The authors declare that they have no competing interests associated with this manuscript.

## REFERENCES

1. Cutts, S., Obi, N., Pasapula, C., and Chan, W. Plantar fasciitis. *Annals: The Royal College of Surgeons of England* 2012; 94 (8): 539-542.

2. Babcock, MS., Foster, L., Pasquina, P., and Jabbari, B. Treatment of Pain Attributed to Plantar Fasciitis with Botulinum Toxin A. *American Journal of Physical Medicine and Rehabilitation* 2005; 84 (9): 649-654
3. Chen, YN., Chang CW., Li, CT., Chang, CH., and Lin, CF. Finite Element Analysis of Plantar Fascia During Walking: A Quasi-Static Simulation. *Foot & Ankle International* 2015; 36 (1): 90-97.
4. Seyler, T., Smith, B., Marker, D., Ma, J., Shen, J., Smith, T., Mont, M., Kolaski, K., and Koman, A. Botulinum Neurotoxin as a Therapeutic Modality in Orthopaedic Surgery: More Than Twenty Years of Experience. *The Journal of Bone and Joint Surgery-American Volume* 2008; 90 (4): 133-145.
5. Nigam, PK., and Nigam, A. Botulinum Toxin. *Indian Journal of Dermatology* 2010; 55 (1): 8-14.
6. U. S. Food and Drug Administration: Drug Safety and Availability. *Information for Healthcare Professionals: OnabotulinumA, AbobotulinumA, and RimabotulinumB* 2009. Retrieved May 06, 2017 from <https://www.fda.gov/Drugs/DrugSafety/PostmarketDrugSafetyInformationforPatientsandProviders/DrugSafetyInformationforHealthcareProfessionals/ucm174949.htm>
7. Allergan Inc. and the U.S. Food and Drug Administration. *Botox Medication Guide* 2011. Retrieved May 08, 2017 from [https://www.accessdata.fda.gov/drugsatfda\\_docs/label/2011/103000s5232lbl.pdf](https://www.accessdata.fda.gov/drugsatfda_docs/label/2011/103000s5232lbl.pdf)
8. Chou LW, Hong CZ, Wu ES, Hsueh WH, Kao MJ. Serial ultrasonographic findings of plantar fasciitis after treatment with botulinum toxin a: a case study. *Arch Phys Med Rehabil.* 2011 Feb;92(2): 316-9..
9. Huang YC, Wei SH, Wang HK, Lieu FK. *J Rehabil Med.* 2010 Feb;42(2):136-40.
10. Placzek R, Deuretzbacher G, Meiss AL. *Clin J Pain.* 2006 Feb; 22(2):190-2.
11. R Placzek, G Deuretzbacher, F Buttgereit, and A Meiss. Treatment of chronic plantar fasciitis with botulinum toxin A: an open case series with a 1 year follow up. *Ann Rheum Dis.* 2005 Nov; 64(11): 1659-1661. doi: 10.1136/ard.2005.035840
12. Díaz-Llopis IV, Rodríguez-Ruiz CM, Mulet-Perry S, Mondéjar-Gómez FJ, Climent-Barberá JM, Cholbi-Llobel F. Randomized controlled study of the efficacy of the injection of botulinum toxin type A versus corticosteroids in chronic plantar fasciitis: results at one and six months. *Clin Rehabil.* 2012 Jul;26(7):594-606.
13. Díaz-Llopis IV, Gómez-Gallego D, Mondéjar-Gómez FJ, López-García A, Climent-Barberá JM, Rodríguez-Ruiz CM. Botulinum toxin type A in chronic plantar fasciitis: clinical effects one year after injection. *Clin Rehabil.* 2013 Aug;27(8): 681-5. doi: 10.1177/0269215512469217.
14. Elizondo-Rodriguez J, Araujo-Lopez Y, Moreno-Gonzalez JA, Cardenas-Estrada E, Mendoza-Lemus O, Acosta-Olivo C. A comparison of botulinum toxin a and intralesional steroids for the treatment of plantar fasciitis: a randomized, double-blinded study. *Foot Ankle Int.* 2013 Jan; 34(1):8-14.
15. Zhang, T., Adatia, A., Zarin, W. et al. The efficacy of botulinum toxin A in managing chronic musculoskeletal pain: a

- systematic review and meta analysis. *Inflammopharmacol* (2011) 19:21. doi:10.1007/s10787-010-0069-x
16. Peterlein, Christian-Dominik MD; Funk, Julia F. MD; Hölscher, Alice MD; Schuh, Alexander MD; Placzek, Richard MD. Is Botulinum Toxin A Effective for the Treatment of Plantar Fasciitis? *Clinical Journal of Pain*. 2012 July/August;28(6): 527-533 doi: 10.1097/AJP.0b013e31823ae65a
  17. Ahmad J, Ahmad S, Jones K. Treatment of Plantar Fasciitis With Botulinum Toxin: A Randomized, Controlled Study. *Foot Ankle Int*. 2017 Jan 38(1): 1-7
  18. K Tsikopoulos, H Vasiliadis, D Mavridis. Injection therapies for plantar fasciopathy ('plantar fasciitis'): a systematic review and network meta-analysis of 22 randomized controlled trials. *Br J Sports Med*. 2016 Nov 3:50(22): 1367-1375
  19. Teck Wee Andrew Ang. The effectiveness of corticosteroid injection in the treatment of plantar fasciitis. *Singapore Med J*. 2015 Aug; 56(8): 423-432.
  20. Crowner B, Torres-Russotto D, Carter A, Racette B. Systemic Weakness After Therapeutic Injections of Botulinum Toxin A: A Case Series and Review of the Literature. *Clinical Neuropharmacology*. 2010 Sep-Oct; 33(5): 243-247.

# Review of New and Innovative Direct Plantar Plate Surgical Interventions via Dorsal and Plantar Surgical Approaches

*Shalanda L. Hall, RN, BSN, Chengcheng Tu, MPH, BS, & Nader F. Ghobrial, MBBCH, MS*

## Abstract

### Introduction

Plantar plate dysfunction is one of the common causes of metatarsalgia. The purpose of this review is to critique two incisional approaches: dorsal and plantar. In addition, it is aimed to evaluate the technologically advanced reparative instruments, produced by ArthroCare Corp and Arthrex Inc., utilized in direct plantar plate repair surgeries.

### Study Design

Qualitative Systematic Review of Literature

### Methods

A comprehensive literature review was conducted utilizing PubMed and Sage databases. The MeSH terms “plantar plate tears” were utilized. The inclusion criteria included studies printed in English and published between December 2011 and December 2016 with full-text availability. The exclusion criteria were cadaveric studies, non-English articles, and publications before December 2011.

### Results

The search generated a total of 319 articles, with 43 articles qualified for the initial abstract review taking into consideration of inclusion and exclusion criteria. A careful review of abstracts resulted in 9 articles to be included in the full-text review. 5 devices and 4 techniques for the plantar plate repair were evaluated; however, literature denies superiority among them and demonstrates functional improvement and relief in pain in all techniques.

### Discussion

To prevent plantar plate tears from progressing to complex digital deformities, it is important for clinicians to diagnose plantar plate tears in the early stages by completing a thorough history and physical examination. If examiners suspect a grade 0 plantar plate tear, conservative treatments should be attempted. If conservative treatments fail, clinicians should confirm the diagnosis of plantar plate tear with MRI. If a plantar plate tear is confirmed, surgery is indicative. The new assistive devices will help improve the outcome of the surgery.

### Key Words

metatarsalgia, plantar plate repair, plantar plate dysfunction, diagnostic imaging

*Level of Evidence: 4*

## INTRODUCTION

It is commonly known that the plantar plate, a thick fibrocartilaginous structure, is the major static stabilizing anatomical structure of lesser metatarsophalangeal joints (MTP joint). The plantar plate is made up of 75% type I collagen and 21% type II collagen. The type I and II collagen are woven together allowing the plantar plate to function as a cushion to support compressive forces of the forefoot during heel lift of the gait cycle. The plantar plate is an extension of the plantar fascia, and on average, it is 2-cm in length, 1-cm in width, and 2-5-mm in thickness.<sup>1</sup> It originates on the proximal neck of the metatarsal metaphysis and inserts distally into the plantar base of the proximal phalanx in close proximity to the phalangeal articular cartilage. The dense portion of the plantar plate

is at its origin and its medial and lateral borders. In contrast, the unsubstantial portion of the plantar plate is at its insertion at the proximal phalanx via one or two bands. This thinner portion of the plate allows for more mobility of the lesser MTP joints, but it is also at an increased risk for degenerative tearing. According to Nery and colleagues, in their prospective series of 55 lesser MTP joints, plantar plate insufficiency occurred 64% at the second MTP joint, 32% at the third MTP joint, and 4% at the fourth MTP joint.<sup>2</sup>

Many factors play a role in plantar plate deterioration and instability. Plantar plate dysfunction frequently occurs in perimenopausal women, women with sedentary lifestyles, and women with a history of wearing high heeled shoes.<sup>1</sup> On the other hand, young male athletes are commonly

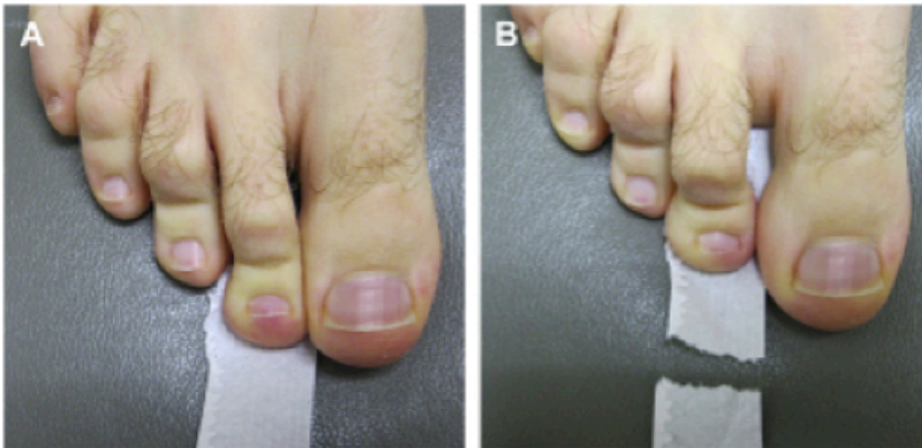

Figure 1: Paper pull-out test. (A) A piece of narrow paper is placed vertically underneath the tip of the affected digit. (B) The paper is ripped when pulled out by the examiner indicating the “paper pull-out test” is negative and confirms the presence of digital purchase.<sup>1</sup>

Table 1 Clinical staging of examination for second MTP joint instability		
Grade	Alignment	Physical Examination
0	No MTP joint malalignment; prodromal phase with pain but no deformity	MTP joint pain, thickening or swelling of the MTP joint, diminished toe purchase, negative drawer
1	Mild malalignment of MTP joint; widening of the webspace, medial deviation	MTP joint pain, swelling of MTP joint, reduced toe purchase, mildly positive drawer (<50% sublaxable)
2	Moderate malalignment; medial, lateral, dorsal, or dorsomedial deformity, hyperextension of the MTP joint	MTP joint pain, reduced swelling, no toe purchase, moderately positive drawer (>50% sublaxable)
3	Severe malalignment; dorsal or dorsomedial deformity; the second toe can overlap the hallux; may have flexible hammertoe	Joint and toe pain, little swelling, no toe purchase (dislocatable MTP joint), flexible hammertoe
4	Dorsomedial or dorsal dislocation; severe deformity with dislocation, fixed hammertoe deformity	Joint and toe pain, little if any swelling, no toe purchase, dislocatable MTP joint, fixed hammertoe deformity

**Table 1:** The severity of the MTP joint instability defined by a 0-4 scale staging system.<sup>1</sup>

diagnosed with plantar plate dysfunction due to trauma. Other common causes of plantar plate injury include MTP joint overload as a result of short first metatarsal bone, long second metatarsal bone, hallux abductovalgus, hallux rigidus, pes valgus, or first ray hypermobility.<sup>1</sup> The Fleischer et al. retrospective case-control study concluded that a long second metatarsal with a metatarsal protrusion index less than (-)4-mm was a significant risk factor for plantar plate pathology.<sup>3</sup> Moreover, those with rheumatoid arthritis and other inflammatory arthropathies commonly have plantar plate dysfunction.<sup>1</sup>

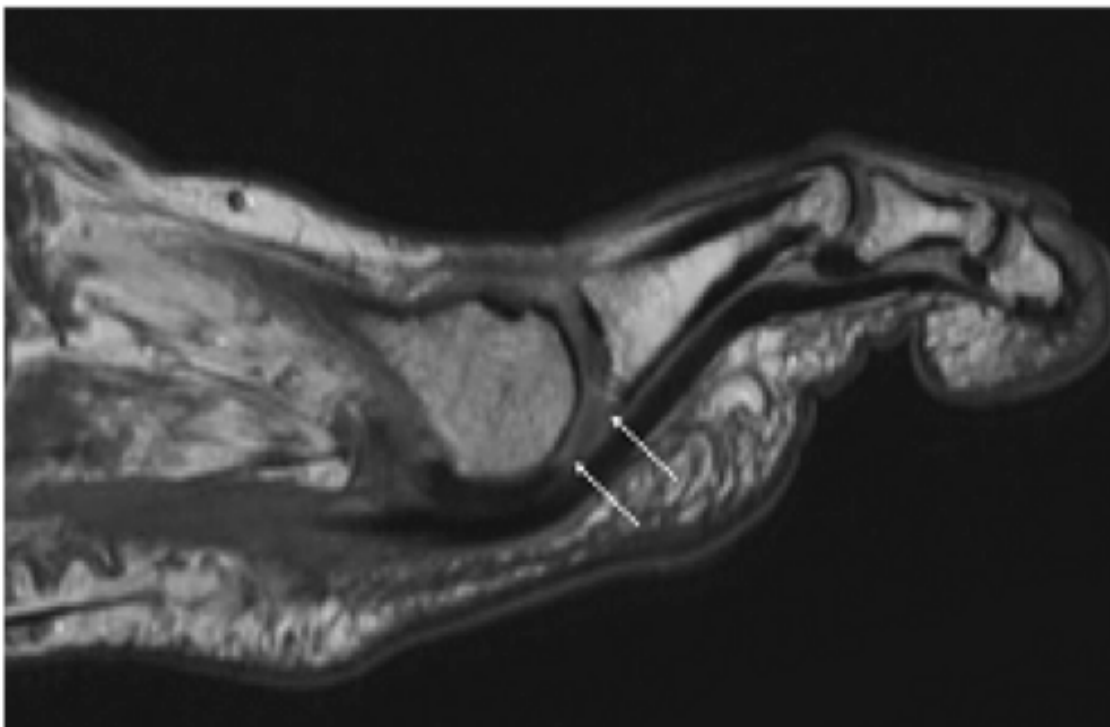
Initially, when the plantar plate becomes attenuated, the patient may experience pain distal to the lesser plantar metatarsal head and more pain with ambulation. In addition, edema

generally occurs under the metatarsal head. According to Doty et al., the clinician can use the “paper pull-out test” to evaluate the digit’s position, strength, and purchase (Figure1).<sup>1</sup> The “paper pull-out test” is performed by placing a piece of narrow paper vertically underneath the tip of the affected digit. The examiner attempts to pull out the paper while the patient resists by plantarflexing the affected toe. If the paper is pulled out intact, the “paper pull-out test” is positive and confirms the absence of digital purchase.<sup>1</sup> In addition Doty et al. suggest the drawer test is a definitive sign of MTP joint instability. The drawer test is performed by the clinician holding the MTP joint in a neutral position and then applying vertical force in a dorsal direction. MTP joint instability is indicated if the vertical force causes pain and

subluxation at the MTP joint. In order to prevent further progression of plantar plate dysfunction, the clinician can effectively use their clinical assessment along with a grading system to diagnose and implement a treatment plan (Table1).<sup>1</sup>

According to Flint et al. and other clinicians, plantar plate insufficiency grade 0 and I injuries are treated with conservative measures and/or microdebridement via radiofrequency shrinkage. Grades II and III injuries are treated with Weil Osteotomy and direct PPR, and grade IV injury is treated with Weil osteotomy and flexor tendon transfer.<sup>6</sup> Conservative treatments are implemented for grade 0 plantar plate tears with the purpose of slowing down the progression of

the deformity and to relieve the pain. The clinician may suggest footwear to help decrease dorsiflexion at the MTP joint. The types of footwear include shoes with a low heel, wide toe box, stiff sole, and/or rocker bottom. Other conservative treatments which help to reduce pain and malalignment is padding, strapping, and splinting. In addition pharmacological treatments, such as NSAIDs and steroid injections, help to lessen pain. Clinicians should note that steroid injections at the MTP joint may cause rapid progression of plantar plate dysfunction. If conservative measurements do not prevent the progression of the plantar plate injury, the MTP joint will deviate on the sagittal and transverse planes resulting



**Figure 2:** MRI is indicating complete plantar plate tear (white arrows).<sup>1</sup>



in dorsiflexion and medial deviation, respectively.<sup>1</sup>

When conservative treatments and/or microdebridement fail to stop further aggravation, surgical options should be explored. Before surgical intervention, Magnetic Resonance Imaging (MRI) must be performed to definitively diagnose plantar plate tear.<sup>4</sup> By using MRI and intraoperative findings to stage the plantar plate tear, the clinician can confidently determine the best surgical option. Approximately 20 years ago, clinicians used indirect surgical plantar plate repair methods to improve patients' joint stability, pain, and toe purchase.<sup>1</sup> The indirect surgical methods included: soft tissue releases, balancing procedures, extensor and flexor tendon transfers, and periarticular osteotomies.<sup>1</sup> However, many surgeons recognized that the indirect methods failed to improve the patient's signs and symptoms compared to the direct repair of the attenuated plantar plate.<sup>1</sup> Currently, many surgeons utilize the direct Plantar Plate Repair (PPR) surgical method, via a dorsal and/or plantar approach, to repair the plantar plate itself. It is believed that the direct PPR surgical method has a more favorable outcome than the indirect surgical PPR.<sup>1</sup> The purpose of this review is to analyze surgical incisional approaches, dorsal and plantar, for direct PPR. In addition, this review will critique recent advanced reparative instruments, produced by ArthroCare Corp and Arthrex Inc, used for direct PPR.

## METHODS

A systematic review of the literature was conducted using both PubMed and Sage databases. A search of "plantar plate tears" was performed using the "and / or" operators (i.e. ("plantar plate"[MeSH Terms] OR ("plantar"[All Fields] AND "plate"[All Fields]) OR "plantar plate"[All Fields]) AND ("tears"[MeSH Terms] OR "tears"[All Fields] OR "tear"[All Fields] OR "lacerations"[MeSH Terms] OR "lacerations"[All Fields])) AND ("full text"[sb] AND "2011/12/13"[PDat] : "2016/12/10"[PDat]) in PubMed (see Chart 1). In addition, a search of "plantar plate tears" in Foot & Ankle Specialist in Sage Journals was performed. The inclusion criteria included studies printed in English, published between December 2011 and December 2016, and full-text availability. The exclusion criteria eliminated non-English language articles, cadaveric or animal studies, and studies before December 2011. The primary search of 2 databases resulted in a total of 43 articles, of which 28 articles were from PubMed, and 15 articles were from Sage Journals. After an initial review of those abstracts, 9 articles were qualified for a full-text review, among which 7 articles were from PubMed, and 2 articles were from Sage Journals. Three investigators performed a careful review of the content of the articles, which resulted in a final inclusion of 9 articles.



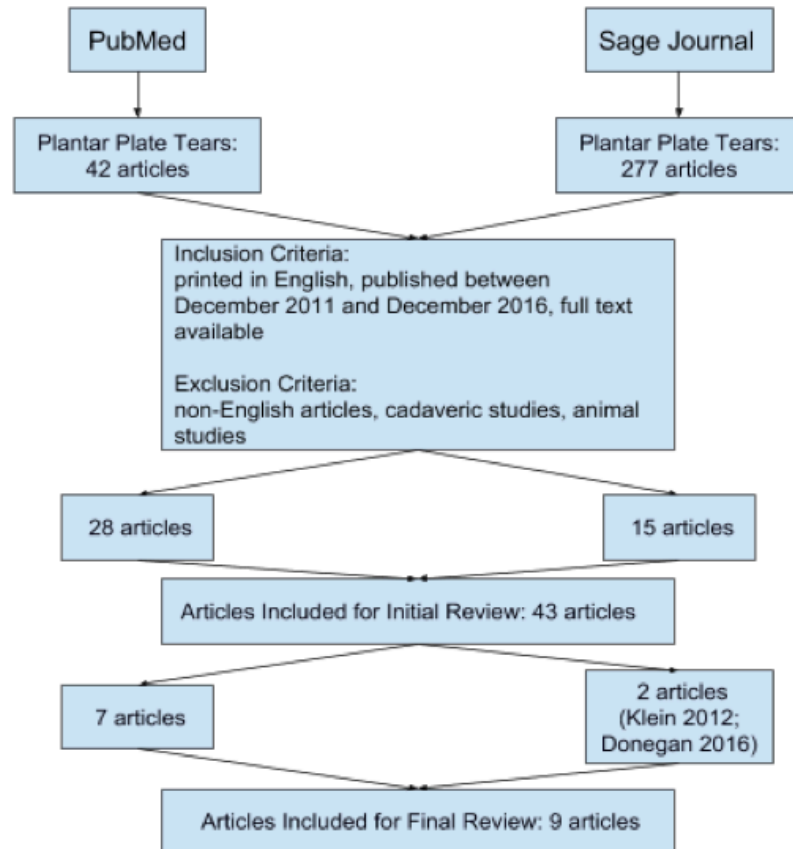


Figure 3: Acquisition of articles from PubMed and Sage Databases based on inclusion and exclusion criteria (9 articles were selected)

## RESULTS

The surgical exposure to repair the plantar plate can be done plantarly and/or dorsally. There are 3 companies: ArthroCare Corp, Arthrex, Inc, and Smith & Nephew, Inc.; which produce advanced suture passer instruments, fiber suture tape, and interference screw fixations. However, only 2 out of 3 companies' devices were evaluated due to the lack of review articles for the HAT-trick device from Smith & Nephew (Smith & Nephew, London, UK). Three case series and one report were evaluated for the following devices: SmartStitch

device (ArthroCare Corp, Austin, TX), Complete Plantar Plate Repair™ System (CPR, Arthrex Inc., Naples, FL), Mini Scorpion™ DX (CPR, Arthrex Inc., Naples, FL), FiberTape® (Arthrex Inc, Naples FL.) and SwiveLock interference screw® (Arthrex, Inc.) (see Table 2 and Table 3).

Weil et al. conducted a retrospective case series for direct PPR of the second MTP joint with a Weil osteotomy of the second metatarsal via a dorsal incision and fixated with a 2.5-mm threaded head screw. An instrument called a SmartStitch device

(ArthroCare Corp, Austin, TX) was utilized to grasp the plantar plate and a mattress stitch was created with nonabsorbable suture. In addition, hallux valgus, hammer toe, and bunionette correction surgeries were done concomitantly. The study included 15 feet of 13 patients diagnosed with MTP instability that had failed conservative management for at least 3 months. Neurological problems and rheumatoid arthritis were ruled out as causative factors for plantar plate insufficiency. Preoperatively, weight-bearing dorsoplantar, lateral, and medial oblique radiographic images were taken and evaluated. The average follow-up period after surgery was 22.5 months and at this time 12 of the 15 cases reported “satisfied” or “very satisfied” outcomes. Despite the fact that 3 cases reported “not satisfied” with the outcome, 2 of the 3 cases indicated an improvement in their function and pain relief. In addition at follow-up, the average visual analog scale (VAS) score was 7.3 preoperatively and 1.7 postoperatively. The final postoperative AOFAS LMIS score was 85.7 out of 100. Complications from the procedure included three patients reporting painful hardware and one with metatarsalgia. It was concluded by the authors that dorsal anatomical plantar plate repair together with a Weil metatarsal osteotomy, more efficiently reduces the MTP subluxation than any other technique.<sup>5</sup>

Flint et al. conducted a prospective case series to evaluate PPR via a dorsal approach. A Weil metatarsal osteotomy and direct repair of the plantar plate using a Complete Plantar Plate Repair™ System (CPR, Arthrex, Naples, FL), was performed for 138 toes (97 feet).<sup>6</sup> A Weil metatarsal osteotomy was not required for 2 toes and was repaired using an inline suture passer, the Viper™ Implant System (CPR, Arthrex, Naples, FL). Patients were followed for 12 months and data collected preoperatively and postoperatively demonstrated 80% “good” to “excellent” satisfaction scores. This improvement is further illustrated by the decrease in VAS pain score from 5.4 to 1.5 and the increase in AOFAS scores from 49 to 81 points following surgery. Fifteen toes underwent isolated direct PPR, and the remaining patients underwent multiple foot procedures (i.e. 48% hammer and mallet toe corrections; 57% hallux valgus and hallux rigidus management). The authors determined that for grade IV plantar plate tears (complete tear of the plantar plate with loss of tissue integrity) a flexor tendon transfer is the procedure of choice due to lack of adequate tissue to gain suture purchase. A flexor tendon transfer provides a tissue substitute for the irreparable plantar plate with the potential risk of collagen patch formation in the plantar area.<sup>6</sup>

Donegan et al. conducted a retrospective case series to analyze concurrent plantar and dorsal incisions

with a flexor digitorum longus (FDL) tendon sheath transfer without hardware for PPR and evaluated the viability of this novel low-cost technique.<sup>7</sup> The Mini Scorpion™ DX (CPR, Arthrex, Naples, FL) suturing assistive device was used for direct PPR. The FDL tendon sheath was transferred dorsally, proximal to the 2nd proximal interphalangeal joint (PIPJ) arthrodesis site, and the plantar plate was reinforced by suturing the FDL side to side. The study included 10 patients (10 feet) and the average follow-up period was 3.7 months. All 10 cases were successful with complete wound healing, desired alignment, resolution of pain, and no recurrences were noticed in the follow-up period. There are several benefits from this technique: direct visualization to obtain precise correction, potential avoidance of a distal metatarsal osteotomy, reduced incidence of “floating toe”, and a

robust repair of the plantar plate even if there is a lack of residual tissue for direct repair. The major concern with this technique is the viability of the digit from devascularization due to a combined dorsal and plantar approach.

7

Sung reported direct PPR of the lesser MTP joints via a dorsal incision using a flat knotless synthetic FiberTape® suture with high tensile strength. This material is composed of ultrahigh-molecular-weight polyethylene (UHMWPE) and polyester yarns braided over a core of fiber wire (UHMWPE and polyester braided over a UHMWPE core, Arthrex, Inc). The FiberTape® suture was placed at the plantar aspect of the unstable MTP joint and secured to the metatarsal head using 3.5-mm SwiveLock interference screw® (polyetheretherketone Arthrex, Inc, Naples, FL). A second 3.5-mm screw

Direct PPR Technique	Author (Year)	Study Type	Patient (feet)	Pros and Cons	Study Limitations
Dorsal approach with Weil osteotomy and suture repair (device: Arthrocare Smart StitchDevice)	LW (2011) <sup>5</sup>	Case series	13 (15)	Pros: Patients allowed to ambulate immediately. Improved postoperative pain and functioning. Cons: Metatarsalgia, Painful hardware and hardware failure.	Only 13 patients in the study; 3 of them reported not satisfied. One of them returned back for screw removal
Dorsal approach with Weil osteotomy and suture repair (device: CPR and Viper, Arthrex, Inc.)	FW (2016) <sup>6</sup>	Case series	91 (97)	Pros: signs and symptoms improvement Cons: decrease MPJ range of motion, floating toe due to concurrent osteotomy	Only 11 patients underwent isolated PPR procedure Did not state specifically which CPR device was used
Dorsal and plantar approach with flexor tendon reinforcement (device: Mini Scorpion, Arthrex, Inc.)	RD (2016) <sup>7</sup>	Case series	10 (10)	Pros: better visualization, repairment possible with minimal residual tissue Cons: devascularization of skin	Only 10 patients in the study; short follow-up time
Dorsal approach with Interference fixation (device: synthetic fiber tape suture and SwiveLock suture anchor)	WS (2015) <sup>8</sup>	Report	N/A	Pros: favorable with no or little remnants of plantar plate. Cons: transfer metatarsalgia, inflammation and hardware failure.	Proper technique for placement and the device type are the main determinants for successful functioning of the implant
Smith and Nephew HAT-trick device	N/A	N/A	N/A	N/A	N/A

Table 2. Direct PPR Technique Summary

Device	Device Features
1. Smart Stitch (Arthrocare, Corp)	*Suture passer *No longer available
2. Complete Plantar Plate Repair System (CPR™, Arthrex)	*Treats plantar plate tears and attenuation from a dorsal incision *Includes 1. CPR Micro SutureLasso™ 2. Mini Scorpion™ Dx 3. Viper™ Implant system
2. Viper™ Implant System (CPR, Arthrex)	*Suture passer *Direct PPR with or without an osteotomy from a dorsal incision under direct visualization
3. Mini Scorpion™ (CPR, Arthrex)	*Suture passer *Direct PPR with an Osteotomy from a dorsal incision under direct visualization or “blind” passes through the plantar plate tissue.
4. Synthetic fiberTape® suture (Arthrex, Inc.)	*Ultra-high strength suture
5. 3.5-mm SwiveLock interference screw® (Arthrex, Inc.)	*Anchor *Placed under tension into a bone tunnel, knotless means of fixation

Table 3: Devices used for direct PPR <sup>10</sup>

fixed the tape to the proximal phalanx by passing it from plantar proximal to dorsal distal.<sup>10</sup> Tension is placed on the interference fixation of the synthetic tape in order to achieve 10 to 15 degrees of dorsiflexion at MTP joint. Under tension, the foot is pressed against a flat plate to stimulate distal toe purchase. Interphalangeal arthrodesis or arthroplasty may be done with this procedure. The author stated that there is a lack of plantar plate remnants for anatomical repair after an extended period of repeated subluxation, and therefore, it is more favorable to use the FiberTape® for plantar plate repair.

## DISCUSSION

Currently, most surgeons agree that direct PPR surgical method is the optimal technique to adequately repair a plantar plate tear. In the case series by Nery et al., the dorsal approach

was used to directly repair the plantar plate. Their surgical technique included a Weil metatarsal osteotomy and directly suturing non-absorbable sutures into the plantar plate with a small needle. The patients in the study demonstrated significant improvement in MTP joint re-alignment and joint stability and a significant decrease in pain level. The authors firmly believe that direct PPR would be enhanced by providing smaller, precise instruments. The surgeons could potentially perform the operation in less time, improve the dissection of soft tissue, and provide better outcomes.<sup>9</sup> In order to assist with direct PPR, modern suture passer devices, interference screws, stronger suture materials, and specialized tapes were produced by several companies, such as ArthroCare Corp, Arthrex, Inc, and Smith & Nephew, Inc,. There is continued debate regarding the best surgical exposure technique, dorsal or

plantar, to visualize the defected plantar plate.

Weil et al. suggested many advantages of using a dorsal incision. These advantages included repairing the plantar plate anatomically and advancing it onto the proximal phalanx after the Weil metatarsal osteotomy is performed. Postoperatively, the patient is able to immediately weight-bear. The dorsal approach, compared to the plantar approach, decreases the chance of wound complications and plantar tissue trauma.<sup>5</sup>

In contrast to the dorsal approach used by Weil et al., Donegan et al. utilized both dorsal and plantar incisions to visualize the plantar plate directly. The plantar plate was reinforced by the FDL sheath. The major complication associated with this technique is devascularization, plantar scarring, and dehiscence of the incisional site. Two out of the 10 patients experienced superficial dehiscence secondary to the plantar incision.<sup>7</sup>

Donegan et al. and Flint et al. both recognized the advantage of utilizing the FDL when there is a lack of plantar plate tissue to suture. By using the FDL, the surgeon is able to robustly repair the plantar plate and to restore digital position.<sup>6,7</sup> The technique proposed by Donegan et al. included an arthrodesis of the 2nd PIPJ rather than a Weil metatarsal osteotomy. The authors suggested their technique eliminated the risk of painful hardware associated with

direct PPR methods utilizing a Weil osteotomy.

Instead of performing an FDL transfer, Sung et al. suggested an alternative procedure using high tensile-strength FiberTape<sup>®</sup> suture with two SwiveLock interference screws<sup>®</sup>. Ideally, this alternative technique should be carried out when there is an inadequate amount or no plantar plate tissue. The authors acknowledged the complications associated with the screws such as hardware failure, local inflammatory response, and metatarsalgia.<sup>8</sup>

In 2014, the London-based company, Smith & Nephew, Inc., purchased ArthroCare Corp. There is a lack of research articles regarding HAT-trick lesser toe repair system. However, the product was present at 2012 International Foot & Ankle Conference in Sydney Australia.<sup>11</sup>

## CONCLUSION

There are several limitations in the studies and report reviewed. Firstly, the studies are retrospective case series in nature or merely a device report without patient data. Secondly, the articles discussed the advantages and disadvantages of dorsal and plantar incisions, but no comprehensive comparisons among different devices were conducted in any of the studies. Also, the number of patients recruited in the PPR-related procedures are small with short-term follow-up. In addition, the surgeon's

experience is one of the determinants of the success of a procedure. The articles failed to mention the experience of the surgeon or if the surgeon was familiar with the devices, hardware, and materials. Lastly, the study conducted by Flint et al. reported that a portion of their study was funded by a grant from Arthrex Inc.

Despite the limitations, it is inferred that: in order to prevent plantar plate tears from progressing to complex digital deformities, it is imperative for clinicians to diagnose plantar plate tear in the early stages by completing a thorough history and physical examination. If examiners suspect a grade 0 plantar plate tear, conservative treatments should be attempted. If conservative treatment fails, clinicians should confirm the diagnosis of plantar plate tear and stage the plantar plate tear with MRI. Corresponding surgery is indicated for different stages of plantar plate tear, and with the availability of new assistive devices, substantial improvement in patient's outcome might be observed functionally and clinically.

The studies utilizing the dorsal and/or plantar incisional approaches to repair the plantar plate reported patients' significant improvement in pain. The dorsal incisional approach is associated with fewer complications and early weight-bearing when compared to the plantar incisional approach. Secondly, no complications were discussed directly related to the suture passer assistive devices, and

therefore, the assistive device should be used instead of a small curved needle to facilitate the best outcome for the patient. To establish a standard of care, a cohort study or randomized control trial comparing the different approaches and devices needs to be carried out with long-term follow-up.

## AUTHORS' CONTRIBUTIONS

All authors participated equally in the conception of the research topic, literature review, and extraction of data. All authors agreed upon the final submission.

## STATEMENT OF COMPETING INTERESTS

The authors declare that they have no competing interests.

## REFERENCES

1. Doty, J. F., Coughlin, M. J., Weil, L., & Nery, C. (2014). Etiology and Management of Lesser Toe Metatarsophalangeal Joint Instability. *Foot and Ankle Clinics*, 19(3), 385-405.
2. Nery, C., Coughlin, M. J., Baumfeld, D., & Mann, T. S. (2012). Lesser Metatarsophalangeal Joint Instability: Prospective Evaluation and Repair of Plantar Plate and Capsular Insufficiency. *Foot & Ankle International*, 33(4), 301-311. doi:10.3113/fai.2012.0301

3. Fleischer, A. E., Klein, E. E., Ahmad, M., Shah, S., Catena, F., Weil, L. S., & Weil, L. (2016). Association of Abnormal Metatarsal Parabola with Second Metatarsophalangeal Joint Plantar Plate Pathology. *Foot & Ankle International*. doi: 10.1177/1071100716674671 doi: 10.1016/j.fcl.2014.06.013
4. Klein, E. E., Weil, L., Weil, L. S., & Knight, J. (2012). Magnetic Resonance Imaging Versus Musculoskeletal Ultrasound for Identification and Localization of Plantar Plate Tears. *Foot & Ankle Specialist*, 5(6), 359-365. doi: 10.1177/1938640012463061
5. Weil, L., Sung, W., Weil, L. S., & Malinoski, K. (2011). Anatomic Plantar Plate Repair Using the Weil Metatarsal Osteotomy Approach. *Foot & Ankle Specialist*, 4(3), 145-150. doi: 10.1177/1938640010397342
6. Flint, W. W., Macias, D. M., Jastifer, J. R., Doty, J. F., Hirose, C. B., & Coughlin, M. J. (2016). Plantar Plate Repair for Lesser Metatarsophalangeal Joint Instability. *Foot & Ankle International*. doi: 10.1177/1071100716679110
7. Donegan, R. J., & Caminear, D. (2016). Anatomic Repair of Plantar Plate with Flexor Tendon Sheath Reinforcement: Case Series. *Foot & Ankle Specialist*, 9(5), 438-443. doi: 10.1177/1938640016630057
8. Sung, W. (2015). Technique Using Interference Fixation Repair for Plantar Plate Ligament Disruption of Lesser Metatarsophalangeal Joints. *The Journal of Foot and Ankle Surgery*, 54(3), 508-512. doi: 10.1053/j.jfas.2014.04.023
9. Nery, C., Coughlin, M. J., Baumfeld, D., Raduan, F. C., Mann, T. S., & Catena, F. (2014). Prospective Evaluation of Protocol for Surgical Treatment of Lesser MTP Joint Plantar Plate Tears. *Foot & Ankle International*, 35(9), 876-885. doi:10.1177/1071100714539659
10. Helping Surgeons Treat Their Patients Better™. (n.d.). Retrieved January 03, 2017, from <https://www.arthrex.com/>
11. Saltzman, C. The Development of a Novel Repair Technique for Metatarsophalangeal Instability Utilizing Cadaver Validated Computer Modeling: A Comparison with Current Techniques. *International Foot & Ankle Conference*. 2012 Sydney, Australia.

# The Efficacy of the Ilizarov Technique in Children with Recurrent Clubfoot Deformities: A Qualitative Systematic Review

*Lauren Murphey, BA, Priam Sandilya, MBS, & Ronika Sethi, BS*

## Abstract

### Introduction

Clubfoot deformities generally present as equinus and varus of the hindfoot, with forefoot adduction. The occurrence of clubfoot is 1 in 1,000, and the recurrence rate is approximately 20%.<sup>1</sup> The Ilizarov technique allows for bone and soft tissue correction through gradual manipulation by means of external fixation. This technique avoids further shortening of the foot and allows for outcomes associated with low complication rates.<sup>1</sup> The purpose of this study is to assess the efficacy of the Ilizarov technique in children under the age of 15 that have recurrent clubfoot deformities.

### Study Design

Qualitative Systematic Review of Literature

### Methods

The authors performed two independent English language PubMed searches. The first search used the MeSH terms “Ilizarov technique” AND “clubfoot” AND “treatment” AND “children”. This produced 37 articles, of which, 7 were used for final review after applying the inclusion/exclusion criteria. The second search used the MeSH terms “relapsed clubfoot” AND “Ilizarov”. This produced 19 articles, of which, 2 additional articles were used for final review. The exclusion criteria included: non-English papers, articles written prior to 2006, case studies, and literature reviews. The inclusion criteria included: human studies and articles with patients under 15 years old. After applying both the inclusion and exclusion criteria, 9 total articles were used by the authors for this qualitative systematic review.

### Results

According to the scoring scales used, the majority of the research asserted 75% “good” or “excellent” results using the Ilizarov technique.<sup>1</sup> Furthermore, the Ilizarov technique has proven to have minimal complications with improved foot function.<sup>3</sup> For additional information refer to Table 2.

### Conclusion

The Ilizarov technique is an excellent treatment option for recurrent clubfoot deformities in children under the age of 15. It is associated with minimal complications, minimal scarring, and does not cause foot shortening. There is a good prognosis for children with relapsed clubfoot treated with the Ilizarov technique, regardless of the scoring scale used, age, frame, and follow up time.

### Keywords

Ilizarov technique, clubfoot, talipes equinovarus (TEV), children under 15, recurrent clubfoot, relapsed clubfoot

*Level of Evidence: 4*



## INTRODUCTION

### *Etiology*

Clubfoot, also known as talipes equinovarus (TEV), occurs in 1 in 1,000 children. A clubfoot deformity generally includes equinus and varus of the hindfoot, with forefoot adduction. Displacement of the navicular, calcaneus, and cuboid bones around the talus can also occur with TEV deformities.<sup>1</sup> A person with this deformity will have difficulty with daily activities due to pain with ambulation. Particularly in developing nations, clubfoot deformities are a common cause of debilitation, having a negative impact on children and adults throughout their lives.<sup>2</sup>

The primary goal of clubfoot treatment is to help the patient obtain a plantigrade, fully functional, painless, and cosmetically appealing foot, without calluses. This will allow the person to wear normal shoes without pain.<sup>3</sup> The gold standard for TEV treatment is the Ponseti technique which utilizes serial casting.

Other treatments of TEV employ open surgeries. Open surgeries include soft tissue releases, tendon transfers, and/or osteotomies.<sup>4</sup> Such interventions often lead to pain, foot shortening, poor wound healing, extensive scarring, and increased rigidity of the foot and ankle.<sup>3</sup> Soft tissue release can lead to neuromuscular problems, fibrosis, and skin necrosis; causing increased pain, and stiffness of the

feet.<sup>5</sup> The primary complication following surgery is the tendency of clubfoot recurrence in approximately 20% of treated patients.<sup>6</sup> Repeated surgical procedures to correct the clubfoot deformity caused more stiffness due to scarring.<sup>7</sup> Causes for a relapsed clubfoot include muscle imbalance, soft tissue contracture, infection following surgery, poor follow up, and inadequate postoperative bracing.<sup>8</sup>

The Ilizarov technique uses an external fixator that allows for correction of recurrent clubfoot deformity, while simultaneously protecting the soft tissue anatomy.<sup>7</sup> These corrections are made by applying a fixator with rings and transfixation wires. The rings and wires are placed in slightly different orientations for each patient in order to cater to their specific needs. Most Ilizarov frames follow the Ponseti principle, which utilizes the natural movements of the subtalar and ankle joints in order to obtain a kinesiological correction in relapsed clubfeet.

### *Scoring*

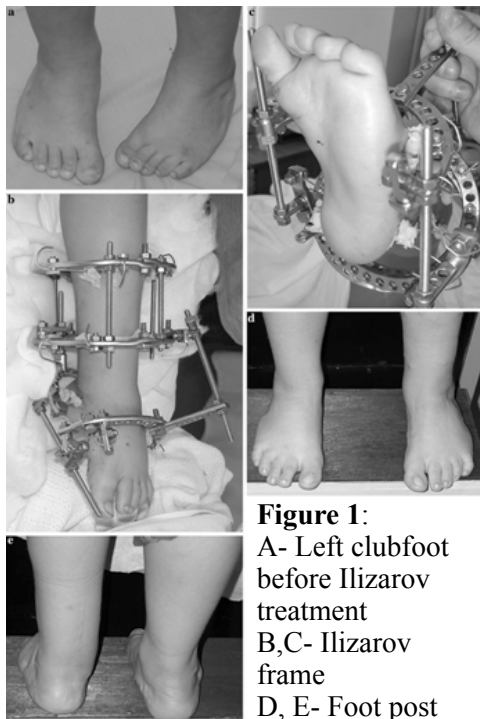
There are several different scoring systems to evaluate the efficacy of the Ilizarov technique. These included the Dimeglio scale, the functional rating system of Laaveg and Ponseti, the Beatson and Pearson numerical assessment, and the International Clubfoot Study Group Score (ICFSG). The Ilizarov outcome grading scales are described in Table 1.

SCALE USED	DESCRIPTION OF SCALE	
International Clubfoot Study Group Score (ICFSG) <sup>4,7</sup>	Score based on: 1. Foot morphology (12 points) 2. Functional evaluation (36 points) 3. Radiological alignment — assessed (12 points) Patient and parental satisfaction was also measured based on the appearance, the plantigrade position of the foot, the ability to walk, and the ability to wear normal shoes	0: normal foot 1-5: excellent 6-15: good 16-30: fair 30-60: poor >60: most deformed
Dimeglio Score <sup>6,9</sup>	Indicator of clinical picture: 1. Equinus in the sagittal plane 2. Varus deviation in the frontal plane 3. Deterioration around the talus of the calcaneoforefoot block 4. Adduction of the forefoot on the hindfoot in the horizontal plane The scale includes four additional points for the presence of medial creases, a posterior crease, cavus foot, and poor calf musculature	GRADE I: Benign < 5 points GRADE II: Moderate 5 to 10 GRADE III: Severe 10 to 15 GRADE IV: Very Severe 15 to 20
American Orthopedic Foot and Ankle Score (AOFAS) <sup>10</sup>	Clinician based score that measures outcomes of four different anatomic regions of the foot: Ankle/Hindfoot, Midfoot, Metatarsophalangeal (MTP)-interphalangeal (IP) for the hallux, MTP-IP for the lesser toes  Score based on: 1. Pain (40 points) 2. Function (50 points) 3. Alignment (10 points)	Score is added together for a total of 100 possible points with a higher score indicating more severe deformity.
Reinker and Carpenter <sup>1</sup>	N/A	1. Excellent: painless, plantigrade foot with no functional limitations 2. Good: plantigrade foot 3. Fair: mild residual deformity required bracing, and/or some functional limitations but an active life in a patient able to ambulate long distance with mild pain 4. Poor: significant residual deformity, pain, and activity limitations
Ponseti-Laaveg System <sup>5</sup>	Functional evaluation score based on: 1. Pain (30 points) 2. Patient satisfaction (20 points) 3. Function (20 points) 4. Gait (10 points) 5. Position of heel when standing (10 points) 6. Passive motion (10 Points)	90-100: excellent 80-89: good 70-79: fair < 70: poor
Beatson and Pearson <sup>6</sup>	System evaluates according to clinical and functional appearance based on: Function, Movement, & Morphology Each category is out of 4 possible points	9 points: excellent 7-9 points: good <7points: poor

**Table 1:** Ilizarov outcome grading scales with a description of each

### Overview of Ilizarov frame

The Ilizarov technique is a relatively non-invasive alternative to invasive surgery and serial casting for relapsed TEV. It works through gradual distraction, lengthening the periarticular contractures, and by forming new congruous joint relationships in a plantigrade position.<sup>4</sup> It does not use bone resection, which causes foot shortening, because it displaces the joints of the foot without compressing cartilage or bone. Thus, this allows bones to realign slowly.<sup>7</sup> By utilizing gradual lengthening, damage to the skin or blood supply is avoided.<sup>2</sup> Minimal fibrous scarring is associated with this procedure, and the biomechanics of the foot is restored.



**Figure 1:**  
 A- Left clubfoot before Ilizarov treatment  
 B,C- Ilizarov frame  
 D, E- Foot post treatment.<sup>3</sup>

Placement of each of the frame wires are customized for the patient. Although there are minor differences, a typical Ilizarov frame consists of several wires attached to different bony structures in the lower extremity. Wires are placed horizontally through the lower 1/3 of the tibia and attached with tension to an external ring. Another set of wires are placed transversely through the posterior part of the calcaneus and the distal part of the metatarsals. Each set of wires are fixed to another set of semicircular rings. The two rings are attached with bars; and the calcaneal and metatarsal rings are connected by links. This arrangement allows for dorsiflexion. The toes are left free.<sup>3</sup> The device is manipulated gradually, allowing the bones and soft tissue to straighten together overtime, which prevents further complications. Ahmed suggests overcorrecting the foot 10 degrees to account for recoil when the frame is removed. Once the deformity is corrected (3-8 weeks) the frames can be kept on for an additional 4-6 weeks to produce overcorrection. The frames are then removed under general anesthesia.<sup>6</sup> After the external fixator is removed, a below knee cast is applied for 2-4 weeks, and nighttime splinting with ankle foot orthosis is worn for 6 months afterward.<sup>3</sup>

### Purpose

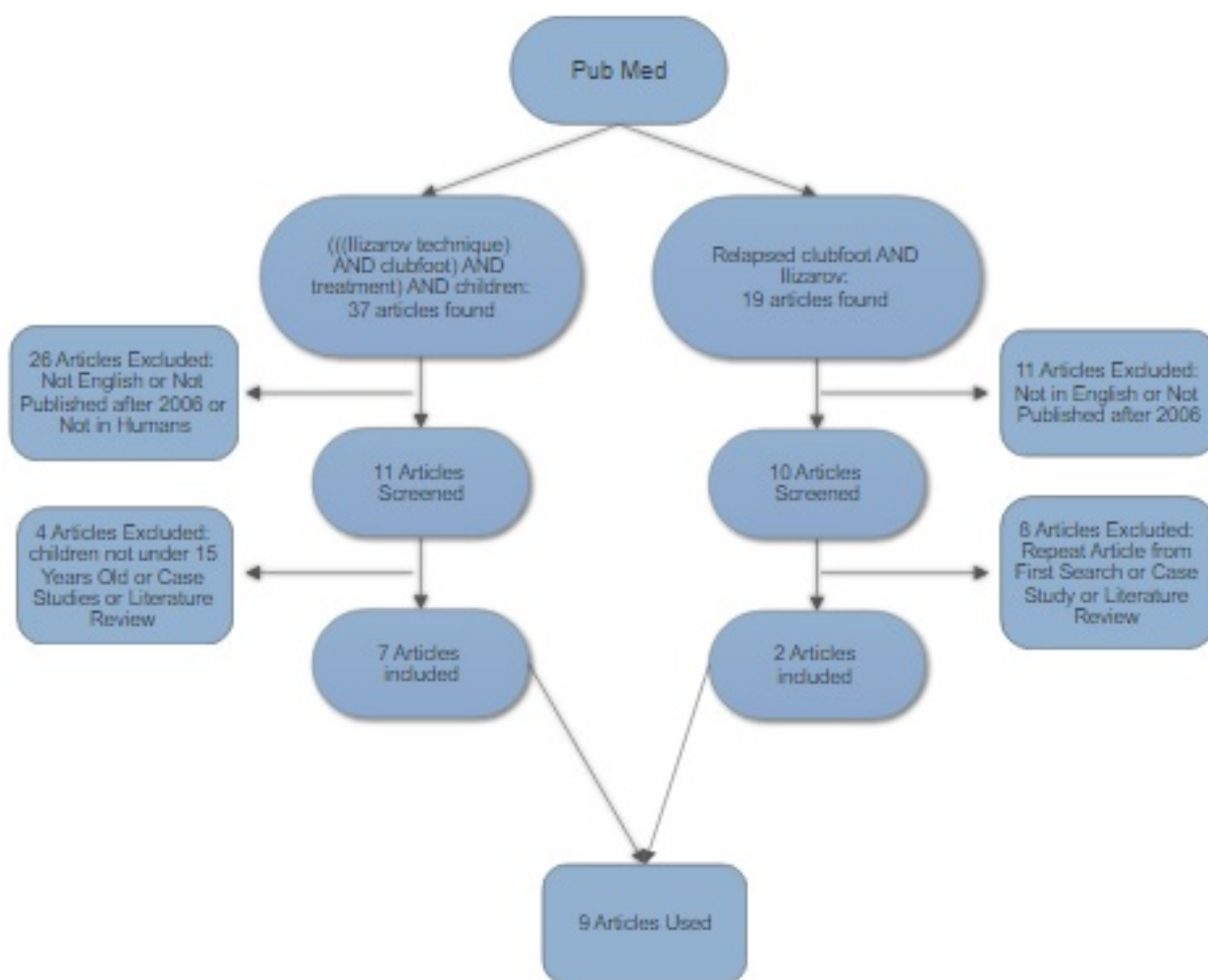
This study aims to explore the Ilizarov technique as a treatment for relapsed clubfoot in children under 15 years of

age. The purpose is to conduct a systematic review on the Ilizarov technique. We hypothesize that the Ilizarov technique is a non-invasive, efficient method for the correction of a previously treated TEV compared to other more invasive operations.

## METHODS

The authors performed two independent online searches using the PubMed database. The Boolean operator “AND” was utilized. The first search included the MeSH terms “Ilizarov technique” AND “clubfoot”

AND “treatment” AND “children”. This yielded 37 articles. The second search included the MeSH terms “relapsed clubfoot” AND “Ilizarov”. This yielded 19 articles. The initial search produced 56 total articles, 15 of which were redundant articles. The exclusion criteria included: articles written prior to 2006, case studies, and literature reviews. The inclusion criteria included: papers written in English and studies performed on human patients under 15 years old. The inclusion and exclusion criteria were applied, and redundant articles were eliminated. 9 total articles were



**Figure 2:** Summary of methods depicted by a flow chart

used for the final review. Figure 2 depicts a flowchart of the methods employed.

## RESULTS

Gupta et al., Prem et al., and Saghieh et al., conducted retrospective studies, and used the ICFSG technique. Gupta et al. found that of the 16 feet that were treated using the Ilizarov technique; 6 feet were excellent, 8 were good, and 2 were fair.<sup>7</sup> Prem et al. found patients post- Ilizarov for recurrent clubfoot to yield 74% excellent or good results; 4 excellent, 10 good, and 1 poor. The patient that received a “poor” rating was due to recurrence.<sup>4</sup> Superficial pin tract infections were observed in multiple patients, but were managed with antibiotics.<sup>1,2,3,4,7,8</sup> Other complications that were recorded, included foot edema<sup>2,7</sup> (usually subsided within 6 weeks), subluxation at the metatarsophalangeal joint, stiffness<sup>4,7</sup>, and flexion deformities of the toes.<sup>7</sup> Saghieh et al. stated that the overall success rate using closed distraction is not significantly better than the reported results from open surgery. This research group used the Ponseti serial casting method, and obtained satisfactory results. Correction was obtained in 89% of cases but 14% relapsed later. Forward subluxation of the talus was seen in 2 feet, flexion deformities of the toes were observed in 4 patients, and there was a first met fracture recorded in 1 patient.<sup>3</sup>

El-Sayed and Tripathy et al. both utilized the Dimeglio scale to assess

the degree of deformity. El-Sayed’s study included 9 feet with a grade IV deformity, 25 feet grade III, and 8 feet grade I pre-Ilizarov. After applying the Ilizarov frame, 25 feet were grade I, 15 were grade II, and 1 foot was grade III. The same research group used the Beatson and Pearson numerical assessment, and found that after an average 4.6 year follow up there were 17 feet that were excellent, 20 were good, and 5 were poor. Pin tract infections were observed in 30 feet, 10 patients needed antibiotics to heal and 1 patient obtained several infections leading to the removal of the wires (this did not affect the total outcome results because the wires were removed after the deformity was corrected). El- Sayed also observed flexion deformities in 26 feet, which then needed to be manipulated after the frame was removed. 2 children had still had equinus and varus deformities after the procedure and subsequent casting. Persistent pain was felt in 2 of the 42 children.<sup>6</sup> Tripathy et al.’s study included 11 feet with grade IV, and 4 feet that were a grade III, per the Dimeglio scoring system. After 2.5 years following the installation of the Ilizarov frame, 1 foot was grade I, and 4 feet were grade II. In this study the total reduction in the Dimeglio score was 11.7 which was statistically significant. This group of researchers also used the Laaveg and Ponseti scoring system; there was an average score of 75.47. No major complications were recorded except in 1 child.<sup>5</sup>

Refai utilized the AOFAS grading scale and found 16 of the 19 feet treated with the Ilizarov frame to be plantigrade with no major complication, which were defined as “needing additional major surgery”. The 3 feet (2 patients) with major

complications needed a foot osteotomy and distraction callotasis.<sup>11</sup>

Table 2 summarizes the findings of the articles, including the scales utilized to compare Pre-op and post-Ilizarov frame treatment of recurrent TEV.

Reference	Scale Used	Pre-Op Inclusion Factors/ Score	Outcome Score After Ilizarov Frame	Age Group
Gupta, P., et al <sup>7</sup>	ICFSG scoring	Analyzed 15 patients with idiopathic club feet who previously had medial open soft tissue surgical releases.	6 patients: excellent 8 patients: good 2 patients: fair	Age range 4-14 years old with a mean age of 6.8 years old
Saghieh, S., et al <sup>3</sup>	ICFSG scoring	Pre-Ilizarov: 8 feet: poor	Post- Ilizarov: 3 feet: excellent 4 feet: good 2 feet: fair -Pre-op and Post-op values was statistically significant with a P value of 0.0039 using the Wilcoxon signed-rank test.	Age range 3 - 9 years old with a mean age of 5.6 years old
Tripathy, SK., et al <sup>5</sup>	Dimeglio Score and the Ponseti-Laaveg System	Dimeglio Score results: Pre-Ilizarov: 11 feet: grade IV (very severe) 4 feet: grade III (severe) Ponseti-Laaveg System results: Mean score: 15.7	Dimeglio Score results: Post- Ilizarov: 11 feet: grade I (benign) 4 feet: grade II (moderate) Ponseti-Laaveg System results: Mean score: 75.47	Mean age of 7.3 years old
El-Sayed, M. <sup>6</sup>	Dimeglio Score and the Beatson and Pearson	Dimeglio score results: Pre-Ilizarov: 9 feet: grade IV 25 feet: grade III 8 feet: grade I	Dimeglio score results: Post-Ilizarov: 25 feet: grade I 15 feet: grade II 1 foot: grade III Beatson and Pearson score results (after average 4.6 year follow up): 17 feet: excellent 20 feet: good 5 feet: poor	Age range 3-13 years old with a mean of 6 years old

Refai, MA., et al <sup>11</sup>	AOFAS	AOFAS: 48-71 (with one score of 32 being an outlier)	AOFAS: 64 - 91 (with one score of 32 being an outlier)	Age range 4-15 years old with a mean age of 8 years old
Malizos, KN., et al <sup>1</sup>	Ponseti-Laaveg	The Ilizarov frame was used on patients with a stiff rearfoot and forefoot that weren't able to be fixed passively, and/or had residual intraoperative deformity from their previous soft tissue releases.	Laaveg-Ponseti score was 85.1: 2 feet: excellent 3 feet: good 2 feet: fair	Mean age was 7.8 years old
Ahmed <sup>8</sup>	Reinker and Carpenter scale	N/A Since these Author's compared the results to others.	11.1%: Excellent 61.1%: good 22.2%: fair 5.6%: poor	Mean age was 5.5 years old
Prem, H. <sup>4</sup>	ICFSG score and the Dimeglio Score	Dimeglio grade III was a minimum inclusion criteria	ICFSG score results: 74% rated excellent or good  Dimeglio's score results: 4 feet: excellent 10 feet: good 1 foot: poor (because of recurrence)	Age range 2- 8 years old
Khanfour, A. <sup>2</sup>	Descriptive grading system was used where results were considered "good" if the foot was plantigrade with no recurrence of the deformity, the parents are satisfied, there was no pain, good walking capacity, and no problems with wearing shoes	N/A  No pre-op condition was disclosed in this article other than the patients had relapsed or neglected clubfeet	21 feet: good 4 feet: fair	Age range 3-8 years old

**Table 2:** Results using the Ilizarov technique; by Authors.

## DISCUSSION

Studies found that the Ilizarov frame worked better in younger children with less previous attempts for clubfoot correction, and less time in-between relapse, and the frame application.<sup>6</sup> The preservation of motion via the Ilizarov technique was found to reduce the occurrence of late ankle arthritis.<sup>7</sup> The Ilizarov technique is more effective than other options for treating recurrent clubfoot because it is effective despite scar tissue buildup from previous surgeries. In addition, Ilizarov technique does not contribute to additional internal scarring like open surgeries.<sup>7</sup>

There was an article written, that contradicts our hypothesis and findings. This article was excluded from our research because it is a literature review and not written within the given time frame used in our set methods. Freddman et al. preformed a study which was the first in the literature to show the Ilizarov frame to result in poor outcomes for patients with resistant clubfoot; meaning that they found high rates of recurrence which lead to needing additional surgery.<sup>12</sup>

### *Complications:*

Although, there are few major complications that arise with the Ilizarov frame, there are some. These include, flexion contracture of the toes, anterior subluxation of the talus, joint stiffness in the foot, recurrence

of clubfoot, and pin tract infections.<sup>7</sup> Pin infections were easily managed with dressings, and antibiotics.<sup>1,2,3,4,7,8</sup> The flexion contracture deformity of the toes, after the fixator was removed could not be prevented due the pain felt during passive manipulation. The flexion was corrected by percutaneous tenotomy, manipulation under anesthesia, or pinning of the hallux to the forefoot half ring. Furthermore, the frame is complicated, and its use is time consuming; there can be a lack of patient, and parent compliance.<sup>8</sup> If the technique is not done gradually it can lead to pain, swelling, and other complications.<sup>8</sup>

### *Limitations:*

The Ilizarov technique has led to many satisfactory outcomes but a large prospective randomized control study needs to be done. There are many ways to measure success and level of deformity in clubfoot but there is no uniform way to measure outcome of treatment. Limitations include small cohort sizes, short term follow up, and the age of the patients.<sup>4</sup>

## CONCLUSION

The Ponseti method is the gold standard care for TEV correction. However, the Ilizarov technique is a viable alternative to other surgical options, or additional serial casting for recurrent clubfoot in children. It is relatively non-invasive, and can correct feet with significant scar tissue buildup from previous surgeries. The



gradual correction prevents neurovascular problems, and prevents tight soft tissues from altering nearby joints because of its multiple levels of fixation. The Ilizarov technique is more effective in younger patients, and in those who have had less previous surgical intervention.<sup>6</sup> Most reports show 75% “good” or “excellent” results.<sup>1</sup> The Ilizarov technique has minimal complications, and can significantly improve foot function.<sup>3</sup> Bracing post op, and watching the patients closely for an extended period of time is necessary to uncover recurrences, and avert relapse.<sup>3</sup> Treating a patient with the Ilizarov external fixation method allows for overall better ambulation, less pain, and the ability to wear normal shoes.<sup>3</sup>

## AUTHORS’ CONTRIBUTIONS

All three authors contributed to producing this paper. All conceived the topic and performed the initial literature reviews. All authors drafted, read, reviewed, and agreed upon the final manuscript.

## STATEMENT OF COMPETING INTERESTS

The authors declare that they have no competing interests.

## REFERENCES

1. Malizos KN, Gougoulis NE, Dailiana ZH, Rigopoulos N, Moraitis T. Relapsed clubfoot correction with soft-tissue release and selective application of Ilizarov technique. *Strategies in Trauma and Limb Reconstruction*. 2008;3(3): 109-117. doi:10.1007/s11751-008-0049-5.
2. Khanfour AA. Ilizarov techniques with limited adjunctive surgical procedures for the treatment of preadolescent recurrent or neglected clubfeet. *Journal of Pediatric Orthopaedics B*. 2013;22(3): 240-248. doi:10.1097/bpb.0b013e32835f1f99.
3. Saghie S, Bashoura A, Berjawi G, Afeiche N, Elkattah R. The correction of the relapsed club foot by closed distraction. *Strategies in Trauma and Limb Reconstruction*. 2010;5(3):127-135. doi:10.1007/s11751-010-0097-5.
4. Prem H, Zenios M, Farrell R, Day JB. Soft Tissue Ilizarov Correction of Congenital Talipes Equinovarus-5 to 10 Years Postsurgery. *Journal of Pediatric Orthopaedics*. 2007;27(2):220-224. doi:10.1097/bpo.0b013e31803173bf.
5. Tripathy SK, Saini R, Sudes P, et al. Application of the Ponseti principle for deformity correction in neglected and relapsed clubfoot using the Ilizarov fixator. *Journal of Pediatric Orthopaedics B*. 2011;20(1):26-32. doi:10.1097/bpb.0b013e32833f33fe.
6. El-Sayed M. Ilizarov external fixation for management of severe relapsed clubfeet in older children. *Foot and Ankle Surgery*. 2013;19(3):177-181. doi:10.1016/j.fas.2013.04.002.
7. Gupta P, Bither N. Ilizarov in relapsed clubfoot. *Journal of Pediatric Orthopaedics B*. 2013;22(6):589-594. doi:10.1097/bpb.0b013e32836486de.

8. Ahmed AA-RY. The Use of the Ilizarov Method in Management of Relapsed Club Foot. *Orthopedics*. January 2010. doi: 10.3928/01477447-20101021-25.
9. Wainwright A, Auld T, Benson M, Theologis T. The classification of congenital talipes equinovarus. *The Bone & Joint Journal* 84(7):1020-4. October 2012:1020-1024. doi: 10.1302/0301-620X.84B7.12909.
10. The American Orthopedic Foot and Ankle Score (AOFAS). Code Technology | We Collect Orthopedic Patient Outcomes. <https://www.codetechnology.com/american-orthopedic-foot-ankle-score-aofas/>. Accessed December 29, 2016.
11. Refai MA, Song S-H, Song H-R. Does Short-term Application of an Ilizarov Frame with Transfixion Pins Correct Relapsed Clubfoot in Children? *Clinical Orthopaedics and Related Research*®. 2012;470(7):1992-1999. doi: 10.1007/s11999-012-2289-4.
12. Freedman, J. A., Watts, H., & Otsuka, N. Y. (2006). The Ilizarov Method for the Treatment of Resistant Clubfoot. *Journal of Pediatric Orthopaedics*, 26(4), 432-437. doi:10.1097/01.bpo.0000226276.70706.0e

# Soft Tissue Sarcomas of the Distal Lower Extremity: A Literature Review of Case Series

*Sara Stachura, BS, BA, Lauren Kuenzi, BS, & Adenike Sonaike, BS*

## Abstract

### Introduction

Soft tissue sarcomas are rare to find throughout the body, and even more rare to find in the foot and ankle. Due to the rarity of this condition and the fact that it often mimics the presenting symptoms of other benign tumors, it is often misdiagnosed in the foot and ankle. The purpose of this paper is to compare case series describing the treatment plans and outcomes of patients with soft tissue sarcomas of the foot and ankle, focusing on limb salvage, radiation therapy, and amputation.

### Study Design

Qualitative Systematic Review of Literature

### Methods

The authors performed a systematic search utilizing PubMed, including keywords such as “soft tissue sarcoma”, “soft tissue tumor”, “lower extremities”, and “foot”. A manual search of Google Scholar was also performed. Inclusion criteria were articles written in the English language, case series, malignant soft tissue sarcomas of the foot, and articles written after the year 2005. Exclusion criteria eliminated articles describing soft tissue sarcomas in regions other than the foot and articles without extractable data for foot specific tumors.

### Results

Ten case series were chosen describing 405 patients, of which there were 187 females and 218 males. The average age of the patients during the primary diagnosis was 46 years old. Overall, 34% of the patients received unplanned excision, defined as those which were removed without the knowledge of malignancy. There were 193 patients who received adjuvant radiation therapy, 77 patients received adjuvant chemotherapy, and 9 patients received both radiation therapy and chemotherapy. Overall, 239 patients successfully completed limb salvage procedures, while 105 patients received an amputation either as initial treatment or after local recurrence. Overall, 86 patients experienced metastasis and 66 patients died from the disease.

### Discussion and Conclusions

Unplanned excisions are common amongst patients with soft tissue sarcomas. All patients presenting with a soft tissue mass of the foot and ankle should receive an MRI with contrast prior to medical treatment. Increased tumor size between the groups affects the prognosis in a negative manner, so early referral to a cancer center is important. Limb salvage is an appropriate treatment for soft tissue sarcomas, even in patients who have undergone previous unplanned excision. Functional outcomes can be attained using this approach. These patients should be treated with adjuvant therapies and followed closely to monitor recurrence.

### Key Words

*soft tissue sarcoma, foot, ankle, excision, limb salvage*

*Level of Evidence: 4*

## INTRODUCTION

Soft tissue sarcomas are a specific group of masses that originate from mesenchymal descent.<sup>1</sup> This group of sarcomas are rare to find throughout the body, and even more rare to find in the foot and ankle.<sup>2</sup> Soft tissue sarcomas represent less than 1% of malignancies in the United States.<sup>3</sup> When they do occur, it is only present in the foot or ankle 2-5% of the time.<sup>3</sup> Many soft tissue sarcomas of the foot and ankle are misdiagnosed upon initial presentation due to their rareness,<sup>4</sup> as well as the fact that they can often mimic the presenting symptoms of other benign tumors such as a ganglion cyst, inclusion cyst, or lipoma.<sup>3</sup> The most common symptom associated with soft tissue sarcoma is a painless mass; however, other symptoms include a painful mass, swelling, and decreased range of motion during gait.<sup>4</sup>

Misdiagnosis can lead to inappropriate treatment.<sup>5</sup> This may include unplanned excision, which is defined as those which were removed without the knowledge of malignancy, and thus did not attempt to achieve tumor-free margins.<sup>9</sup> Unplanned excision may result in positive margins, meaning residual tumor remains in the tissue.<sup>3</sup> This can lead to greater complications including local recurrence, amputation, or death.<sup>3</sup> Despite the increased risk, unplanned excisions are still used in over 40% of the cases that occur in the lower extremity.<sup>5</sup> Planned excision is

defined as those which underwent clinical and imaging evaluation in order to determine malignancy prior to excision.<sup>9</sup> The overall goal of planned treatment is to excise the tumor fully while still preserving full function of the lower extremity.<sup>9</sup> In order to excise the tumor fully, wider excision margins are attempted compared to margins used in unplanned excisions.<sup>9</sup>

Certain risk factors are associated with soft tissue sarcomas, including metastasis and death.<sup>3</sup> Epithelioid sarcoma, in particular, is associated with a higher risk of local lymph node metastasis.<sup>6</sup> Sarcomas located in the foot and ankle, as opposed to other locations, are also a risk factor because excision could result in loss of function to the extremity.<sup>7</sup> Due to the neurovascular structures of the foot and ankle, some authors recommend that the sarcoma be excised with larger margins, though this could ultimately lead to loss of function.<sup>6</sup>

Treatment options for soft tissue sarcomas include excision, limb salvage procedures, chemotherapy, radiation therapy, and amputation.<sup>6</sup> Limb salvage in conjunction with radiation therapy, is the accepted treatment for soft tissue tumors, though complications may arise that change the treatment course.<sup>10</sup> Complications of the limb salvage procedure include joint stiffness, skin ulceration and atrophy, fibrosis of the tissue, and more, which may ultimately lead to amputation.<sup>10</sup> The limb salvage procedure proves

difficult because it is a technically challenging procedure to perform.<sup>9</sup> In addition, there are many factors that may influence the overall success of the limb salvage procedure, including tumor type, size, grade, and depth.<sup>11</sup> Overall success may be measured by variables such as overall survival, sarcoma recurrence, overall happiness, ability to wear normal shoes, and ability to walk without the use of a walking aid.<sup>8</sup>

The purpose of this paper is to compare case series describing the treatment plans and outcomes of patients with soft tissue sarcomas of the foot and ankle, focusing on limb salvage, radiation therapy, and amputation.

## METHODS

The authors performed a systematic search utilizing PubMed, entering keywords “‘soft tissue sarcoma’ AND ‘foot’”. The search yielded 67 articles, 6 of which were selected. Keywords “‘soft tissue sarcomas’ AND ‘lower extremities’” yielded 53 articles, one of which was selected. Keywords “‘soft tissue sarcomas’ AND ‘feet’” yielded 6 articles, one of which was selected. Additional searches on PubMed, including “‘soft tissue

tumor’ AND ‘foot’” and “‘soft tissue sarcoma’ AND ‘lower extremity’”, yielded no unrepeated selectable results. All of the stated keywords were entered into Biomed Central, Cochrane databases, and JAPMA, yielding no selected articles. A manual search of Google Scholar yielded 2 selected articles. Inclusion criteria required articles written in the English language, case series, malignant soft tissue sarcomas of the foot, and articles written after the year 2005. Exclusion criteria eliminated articles describing soft tissue sarcomas in regions other than the foot and articles without extractable data for foot specific tumors. Overall, 10 articles were chosen describing 405 patients diagnosed with malignant soft tissue sarcoma of the foot.

## RESULTS

There were 10 studies selected which fulfilled the inclusion and exclusion criteria. These studies included a total of 405 patients diagnosed with soft tissue sarcoma of the foot or ankle. There were 187 females and 218 males. The mean age of onset was 46 years old. The average length of time that the studies took place was 22 years. The patient demographics and study length are presented in Table 1.

**Table 1.** Patient demographic and study length

Author	Salipas	Bishop	Harati	Kozawa	Nishimura	Latt	Cribb	Houdek	Thacker	Murray	
<b># of Patients</b>	33	47	120	24	14	16	27	62	52	10	
<b>Sex of Patients</b>	Female	11	23	60	12	4	9	15	27	20	6
	Male	22	24	60	12	10	7	12	35	32	4
<b>Mean Age of Onset</b>	43	41	57	43	36	41	47	45	38	33	
<b>Years of Study</b>	16	46	15	26	36	15	15	21	22	7	

Studies took place over an extended period of time due to rarity of soft tissue sarcomas in the lower extremity.

The patients in the studies were treated with a variety of techniques including excision, radiation, and/or chemotherapy. Overall, 138 patients received unplanned excision while 267 received planned excision, resulting in a total of 34% of patients receiving unplanned excision. There were 193 patients who received adjuvant radiation therapy, 77 patients received adjuvant chemotherapy, and 9 patients received both radiation therapy and chemotherapy as adjuvant treatments. There were 71 patients who experienced local recurrence of the soft tissue sarcoma. Overall, 239 patients successfully completed limb salvage procedures, while 105 patients received an amputation either as initial treatment or after local recurrence. Overall, 86 patients experienced metastasis and 66 patients died from the disease. The treatment and outcomes are presented in Table 2.

A total of 93 patients were diagnosed with synovial sarcomas, representing 22.9% of the study population. Synovial sarcoma was the most

common diagnosis in every study. The second most common diagnosis was clear cell carcinoma, totaling 26 patients and representing 6.4% of the study population. The third most common diagnosis was malignant fibrous histiocytoma, totaling 22 patients and representing 5.4% of the study population. The diagnosis of high grade pleomorphic undifferentiated sarcoma and leiomyosarcoma had 19 patients each, which each represented 4.7% of the study population. The diagnoses of low grade myxoid sarcoma, epithelioid sarcoma, and fibrosarcoma comprised of 14 patients each. Each of these diagnoses represented 3.5% of the study population. Twelve patients were diagnosed with dermatofibrosarcoma protuberans, 10 with liposarcoma, and 6 with myxofibrosarcoma. The diagnosis of alveolar rhabdomyosarcoma and myxoinflammatory fibroblastic sarcoma included 5 patients each. Four patients were diagnosed with angiosarcoma, 4 with peripheral nerve sheath tumor, and 4 with soft tissue

Author		Salipas	Bishop	Harati	Kozawa	Nishimura	Latt	Cribb	Houdek	Thacker	Murray
# Excised	Planned	14	47	104	14	9	8	11	27	23	10
	Unplanned	19	0	16	10	5	8	16	35	29	0
Treatment	Radiation	19	47	64	2	4	12	18	23	0	4
	Chemo	10	0	12	11	5	0	2	16	15	6
	Both	0	0	0	0	0	0	0	0	6	3
Recurrence		2	7	37	2	2	2	2	9	7	1
Limb Salvage		na	na	91	18	8	13	26	35	38	10
Amputation		19	na	29	6	6	3	1	27	14	0
Metastasis		na	5	31	8	6	4	2	15	13	2
Deaths (Disease)		na	na	18	5	4	3	4	20	11	1
na=not applicable, data could not be extracted from the published study											

**Table 3.** Summary of the most common soft tissue sarcoma diagnosis

Author	Salipas	Bishop	Kozawa	Nishimura	Latt	Cribb	Houdek	Thacker	Murray
Synovial Sarcoma	8	17	7	4	7	12	16	17	5
Clear Cell Carcinoma	5	3	4	2	2	3	5	0	2
Malignant Fibrous Histiocytoma	3	15	2	0	1	1	0	0	0
High Grade Pleomorphic Undifferentiated Sarcoma	0	0	0	0	3	2	5	9	0
Leiomyosarcoma	5	0	1	1	0	1	9	2	0
Low Grade Myxoidsarcoma	0	0	0	0	0	0	0	0	1
Epithelioid Sarcoma	0	4	3	0	0	1	3	3	0
Fibrosarcoma	1	0	0	1	2	0	8	2	0

Harati excluded from this table due to insufficient data.

chondrosarcoma. The diagnoses of neurofibrosarcoma, fibromyxosarcoma, and myxoid chondrosarcoma comprised 3 patients each. Two patients were diagnosed with small cell sarcoma, and one patient each with pleomorphic liposarcoma, spindle cell liposarcoma, rhabdomyosarcoma, myxoid liposarcoma, and small round cell sarcoma. There were 10 soft tissue sarcomas with the classification of “other.” The summary of the most common soft tissue sarcomas in each study is presented in Table 3.

Complications following treatment of soft tissue sarcomas varied in the case studies analyzed. Not all of the studies included complications of treatment, but those mentioned are worthy of noting. Bishop et al. found that 3 patients experienced tissue necrosis and ulceration.<sup>10</sup> Latt et al. found that one patient suffered a superficial wound infection, 2 patients experienced skin necrosis, and one patient experienced a free flap perfusion problem.<sup>5</sup> Cribb et al. found that one patient experienced wound edge necrosis, 3 patients experienced radiation burns, one patient had complex regional pain syndrome, one

patient suffered a small post-operative cerebral vascular accident, and one patient experienced local inflammation with patchy skin loss.<sup>8</sup> Houdek et al. had 8 patients with wound drainage and dehiscence, 3 patients with infection, 3 patients with skin graft failures, one patient experienced fibular overgrowth, and one patient experienced a pseudoaneurysm of the tibial vessels.<sup>12</sup> Finally, Murray et al. found that one patient experienced a wound infection, 2 patients had stiffness and swelling, and one patient had minor numbness.<sup>4</sup>

Several prognostic factors were indicated in the studies that are important to take into consideration when planning treatment for this condition. In the study conducted by Harati et al., it was noted that factors indicating a worse prognosis included male patients and those over 60 years of age at the time of primary diagnosis.<sup>11</sup> Nishimura et al. stated that prognosis could be improved through early referral to a cancer center, biopsy, and wide excisional margins.<sup>3</sup> Salipas et al. noted that metastasis present at the time of referral or after treatment was also linked to a worse prognosis.<sup>13</sup> Murray

et al. stated that 62.5% of the patients who had undergone unplanned excision had residual tumor present in the final resection; however, this did not affect the prognosis.<sup>4</sup> This was attributed to subsequent wide excision with adjuvant therapy, a small average tumor size of 3.28 cm, and a short follow-up period of 22.4 months.<sup>4</sup> Nishimura et al. and Salipas et al. noted that large tumor size negatively affected prognosis.<sup>3,13</sup> Thacker et al. stated that smaller tumor size also made limb salvage a more feasible option.<sup>2,9</sup>

In terms of amputation, Kozawa et al. noted that 2 patients received amputation.<sup>6</sup> One patient had an epithelioid sarcoma while the other had a clear cell sarcoma. The amputation was performed due to the higher rate of metastasis of these two tumors. Houdek et al. also found that amputation was associated with tumor physiology.<sup>12</sup> Bishop et al. noted that some clinicians promote immediate amputation due to the high rate of local control, but cautioned this approach by adding that treatment should be balanced against functional loss of the patient and the possibility of limb salvage.<sup>10</sup> Salipas et al. found that most of the patients who underwent amputation did so because of positive margins, most of which were intra-lesional.<sup>13</sup> Harati et al. found that patients who underwent amputation had worse outcomes, but noted that those patients had larger, more aggressive tumors.<sup>11</sup> Thacker et al. noted that unplanned excision did not result in more amputations, though

this may have been due to relatively smaller sized tumors in that group.<sup>9</sup>

Nishimura et al. noted that there was a higher rate of local recurrence in patients with unplanned excision.<sup>3</sup> Salipas et al. expanded on this, stating that there was also a high incidence of positive margins that resulted in an increased incidence of metastasis.<sup>13</sup> Thacker et al. found that local recurrence occurred more in the unplanned excision group, but this was not statistically significant.<sup>9</sup> This study noted that early identification of local recurrence may allow for re-excision with limb salvage, advocating that patients be followed closely to monitor for recurrence. Harati et al. noted that local recurrence, as well as overall survival, were not affected by surgical margins, but there was a trend in the data favoring negative margins.<sup>11</sup>

Harati et al. found that radiation therapy did not improve local recurrence or overall survival, but it did impair foot function.<sup>11</sup> Thacker et al. found that radiation therapy did not improve local disease control, a finding that may be because only patients with a worse clinical picture received radiation therapy.<sup>9</sup> This study also noted that unplanned excision was associated with more complications, attributing this to the requirement for more radiation therapy and free tissue transfer. Houdek et al. found that the only significant postoperative complication in this study was wound healing, which was associated with radiation



therapy.<sup>12</sup> In contrast, Kozawa et al. found that cases of unplanned excision with positive margins can be remedied to achieve local control with additional excision without the use of radiation therapy.<sup>6</sup> Bishop et al. expanded on this by stating that positive margins after the initial resection can be successfully managed with radiation therapy, and that this treatment did not result in further loss of function of the limb.<sup>10</sup> This study claimed that the addition of radiation therapy to the treatment regimen reported a better outcome than previous studies reported of resection alone.<sup>10</sup>

In terms of foot function, Kozawa et al. found that patients who received a free flap had lower functional scores, possibly indicating that excisions resulting in a larger defect is correlated to a poorer functional outcome.<sup>6</sup> Harati et al. stated that surgical excision attempting negative margins may be extensive and result in impaired function, and close negative margins seem to be an adequate approach.<sup>11</sup> Latt et al. found that patients with local recurrence did not always die, supporting the notion that limb salvage and preservation of function is appropriate.<sup>5</sup> Similarly, Cribb et al. concluded that functional outcomes can be attained with excision and adjuvant therapy when necessary, while Thacker et al. found that unplanned excision did not affect function of the patient after treatment or local recurrence.<sup>8,9</sup>

## DISCUSSION

Of the 405 patients included in this study, there were more male subjects, with a female to male ratio of 1:1.17. This suggests that males are slightly more likely to be diagnosed with soft tissue sarcomas of the lower extremity. The mean age of onset was 46 years of age in this study. Though the majority of patients were adults, soft tissue sarcomas do appear in the lower extremity of the pediatric population as well.<sup>14</sup> The lack of pediatric patients in this study may indicate that soft tissue sarcomas of the foot are more common in the adult population, or may be the result of selection bias.

On physical examination of soft tissue masses, tumor locations were recorded to have occurred in every area of the foot, including the dorsal and plantar aspects of the foot, rearfoot, midfoot, forefoot, and sinus tarsi area. Each study used different or unspecified boundaries to describe tumor location, leading to an inability to analyze tumor location between the studies evaluated. Documented tumor sizes ranged greatly, with wide variations of tumor grading and staging. Though tumor sizes in the foot may vary, they are still smaller in size than those found in other areas of the body.<sup>9</sup> This finding is attributed to the smaller compartments of the foot leading to increased constraints.<sup>9</sup> This may explain the finding that there is a decreased death rate amongst patients with soft tissue sarcomas of the foot

compared to other parts of the body.<sup>9</sup> Nishimura et al. noted a predictable variation amongst tumor size within the foot itself, stating that sarcomas of the plantar foot tend to initially present when they are a smaller size due to increased constraints and thus symptomatology.<sup>3</sup> It was noted that tumors on the dorsal aspect of the foot were larger due to decreased symptoms allowing increased neglect.<sup>3</sup>

The most common type of tumor in every study was synovial sarcoma, representing 22.9% of the study population. Synovial sarcomas have a metastasis rate of 50%-70%, and they tend to recur later than other histological sarcoma types.<sup>4</sup> The average follow-up ranged from 22.4 months to 7.5 years. The studies with shorter follow-up periods may have skewed the recurrence rate, causing it to appear lower than it is. Murray et al. suggests that patients with synovial sarcomas have a follow-up period of at least 10 years.<sup>4</sup> The overall second most common soft tissue sarcoma type was the clear cell carcinoma, which has a metastasis rate of 10%-14%.<sup>4</sup> Despite the lower rate of metastasis reported by Murray et al., Kozawa et al. noted that clear cell sarcomas, along with epithelioid sarcomas, tended to result in amputation and death more commonly than other histological tumor types.<sup>4,6</sup>

Houdek et al. noted that a high percentage of amputations were due to tumor physiology in general, and patients who received an amputation

had a decreased overall survival.<sup>12</sup> Kozawa et al., Cribb et al., and Harati et al. similarly attributed histology of the sarcoma to amputation of the limb.<sup>6,8,11</sup> Besides tumor physiology, other reasons for amputation included treatment complication, local recurrence, and when limb salvage was predicted to severely decrease limb function or leave gross residual sarcoma within the body.<sup>4,5,9</sup> Overall, this study found that 26% of patients required amputation despite limb salvage attempts or required amputation as initial treatment. This is significant because many patients prefer limb salvage, if possible, despite the various complications that may arise.<sup>8</sup>

At the time of presentation, the articles recorded a variety of patient chief complaints, including painless mass, stiffness during gait, limited range of motion, tenderness, and swelling. Of the chief complaints that were recorded, the most common complaint at the time of visit was a visible mass that seemed to be asymptomatic.<sup>3,4</sup> Differential diagnoses for soft tissue sarcoma include benign lesions such as ganglion cysts, which comprise about one-third of all soft tissue masses, lipomas, and hemangiomas.<sup>3</sup> Murray et al. stated that confusion may result from the painless presentation of a soft tissue sarcoma and its relative infrequency compared to benign lesions.<sup>4</sup> If a soft tissue sarcoma is mistaken for these differential diagnoses, there may be a delay in appropriate treatment.<sup>4</sup>

The percentage of unplanned excisions was 34% in this study, supporting the statement that unplanned excisions are common amongst patients with soft tissue sarcomas.<sup>3</sup> Murray et al. stated that before a soft tissue mass is excised from the foot or ankle, magnetic resonance imaging (MRI) should be performed.<sup>4</sup> Salipas et al., on the other hand, felt that ultrasound was appropriate to use to evaluate for malignancy before excision.<sup>13</sup> If there is a possibility of malignancy, a referral should be made to a surgical center.<sup>13</sup> In addition to MRI and ultrasound imaging techniques, computed tomography can be used to evaluate soft tissue masses and aid in identifying malignancy.<sup>6</sup> Proper diagnostic testing can lead to a more precise soft tissue excision.<sup>3</sup> This decreases the chance of remaining residual tumor, which may progress to local recurrence and further complications.<sup>3</sup>

There was a disparity between the effects of radiation therapy among the articles. Harati et al. concluded that radiation therapy impaired foot function, though this may be due to a small sample size.<sup>11</sup> In contrast, other studies did not report a functional deficit associated with radiation therapy.<sup>10</sup> It was noted that radiation therapy was associated with more wound healing complications.<sup>12</sup> Further research into radiation therapy techniques may decrease complications and improve the

outcomes for patients who receive this adjuvant therapy.<sup>10</sup>

Some of the complications that occurred post-operatively included infection, wound dehiscence, wound drainage, graft failure, free flap perfusion problems, tissue necrosis, ulceration, numbness, stiffness, and swelling. Complications from adjuvant therapies included radiation burns and local inflammation with patchy skin loss. Despite the possible complications noted, all authors agreed that limb salvage is appropriate for most soft tissue sarcomas of the foot and ankle, which commonly results in minimal functional deficit. Limitations of this study included the retrospective nature of all of the articles, small sample sizes, and lack of uniform analysis of the data obtained. Further, the studies took place over an average of 22 years. This wide time frame may influence the treatments that the patients received due to changes in protocols and advancement of surgical techniques.

## CONCLUSION

The probability of a positive prognosis can be increased with early detection and planned wide margin excisions.<sup>4</sup> Despite growing evidence for the need to fully evaluate soft tissue tumors and refer to a specialist, patients are still being treated with inappropriate interventions due to misdiagnosis. All patients presenting with a soft tissue mass of the foot and

ankle should receive MRI with contrast prior to medical treatment.<sup>3,4</sup> Patients should also receive MRI with contrast after unplanned excision to evaluate for residual tumor and plan adequate margins.<sup>4</sup> Increased tumor size between the groups affects the prognosis in a negative manner, so early referral to a cancer center is important.<sup>3</sup> Primary amputation is not indicated for soft tissue sarcomas of the foot and ankle.<sup>8</sup> Limb salvage is an appropriate treatment for soft tissue sarcomas, even in patients who have undergone previous unplanned excision.<sup>9,11</sup> These patients should be treated with adjuvant therapies and followed closely to monitor recurrence and achieve functional outcomes.<sup>8,9</sup>

## AUTHORS' CONTRIBUTIONS

All authors participated equally in conception of the research topic, literature review, and extraction of data. LK drafted the introduction, SS drafted the methods, results, and conclusion, AS drafted the discussion. All authors reviewed and approved the final submission.

## STATEMENT OF COMPETING INTERESTS

The authors declare that they have no competing interests.

## REFERENCES

1. Furtado S, Grimer RJ, Cool P, Murray SA, Briggs T, Fulton J, Grant K, Gerrand CH. Physical functioning, pain and quality of life after amputation for musculoskeletal tumours: a national survey. *Bone Joint J.* 2015;97(9): 1284-1290. doi: 10.1302/0301-620X.97B9.35192. [doi].
2. Khan Z, Hussain S, Carter SR. Tumours of the foot and ankle. *Foot.* 2015;25(3): 164-172. doi: 10.1016/j.foot.2015.06.001.
3. Nishimura A, Matsumine A, Asanuma K, Matsubara T, Nakamura T, Uchida A, Kato K, Sudo A. The adverse effect of an unplanned surgical excision of foot soft tissue sarcoma. *World J Surg Oncol.* 2011;9: 160. doi: 10.1186/1477-7819-9-160.
4. Murray D, Topfer J, Decilveo AP, Wittig JC. Benefits associated with early diagnosis and treatment of soft tissue sarcomas of the foot and ankle. *J Foot Ankle Surg.* 2016;55(5): 980-984. doi: 10.1053/j.jfas.2016.05.001.
5. Latt LD, Turcotte RE, Isler MH, Wong C. Soft-tissue sarcoma of the foot. *Can J Surg.* 2010;53(6): 424-431.
6. Kozawa E, Nishida Y, Nakashima H, Tsukushi S, Toriyama K, Kamei Y, Ishiguro N. Foot sarcomas: factors affecting oncological and functional outcomes. *Oncol Lett.* 2012;3(1): 82-88. doi: 10.3892/ol.2011.427.
7. Ring A, Kirchhoff P, Goertz O, Behr B, Daigeler A, Lehnhardt M, Harati K. Reconstruction of soft-tissue defects at the foot and ankle after oncological resection. *Front Surg.* 2016;3: 15. doi: 10.3389/fsurg.2016.00015.
8. Cribb GL, Loo SC, Dickinson I. Limb salvage for soft-tissue sarcomas of the foot and ankle. *J Bone Joint Surg Br.* 2010;92(3): 424-429. doi: 10.1302/0301-620X.92B3.22331.
9. Thacker MM, Potter BK, Pitcher JD, Temple HT. Soft tissue sarcomas of the foot and ankle: impact of

- unplanned excision, limb salvage, and multimodality therapy. *Foot Ankle Int.* 2008;29(7): 690-698.
10. Bishop AJ, Zagars GK, Moon BS, Lin PP, Lewis VO, Guadagnolo BA. Combined limb-sparing surgery and radiation therapy to treat sarcomas of the hands and feet: long-term cancer outcomes and morbidity. *Int J Radiat Oncol Biol Phys.* 2015;92(5): 1060-1068. doi: 10.1016/j.ijrobp.2015.04.022.
  11. Harati K, Kirchhoff P, Behr B, Diageler A, Goertz O, Hirsch T, Lehnhardt M, Ring A. Soft tissue sarcomas of the distal lower extremities: a single institutional analysis of the prognostic significance of surgical margins in 120 patients. *Oncol Rep.* 2016;36(2): 863-870. doi: 10.3892/or.2016.4862.
  12. Houdek MT, Beahrs TR, Wyles CC, Rose PS, Sim FH, Turner NS. What factors are predictive of outcome in the treatment of soft tissue sarcomas of the foot and ankle. *Foot Ankle Spec.* 2016(1).
  13. Salipas A, Dowsey MM, May D, Choong PF. 'Beware the lump in the foot!': predictors of recurrence and survival in bone and soft-tissue sarcomas of the foot and ankle. *ANZ J Surg.* 2014;84(7-8):533-538. doi: 10.1111/ans.12593.
  14. Gross E, Rao BN, Bowman L, Michalkiewicz E, Pappo A, Santana V, Kaste S, Greenwald C, Pratt C. Outcome of treatment for pediatric sarcoma of the foot: A retrospective review over a 20-year period. *J Pediatr Surg.* 1997;32(8): 1181-1184. doi:10.1016/S0022-3468(97)90678-3.

# Surgical Correction of Bilateral Rigid Equinovarus Deformity in a Young Adult Following a Motor Vehicle Accident: A Case Report

Amanda Siegel, BS, Petrina Yokay, BS, & Thomas Vitale, DPM

## Abstract

### Introduction

Motor vehicle accidents (MVA) are a leading cause of injury and death in the United States. These accidents can have devastating neurologic consequences such as traumatic brain injury (TBI), which is the leading cause of acquired spastic limb deformity in young adults. TBIs cause upper motor neuron (UMN) destruction, which leads to spasticity due to overactivity of specific muscle groups and hyperactive stretch reflexes. Equinovarus is the most common foot posture following a TBI due to a functional imbalance of agonist-antagonist musculature in the lower extremity. Functional recovery of motor control after an UMN insult such as TBI can continue for up to 18 months. Therefore, conservative treatment and rehabilitation are encouraged during this period of spontaneous neuromuscular recovery. Surgery is indicated for rigid, fixed contractures that can no longer be corrected with conservative treatments alone.

### Study Design

Case Report

### Case Report

A 23 year old male presented to the orthopedic clinic with spastic paraplegia and bilateral rigid equinovarus foot deformity as a result of a TBI and an anoxic brain injury following a MVA in January 2015. Due to the lack of adequate treatment in the early stages of the patient's recovery, the lower extremity musculature became rigidly contracted. This resulted in a bilateral fixed equinovarus foot posture. One year after the accident, the patient began physical therapy to initiate ambulation, however he has medial knee instability that requires surgical correction. It was deemed necessary by orthopedics that in order to perform knee stabilization surgery, the patient's feet need to be plantigrade in order to be able to perform post-operative rehabilitation. The patient was referred to podiatry. The surgical plan included bilateral Achilles tenotomy and ankle arthrodesis to reduce the rigid equinovarus deformity and stabilize the ankle, performed one limb a time.

### Discussion

Mobilization, bracing, and splinting during the spontaneous recovery period are an important part of rehabilitation to preserve joint function and prevent contractures. After 18 months, neurologic recovery plateaus, and surgery may be indicated as bracing and splinting may not be effective. A lateral approach to ankle arthrodesis was utilized, however the fibula was kept intact for several reasons: (1) it gives the ankle increased lateral stability, (2) the intact fibula acts as a vascularized bone graft and (3) maintaining the fibula allows future conversion to a total ankle arthroplasty, however in this patient, this is highly unlikely.

### Conclusion

Correction of equinovarus deformity will allow the patient to comfortably wear proper shoes and/or braces as well as perform proper rehabilitation needed for recovery. Having a plantigrade foot will also aid in ease of transfers and reduce the development of pressure ulcers. Additionally, successful correction of the deformity will allow orthopedic surgeons to perform knee stabilizing procedures so that the patient can start physical therapy to initiate ambulation.

### Key Words

Traumatic Brain Injury, Equinovarus, Ankle Fusion, Achilles Tenotomy

*Level of Evidence: 4*

## INTRODUCTION

A traumatic brain injury (TBI) is defined as “damage to brain tissue caused by an external mechanical force trauma,” resulting in neurologic dysfunction.<sup>1</sup> TBIs can cause devastating neuromuscular deficits as well as profound long-term disability. TBIs are relatively common, with an incidence of 1.7 million per year and contribute to 30% of all injury-related deaths in the United States.<sup>2</sup> According to the Centers for Disease Control and Prevention, motor vehicle accidents (MVA) are the leading cause of TBI-related death, and rates are highest for adult males aged 20-24 years.<sup>2</sup>

TBIs cause upper motor neuron (UMN) destruction, which can lead to muscle weakness and spasticity due to overactivity of specific muscle groups and hyperactive stretch reflexes.<sup>3,4</sup> Spasticity commonly manifests as contractures of the lower extremity musculature. Equinovarus is the most characteristic foot posture following a TBI and results from a functional imbalance of agonist-antagonist musculature in the lower extremity.<sup>5</sup> The deformity is characterized by overactivity of gastrocnemius, soleus, tibialis anterior, tibialis posterior, flexor hallucis longus, and flexor digitorum longus with weakness of the antagonist muscles peroneus longus and peroneus brevis.<sup>5,6</sup> The main varus-producing force of the equinovarus deformity following a TBI is overactivity of tibialis anterior.

Equinovarus deformity can range in severity from flexible to fixed contractures. If the deformity is not treated soon after the injury, flexible deformities can progress into fixed, rigid deformities as a result of muscle shortening secondary to prolonged contracture.<sup>5</sup> The main factors contributing to the development of ankle contracture after acquired brain injury are altered muscle stiffness and extensibility, which are secondary to disuse and adaptive soft tissue shortening that may occur during prolonged bedrest after injury.<sup>7</sup> Adaptive soft tissue shortening creates muscle imbalances, producing sustained abnormal joint postures.<sup>7</sup> Singer et al concluded that sustained involuntary contraction of the plantarflexor and invertor muscles is strongly associated with development of the equinus ankle contracture.<sup>7</sup>

Functional recovery of motor control after an UMN insult such as TBI can continue for up to 18 months. King et al states that during this time, spasticity can improve with the return of strength, coordination, and sensation.<sup>6</sup> Studies report that up to 70% of patients will be able to ambulate independently within the first 6 months of a TBI.<sup>1</sup> Therefore, conservative treatment and rehabilitation are encouraged during this period of spontaneous neuromuscular recovery. Physical therapy, injections, bracing, splints, and/or progressive casting can also help to maintain joint motion and flexibility of the contractures.<sup>6,8</sup>

Surgery is indicated for fixed contractures that can no longer be corrected with conservative measures alone. Surgical goals of correcting the equinovarus deformity include re-establishing the balance of pull of agonist and antagonist muscles and creating a functional, plantigrade foot with the goal of eventual ambulation. Even if the patient is never able to ambulate, having a plantigrade foot will allow the patient to comfortably wear proper shoes and/or braces as well as perform rehabilitation needed for recovery. Having a plantigrade foot will also aid in ease of transfers and reduce the development of pressure ulcers.

The current study is an evaluation of surgical technique in a patient with a bilateral rigid equinovarus deformity, secondary to spastic ankle equinus, and knee instability as a result of TBI following a MVA.

## CASE PRESENTATION

### *Pre-Operative Evaluation*

A 23 year old male patient presented originally to the orthopedic clinic at Metropolitan Hospital with spastic paraplegia and bilateral rigid equinovarus foot deformity as a result of TBI and anoxic brain injury following a MVA in January 2015. The patient was non-ambulatory and wheelchair-bound, 14 months status-post TBI. The patient was verbal with severe dysarthria and slow cognitive processing. The patient's mother

stated that the patient had been training for the New York City Marathon when he was hit by a car while running in a park in Queens, New York. Following the accident, the patient was in a coma for three weeks at a hospital in Queens, and was then transferred to the Henry J. Carter Specialty Hospital & Nursing Facility, where he currently resides. Prior to the accident, the patient was healthy and physically active with no significant medical history. The patient was originally seen by orthopedics as an inpatient at the hospital in Queens after his accident, where bracing was recommended for his lower extremity contractures. For unknown reasons, the patient was never able to obtain the brace, and the contractures became fixed as the patient remained bedridden. The patient saw a physical therapist at Metropolitan Hospital from December 2015 to February 2016, and was subsequently referred to orthopedics for possible knee ligament reconstruction in order to ambulate.

At the patient's initial orthopedic evaluation on March 23, 2016, physical examination revealed bilateral equinus contractures of the ankle, valgus laxity of the knees bilaterally, and severe atrophy of the lower extremity musculature bilaterally. Examination of the left knee revealed positive posterior sag sign and positive posterior drawer. An MRI was taken of the left knee, which revealed a horizontal tear of the posterior horn of the medial meniscus and a left PCL tear. The patient was

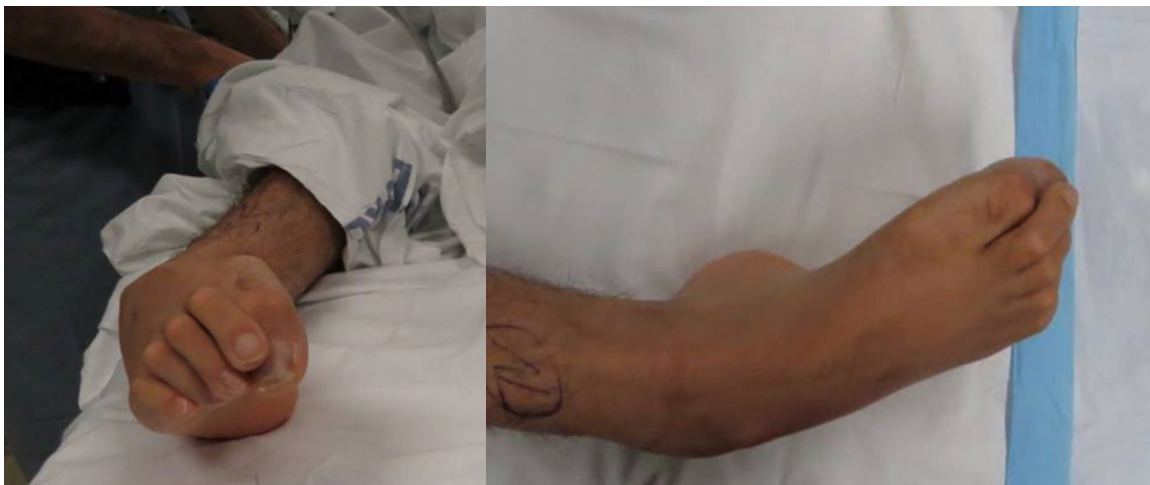

referred to podiatry by his orthopedist, who determined that in order to correct the patient's knee instability, he would first require correction of his bilateral equinovarus foot deformity. Orthopedics would only consider performing the knee-stabilizing procedure if podiatric surgeons could successfully construct a functional, plantigrade foot. Creation of a plantigrade foot followed by subsequent knee-stabilizing procedures would be a prerequisite in order to allow for the patient to participate in physical therapy to initiate ambulation.

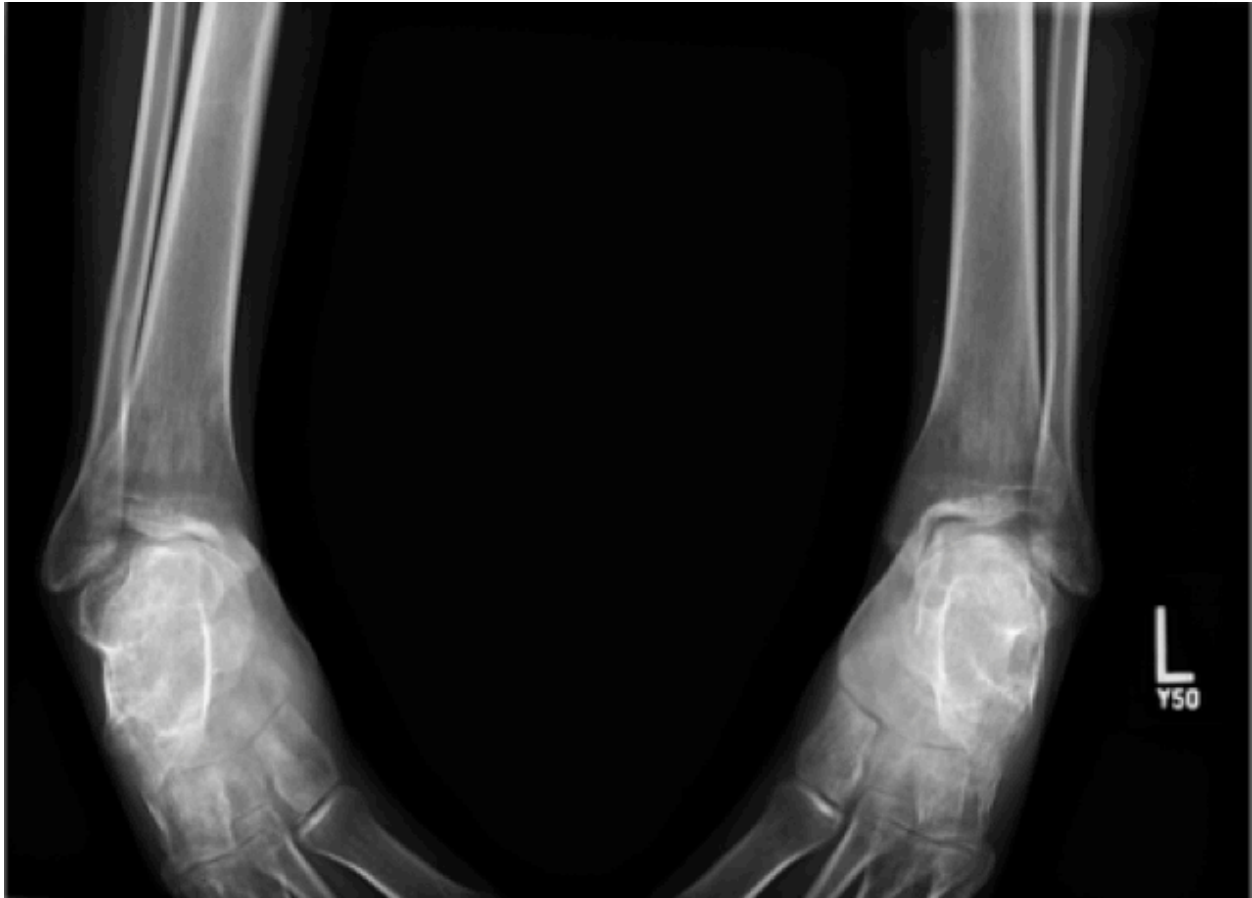
The patient presented to the podiatry clinic in a wheelchair on March 30, 2016, 14 months status post-TBI. On physical exam, the patient was noted to have bilateral spastic contractures of the Achilles tendon (ankle equinus), rigid equinovarus foot deformity (right worse than left), absent ankle dorsiflexion bilaterally, hammered digits 2-5 bilaterally, and severe atrophy of the lower extremity musculature bilaterally (Figure 1).

Bilateral foot and ankle radiographs were ordered. Radiographic evaluation revealed bilateral equinovarus deformity and significant osteopenia of the ankle joint, right worse than left (Figure 2). AP radiographs of the foot revealed a significantly decreased talocalcaneal angle and overcoverage at the talonavicular joint, signifying the varus component of the deformity (Figure 3). Lateral radiographs showed bilateral cavus foot type with increased calcaneal pitch and significant midfoot equinus.

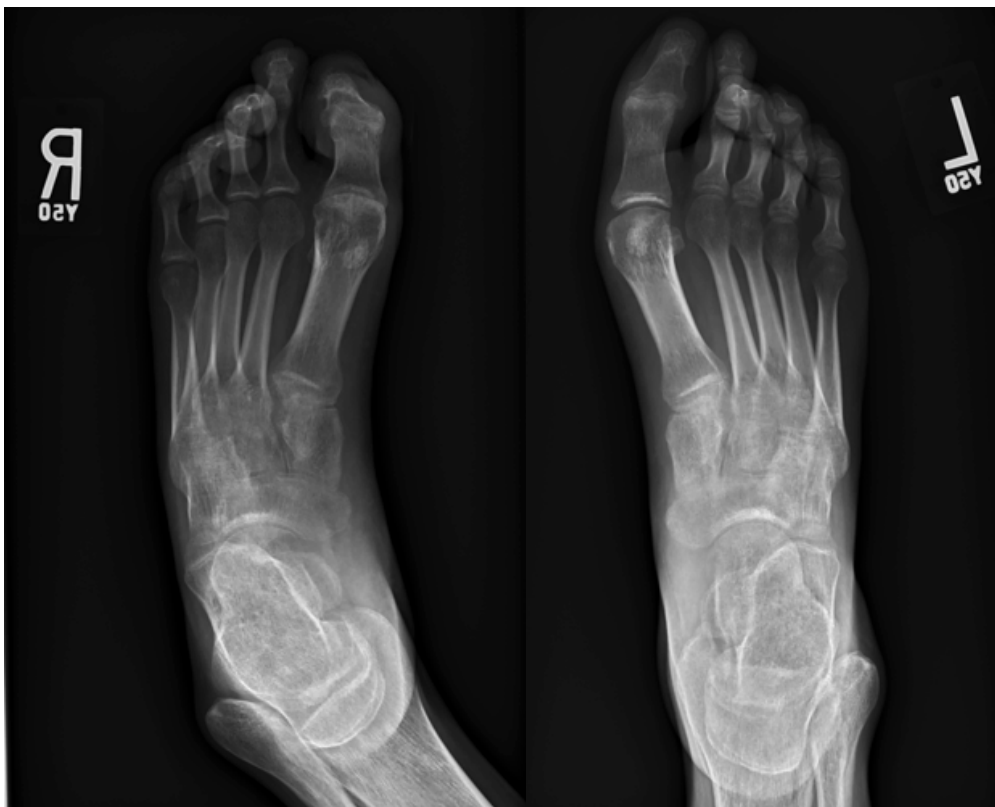The patient was medically cleared for the operation and was determined to be low risk for the procedure. The patient had no cardiac contraindications. Surgery of the left ankle was performed on June 10, 2016 and surgery of the right ankle was performed on November 4, 2016.



**Figure 1:** Pre-op equinovarus position of right foot



**Figure 2:** Pre-op bilateral AP ankle X-rays

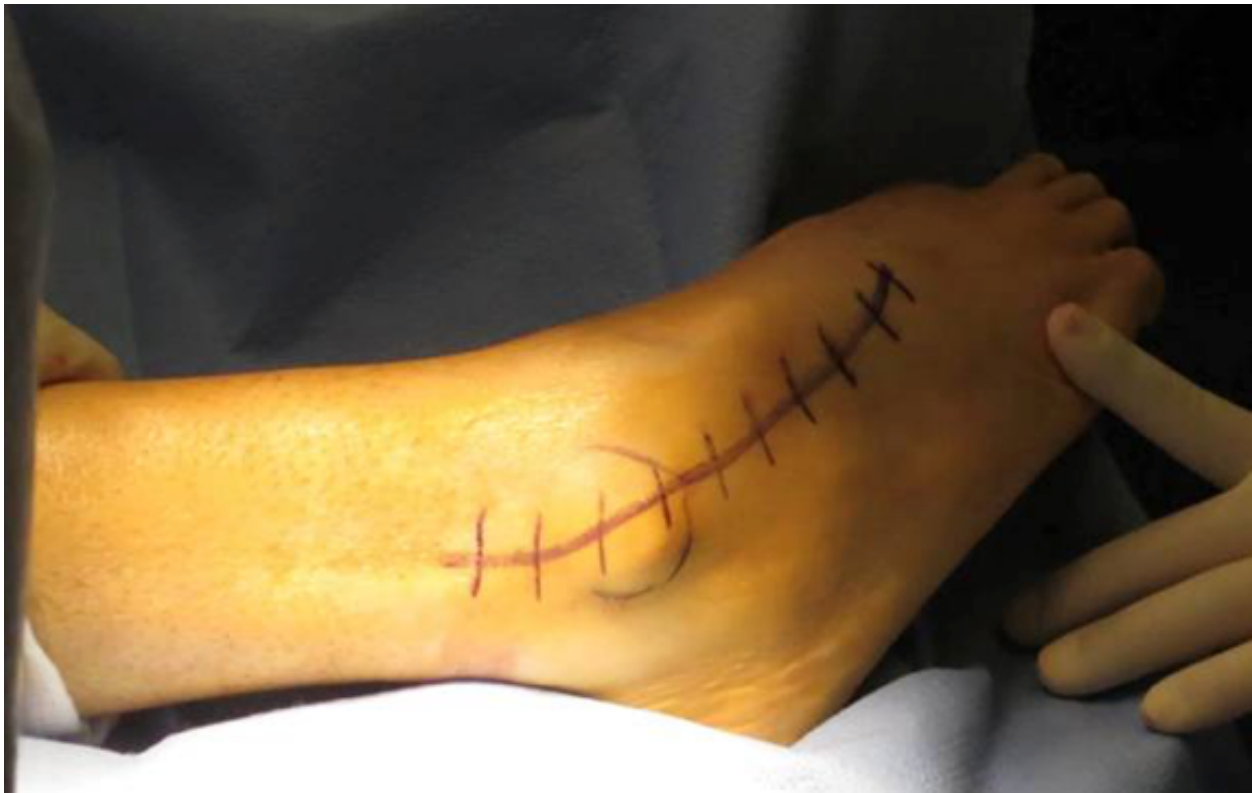

**Figure 3:** Pre-op bilateral AP foot X-rays

***Surgical Technique: Right Ankle Fusion and Achilles Tenotomy***

Attention was first directed to the posterior ankle, where the Achilles tendon was noted to be severely contracted with the ankle in non-reducible equinus. Tendon margins were marked and a percutaneous Achilles tenotomy was performed via lateral and medial stab incisions using a number 15 blade. After release of the Achilles tendon, the ankle equinus improved but was still not completely reducible. The varus contracture remained.

a nearly 10 cm curvilinear incision was made at the distal aspect of the fibula extending to the 4th metatarsal base (Figure 4). Sharp dissection was carried out to the level of the ankle capsule. A full thickness skin flap was then raised medially and laterally. The ankle joint was exposed with careful and sharp dissection of the ankle capsule and periosteum off of the tibia, fibula, and talus. It was noted that there was a severe varus deformity of the ankle and the talar dome was significantly degenerated. The ankle joint was then prepped utilizing osteotomes, mallets, curettes,



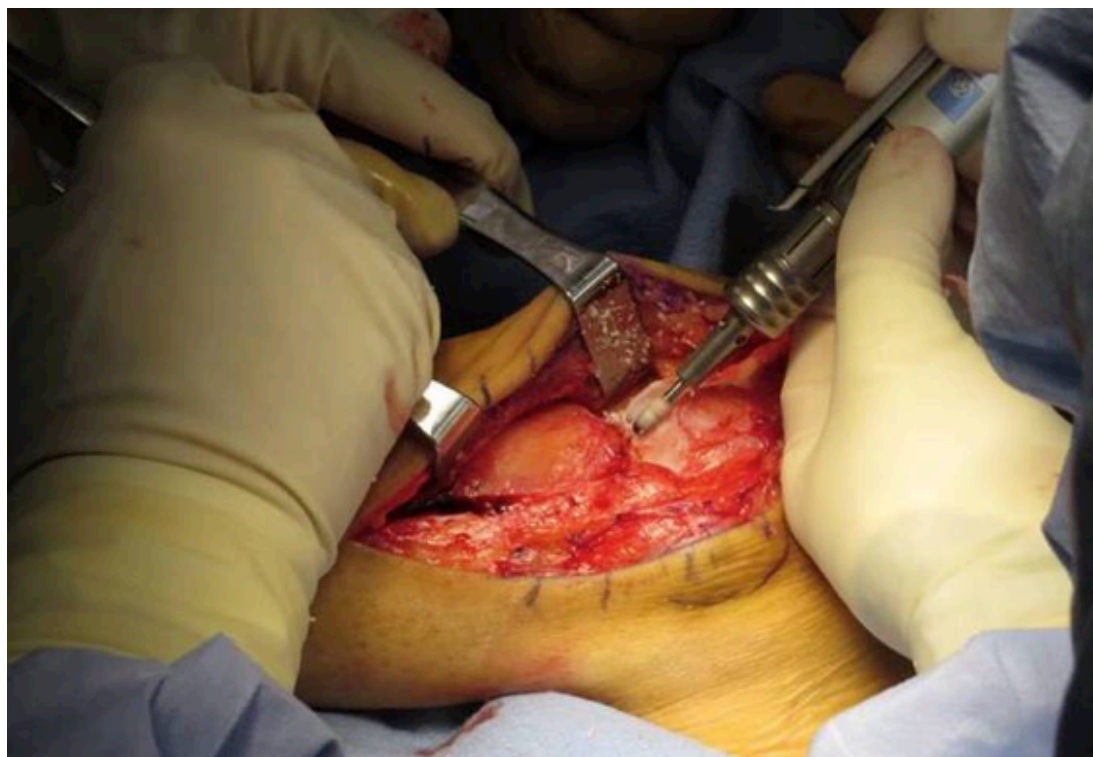**Figure 4:** Lateral incision from distal fibula to base of 4th metatarsal, right ankle joint

Attention was then directed to the lateral aspect of the ankle joint, where

and burrs in attempt to minimize shortening A sagittal saw was utilized minimally. The cartilage of the ankle

joint was resected down to healthy, bleeding subchondral bone. Resected portions included the medial aspect of the fibula, dorsal aspect of the talus, distal aspect of the tibia, and lateral aspect of the medial malleolus.

screws were used: the first screw was placed from the medial aspect of the talus into the lateral aspect of the tibia, the second screw was placed from the lateral aspect of the talus into the tibia, and the third screw was inserted from

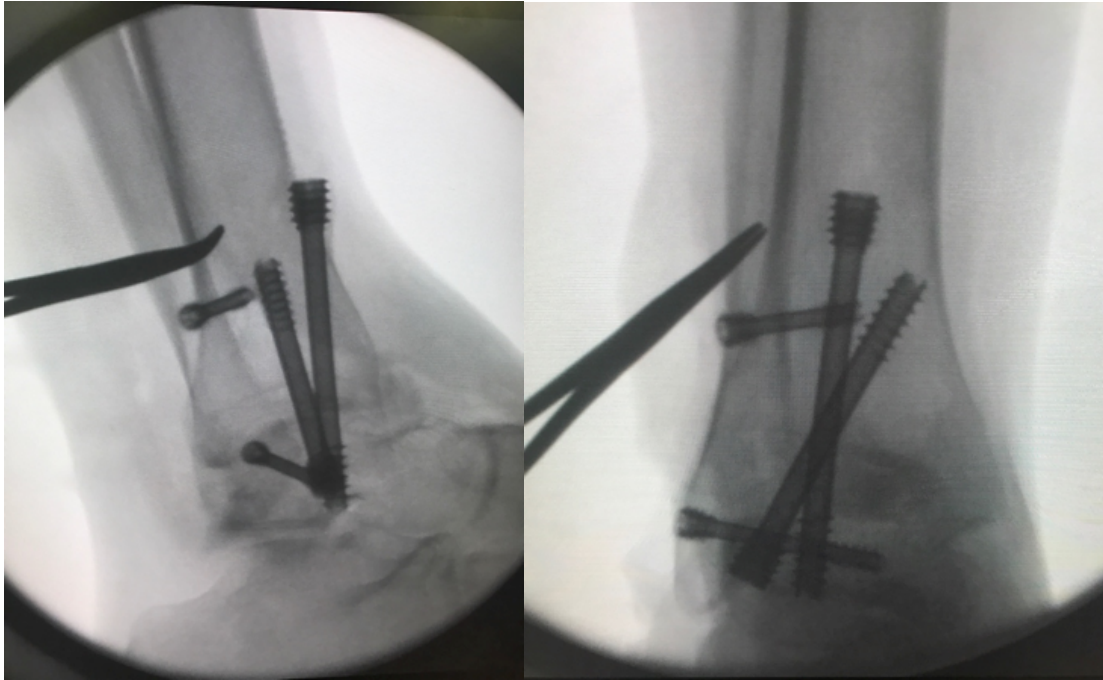


**Figure 5:** Prepping the right ankle joint with a burr

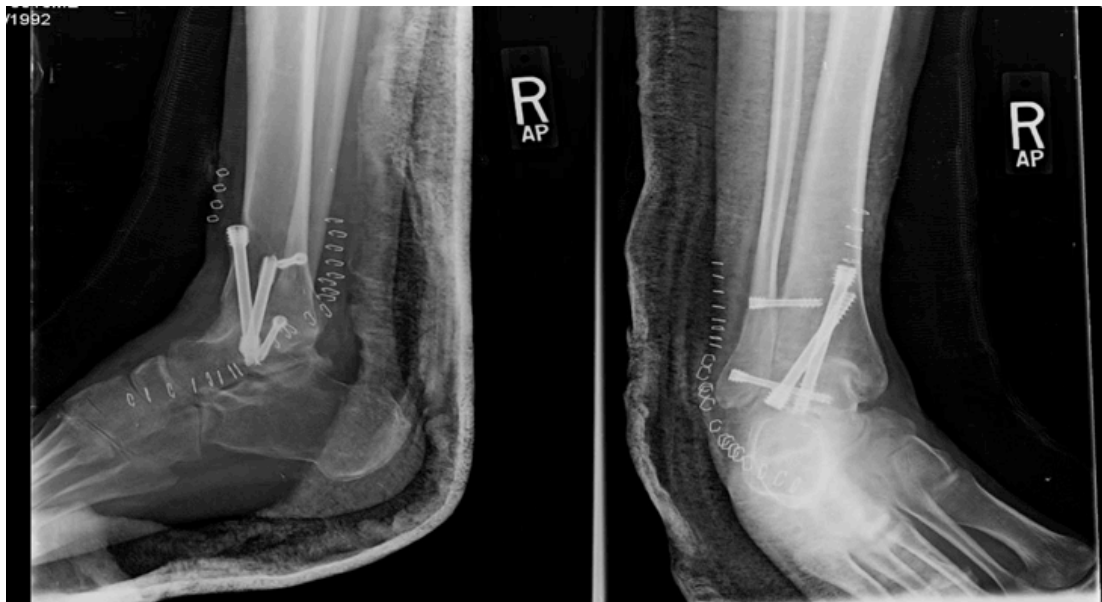Utilizing fluoroscopy and following AO principles, the ankle was positioned in a rectus position with confirmation that all planes (frontal, sagittal, and transverse) were acceptable for fusion. The ankle joint was placed at neutral ( $90^\circ$  to the leg) with slight external rotation ( $5-10^\circ$ ) and slight valgus ( $0-5^\circ$ ). Temporary fixation was applied utilizing a Kirschner wire, and ankle fusion was performed using partially-threaded screws. For the left ankle fusion, three

the lateral aspect of the lateral malleolus into the talus approximately at the proximal aspect of the talar neck. For the right ankle fusion, four screws were used: the first screw was inserted from the distal lateral aspect of the talar body into the proximal, medial aspect of the tibia, the second screw was applied percutaneously from the proximal anterior aspect of the tibia to the distal posterior aspect of the talus to achieve crossing screw construct, the third screw was inserted from the lateral aspect of the lateral





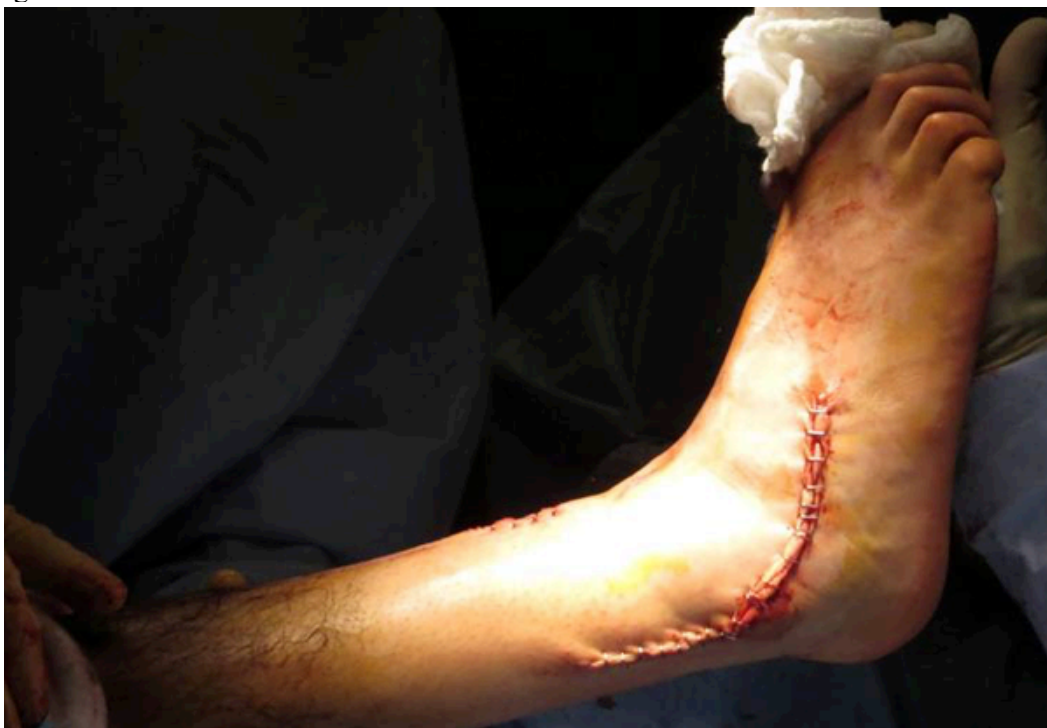**Figure 6:** Intra-op X-rays of the right ankle showing 4 screw configuration



**Figure 7:** Immediate post-op AP x-ray of the right ankle showing the 4 screw configuration

malleolus into the talus the fourth screw was inserted from the lateral fibula into the tibia parallel to the ankle joint and proximal to the syndesmosis (Figures 6-7).

The skin edges were re-approximated using subcutaneous sutures followed by staples (Figure 8). The ankle was dressed with adaptic, 4x4 sterile gauze, ABD pads, Kerlix, and an ace



**Figure 8:** Post-op plantigrade position of the right ankle

bandage. The foot and ankle was then placed in an AO splint.

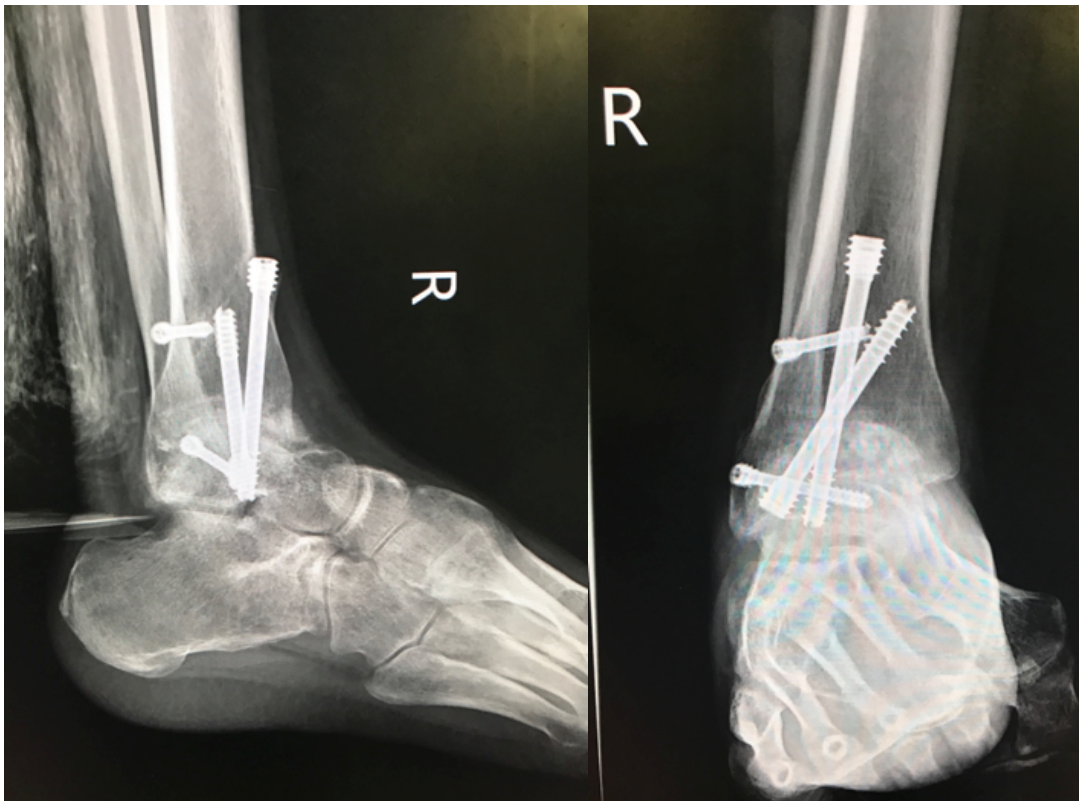
### ***Post-Operative Management***

**Left Ankle:** The patient returned to clinic 1 week post-op where the sutures and staples were intact, however mild edema, erythema, ecchymosis, and increased temperature were noted at surgical site. The patient was placed on Keflex 500 mg BID for 7 days. At 2 weeks post-op, the post-surgical erythema and edema of the left ankle had decreased from the previous week. The incisions were well coapted with no signs of dehiscence, abscess, or hematoma. X-rays of the left ankle were ordered and showed the hardware to be intact and in appropriate alignment. The staples and sutures on the left ankle were removed 4 weeks post-op, where the patient

was placed in a below-knee cast and posterior splint.

**Right Ankle:** The post-op course was similar except the patient was not placed on Keflex and the staples were removed 2.5 weeks post-op.

At 8 weeks post-op, complete consolidation of the fusion site was seen on x-ray for both ankles (Figure 9). The posterior splint is discontinued at this time and the patient is placed into a CAM walker for an additional 6 weeks. Physical therapy is initiated subsequent to each surgery with progressive weight bearing as tolerated 7 months post-op. The patient is scheduled to see orthopedics regarding future knee-stabilizing surgery.



**Figure 9:** 2 months status-post right ankle fusion

## DISCUSSION

### *Neuromuscular Recovery and Bracing*

Mobilization, bracing, and splinting during the spontaneous recovery period are important parts of rehabilitation to preserve joint function and prevent contractures.<sup>3,9</sup> The spontaneous recovery period lasts up to 18 months post-TBI. After 18 months, the neurologic recovery plateaus, and bracing and splinting are no longer as effective.<sup>3</sup> Spastic lower extremity contractures can be corrected via static splinting, dynamic splinting, and orthoses.<sup>3,9</sup> Static splinting helps reduce spasticity by inhibiting joint range of motion,

therefore decreasing stimulation of the stretch reflex. Types of static splints include padded bivalve casts, molded splints, and ankle foot orthoses (AFOs).<sup>9</sup> Dynamic splints allow motion at the joint and are indicated for a patient with a fixed contracture and reduced spasticity. Dynamic bracing should be used with caution, as it can exacerbate the spastic contracture through increased stimulation of the stretch reflex.<sup>9</sup> For more severe equinovarus contractures, an aluminum double upright brace with a plantarflexion stop and a T strap can be utilized to correct the varus deformity.<sup>3</sup> If bracing is inadequate, surgical intervention should wait until the plateau phase of recovery.

In most rehabilitation facilities, AFOs and orthopedic footwear are the first line of conservative treatment.<sup>1</sup> Studies show that early management of equinovarus deformity focuses on preventing formation of rigid contractures with orthotic bracing.<sup>6,10</sup> Woods et al states that “orthotic braces are used to prevent deformities from occurring as a result of poor positioning of a limb while the patient is recovering in bed.”<sup>10</sup> In contrast, there are studies that did not find orthotic bracing in the early stages of recovery to be beneficial in preventing formation of rigid contractures. Singer et al carried out a study on patients post-acquired brain injury who were participating in a daily intensive rehabilitation regimen. The authors concluded that “those who developed contracture did so despite preventative measures such as...splinting to maintain soft tissue length.”<sup>7</sup> They also concluded that “it is not possible to quantify the influence of disuse and paresis on the development of ankle deformity.”<sup>7</sup>

Similar to the Singer et al study, the patient in our case study was living in an inpatient rehabilitation facility for 10 months after his acquired brain injury. However, the patient was unable to obtain a brace even though it was recommended after his accident. It is likely that the patient’s deformity progressed into a rigid contracture because the patient was bedridden and unable to appropriately move the joints or muscles in his lower extremities. Had the patient been

braced within 18 months of the injury, his spastic contractures may not have become fixed, and it is possible that the only procedures necessary to correct the equinovarus deformity would be tendon lengthening and/or releases.

### ***Surgical Approach***

Surgical correction of equinovarus deformity is reserved for patients who failed to respond to conservative treatment, such as orthoses, bracing, casting, and/or chemodenervation.<sup>1,11</sup> Because of the spontaneous neuromuscular recovery that can occur following a TBI, it is advised to defer surgical correction of the deformity, spasticity, and/or contractures until 18 months post-injury.<sup>1, 3, 6, 12</sup> Lawrence et al outlined criteria for when surgical correction is indicated: “(1) the deformity causes significant functional impairment, (2) rehabilitation efforts and bracing attempts have been unsuccessful, and (3) the period of spontaneous neurologic recovery has ended.”<sup>3</sup> There are various approaches to surgical correction of equinovarus deformity, all of which share the goal of establishing a plantigrade foot that is stable and functional. Different approaches include tendon lengthening, tendon transfers, ankle fusion, fibula extension, talectomy, and multi-planar external fixation. The procedure of choice depends on the nature and severity of the deformity, including how reducible or rigid the deformity is and how long the deformity has been present. Tendon



transfers and/or lengthening are used if the equinovarus deformity is easily reducible. Commonly, a Tendo Achilles lengthening (TAL) or a triple hemisection tenotomy (Hoke lengthening) is used to correct the equinus deformity and a split anterior tibialis tendon transfer (SPLATT) is used to correct the varus component.<sup>6</sup> An ankle joint arthrodesis, or fusion, has been termed a last-resort procedure in the management of severe equinovarus deformity.<sup>13</sup>

Numerous approaches to ankle arthrodesis have been described, which include arthroscopic, mini-arthrotomy, and open joint resection. The open approach is the preferred method for significant deformities, as it provides better access to the ankle joint. Over 30 approaches to open ankle fusion have been described, which include lateral transfibular, medial, and posterolateral.<sup>13, 14</sup> The lateral transfibular approach uses a 10 cm curvilinear incision from the distal fibula to the base of the 4th metatarsal, the medial approach uses a 6 cm curvilinear incision from the posterior medial malleolus to a point 1 cm below the sustentaculum tali, and the posterolateral approach uses an 8 cm longitudinal incision lateral to the Achilles tendon extending to the calcaneal tuberosity.<sup>13</sup> The lateral transfibular approach is considered to be the gold standard approach, as it causes the least risk to arterial structures and provides maximal exposure for articular cartilage removal from the ankle joint.<sup>13</sup> Wapner states that the lateral

transfibular approach “offers the advantages of excellent exposure, the ability to minimize wound problems by developing full thickness flaps, and the availability of the distal fibula for local bone graft.”<sup>14</sup> The posterolateral approach is most likely to cause vascular compromise due to close proximity of the incision to the lateral malleolar branches of the peroneal artery.<sup>13</sup> The medial approach has the advantage of being able to include a medial malleolar osteotomy, which provides more exposure during surgery and is the best approach if the patient has significant valgus deformity.<sup>13</sup> However, the medial approach makes the venous structures and saphenous nerve most vulnerable to damage. A posterior approach has also been described. The incision is made parallel to the Achilles tendon and between angiosomes, so it has been shown to have a much better outcome from the standpoint of wound dehiscence.<sup>15</sup>

For the patient in this case report, an Achilles tenotomy and ankle fusion were required to bring the ankle into neutral position due to the fixed nature of the bilateral equinovarus deformity. The Achilles tenotomy was performed prior to the ankle fusion because of the patient’s severe soft tissue contractures, likely due to inadequate bracing in the 18 month period after his injury. Releasing the Achilles tendon allowed for the surgeon to position the ankle into neutral position before performing the ankle fusion. An ankle joint fusion was determined to be a viable option as the patient had

optimal motion at the oblique mid-tarsal joint (OMTJ) axis, and thus would be able to compensate at the OMTJ for loss of sagittal plane dorsiflexion at the ankle joint post-operatively. A lateral approach to ankle arthrodesis was used without going transfibular. The fibula was kept intact for several reasons: (1) it gives the ankle increased lateral stability, (2) the intact fibula acts as a vascularized bone graft and (3) maintaining the fibula allows future conversion to a total ankle arthroplasty, however in this patient, this is highly unlikely. According to Pellegrini et al, “preserving the fibula can strengthen the construct laterally, helping to prevent valgus drift.”<sup>15</sup> The lateral approach also allowed for creation of a U-shaped flap, which provided optimal exposure of the articular surfaces. Because the patient had significant equinovarus deformity, realignment fusion was performed. Curettes and osteotomes were used to resect the least amount of bone in order to avoid shortening, as they help to maintain the concavity and convexity of the tibia and talus, respectively. This method is preferred over a wedge resection, which can create significant pathologic shortening.

Screw fixation is the gold standard for ankle fusion as it leads to compression, rigidity, and earlier fusion of the site. Screws placed parallel from infralateral to superomedial increase the compression, whereas screws that are crossed increase the rigidity due to

increased torque.<sup>14</sup> In comparing two vs three screw fixation in a crossed configuration, Ogilvie-Harris et al found that three screws gave increased compression and resistance to torque and that insertion of the first screw should be from the lateral aspect in order to get better compression.<sup>16</sup> When the structural integrity of the fusion site is questionable, a third screw is often used from the posterolateral aspect of the distal tibia and directed down to the talar neck.<sup>14</sup> In our patient, a crossing screw construct was achieved by inserting a screw from the distal lateral aspect of the talar body to the proximal medial aspect of the tibia and by inserting a second screw percutaneously from the proximal anterior aspect of the tibia to the distal posterior aspect of the talus. Multiple screws were used in both ankles due to the questionable structural integrity of the fusion site, as seen on pre-operative radiographs.

### ***Complications***

It was noted that once the ankle was released from equinus via Achilles tenotomy, fusing the ankle in neutral position put stretch on the tendons and ligaments, which then positioned the forefoot in slight varus. Varus deformity puts increased stress on the lateral border of the foot and can cause subtalar joint instability.<sup>14</sup> A patient cannot easily compensate for varus deformities. Therefore, it is possible that the patient will need orthotic devices to ameliorate the varus deformity or will require forefoot varus corrective procedures

in the future. Further surgery will be dependent on how well the patient will be able to get into a shoe and wear an orthotic or brace post-operatively.

## CONCLUSION

Ankle joint arthrodesis is indicated in patients with bilateral rigid equinovarus deformity where conservative treatment measures have failed. In patients who have suffered a TBI, bracing and splinting should be utilized within the 18 month period of spontaneous neurologic recovery to prevent formation of a rigid contracture. Surgery may only be considered after 18 months. Although the patient may never ambulate, having a plantigrade foot will increase the patient's quality of life in many ways. It allows the patient to fit into shoe gear and participate in physical therapy exercises, which may prevent formation of additional contractures. A plantigrade foot will also allow for ease of transfers and prevent pressure ulcers from developing on the lateral aspect of the foot.

In conclusion, overall quality of life and functionality for TBI patients can be greatly increased if the proper bracing and surgical procedures are utilized to reduce contractures and create a plantigrade foot. This case represents the end result of improper post-injury care that ultimately resulted in the patient undergoing bilateral ankle fusions and Achilles tenotomies. The ability to correct supra-structural issues is dependent on having a plantigrade foot and ankle. The hope is that the patient's quality

of life will be improved and that he will be able to progress to a weight bearing status.

## AUTHORS' CONTRIBUTIONS

All authors participated equally in the conception of the research topic, literature review, and extraction of data. All authors agreed upon the final submission.

## STATEMENT OF COMPETING INTERESTS

The authors declare that they have no competing interests.

## REFERENCES

1. Renzenbrink GJ, Buurke JH, Nene AV, Geurts AC, Kwakkel G, Rietman JS. Improving walking capacity by surgical correction of equinovarus foot deformity in adult patients with stroke or traumatic brain injury: A systematic review. *Journal of Rehabilitation Medicine*. 2012;44(8): 614-623.
2. Faul M, Xu L, Wald MM, Coronado VG. Traumatic Brain Injury in the United States: Emergency Department Visits, Hospitalizations and Deaths 2002–2006. Atlanta (GA): Centers for Disease Control and Prevention, National Center for Injury Prevention and Control; 2010.
3. Lawrence SJ, Botte MJ. Management of the adult, spastic, equinovarus foot deformity. *Foot & Ankle International*. 1994 Jun;15(6): 340-346.
4. Keenan MA. The management of spastic equinovarus deformity

- following stroke and head injury. *Foot Ankle Clin. N Am* 16 (2011) 499-514.
5. Giannotti E, Merlo A, Zerbinati P, Longhi M, Prati P, Masiero S, Mazzoli D. Early rehabilitation treatment combined with equinovarus foot deformity surgical correction in stroke patients: safety and changes in gait parameters. *European Journal of physical and rehabilitation Medicine*. 2016 June;52(3):296-303.
  6. King BW, Ruta DJ, Irwin, TA. Spastic foot and ankle deformities: Evaluation and treatment. *Foot and Ankle Clinics. N Am* 19 (2014) 97-111
  7. Singer BJ, Jegasothy GM, Singer KP, Allison GT, Dunne JW. Incidence of ankle contracture after moderate to severe acquired brain injury. *Archives of Physical Medicine and Rehabilitation*. 2004;85(9):1465-1469.
  8. Bell K, DiTommaso C. Spasticity and traumatic brain injury. *Archives of Physical Medicine and Rehabilitation*. 2016;97(1):179-180.
  9. Botte MJ, Bruffey JD, Copp SN, Colwell CW. Surgical reconstruction of acquired spastic foot and ankle deformity. *Foot and Ankle Clinics*. 2000 Jun;5(2):381-416.
  10. Woods RJ, Cervone RL, Fernandez HH. Common neurologic disorders affecting the foot. *Journal of the American Podiatric Medical Association*. 2004;94(2):104-117.
  11. Reddy S, Kusuma S, Hosalkar H, Keenan M. Surgery can reduce the nonoperative care associated with an equinovarus foot deformity. *Clin Orthop Relat Res*. 2008;466(7):1683-1687.
  12. Keenan MA, Creighton J, Garland DE, Moore T. Surgical correction of spastic equinovarus deformity in the adult head trauma patient. *Foot & Ankle*. 1984 Jul-Aug;5(1):35-41.
  13. Rausch S, Loracher C, Fröber R, Gueorguiev B, Wagner A, Gras F, Simons P, Klos K. Anatomical evaluation of different approaches for tibiototalcalcaneal arthrodesis. *Foot & Ankle International*. 2014;35(2):163-167.
  14. Wapner KL. Transfibular ankle fusion technique. *Techniques in Foot & Ankle Surgery*. 2002;1(1):17-23.
  15. Pellegrini MJ, Schiff AP, Adams Jr. SB, DeOrio JK, Easley ME, Nunley II J A . Outcomes of Tibiototalcalcaneal Arthrodesis Through a Posterior Achilles Tendon-Splitting Approach. *Foot & Ankle International*. 2015;37(3):1-8.
  16. Ogilvie-Harris DJ, Fitsialos D, Hedman TP. Arthrodesis of the ankle. A comparison of two versus three screw fixation in a crossed configuration. *Clin Orthop Relat Res*. 1994 Jul;(304):195-9.

# Arthroscopic Brostrom Repair Versus Open- Brostrom for Lateral Ankle Instability: Current Literature Review

Charles Hu, BS, Caroline Tippett, BS, Hesam Naenifard, BS, MPH, & Fawzy Ibrahim, BA

## Abstract

### Introduction

Chronic lateral ankle instability is an orthopedically common and debilitating problem. When conservative treatment fails, it is necessary to consider surgical repair. The open modified Brostrom Gould technique is the current gold stand for lateral ankle ligament repair. However, per recent literature in 2015 from Acevedo and Mangone, arthroscopic modifications to the Brostrom are gaining popularity and continue to have promising results. The purpose of this systematic review is to present these novel arthroscopic modifications and compare their efficacy with the efficacy of traditional Brostrom as well as other published arthroscopic modifications of the Brostrom procedure for lateral ankle repair.

### Study Design

Qualitative Systematic Literature Review

### Methods

A PubMed and Cochrane database search using the keywords “arthroscopic AND brostrom” was performed. At the time the search was performed, Pubmed yielded 29 results and Cochrane yielded 0 results. Out of these 29 papers 19 articles were eliminated, specifically articles written before 2015. After careful analysis of the remaining ten papers, seven papers were selected for this systematic review.

### Results

Of the reviewed articles, two cadaveric studies measured maximum load to failure, degrees to failure, torque to failure, and stiffness following different arthroscopic techniques. The remaining five articles were clinically-oriented detailing specific procedures including, but not limited to, the use of bone tunnels, suture anchor constructs, and internal braces in conjunction with arthroscopic Brostrom procedure. While some of these constructs are well-known and widely practiced, others are novel and exploratory. Clinical outcomes of the studies measured pre- and post-op courses via the American Orthopedic Foot and Ankle Score (AOFAS), Visual Analog Scale (VAS), Karlsson-Peterson score (K-P), and time to full weight-bearing/sporting activities.

### Discussion and Conclusions:

Arthroscopic procedures give physicians the advantage of dealing with intra-articular pathologies prior to ankle stabilization. Minimal invasion allows for rapid healing and return to daily activities. However, there remains the risk, albeit low when compared with open procedures, of sural nerve damage, limited visualization, and lack of operator proficiency for arthroscopic Brostrom repairs. Among the various arthroscopic Brostrom techniques employed, the use of a double-row 3 suture-anchor provided the greatest AOFAS score with the quickest return to full-weight bearing and the fastest onset for beginning physical therapy. However, more randomized controlled trials should be performed comparing different arthroscopic techniques side-by-side.

### Key Words

arthroscopic repair; ATFL, lateral ankle ligaments, modified Brostrom, ankle instability

*Level of Evidence: 4*

## INTRODUCTION

Lateral ankle injuries are some of the most common injuries that occur among athletes. It is estimated that ankle injuries account for 10% of all emergency department visits.<sup>1</sup> Ankle sprains account for 20% to 40% of all athletic injuries.<sup>2</sup> Previous studies performed with younger athletes revealed 14% of the recorded sports injuries (14 sports) involve the ankle. Of these injuries, 85% were ankle sprains, many of which were caused by excessive inversion, plantar flexion, and internal rotation.<sup>3</sup> More recent epidemiological studies performed on collegiate sports indicate lateral ligament complex (LLC) injuries were the most frequently sustained injuries by athletes. In general, inversion ankle sprains involving the LLC, which consist of the anterior talofibular ligament (ATFL), calcaneofibular ligament (CFL), and posterior talofibular ligament, can lead to recurrent or chronic ankle instability in approximately 20% of patients after initial injury.<sup>1</sup>

Chronic lateral ankle instability manifests itself as recurrent sprains, difficulty walking on uneven ground, swelling, and possibly pain upon motion. Sprains to the LLC are often graded by anatomic or functional classifications<sup>4</sup> (Table 1). Physicians primarily opt for a conservative treatment protocol for a minimum of 3 months before aggressive intervention is considered. Non-surgical treatment

options, which include rest, icing, compression, peroneal muscle strengthening, ankle bracing, and physical therapy, have a success rate of 80%.<sup>1</sup> Recurring ankle instability after 4 months of conservative treatment provides indication for surgical repair.<sup>5</sup> Individuals suffering from chronic ankle instability often exhibit decreased proprioception, decreased activity levels, as well as the increased risk for developing new ankle sprains. It is therefore imperative to adequately treat LLC injuries before they evolve into potential life-altering complications.<sup>1</sup>

**Table 1. Classifications of Ankle Sprains**

<b>Anatomic Classification of Ankle Sprains</b>	
Grade I	LLC stretched
Grade II	Partial LLC tear
Grade III	Complete rupture of LLC

<b>Functional Classification of Ankle Sprains</b>	
Grade I	Full weight-bearing and ambulation
Grade II	Noticeable limp during ambulation
Grade III	Unable to ambulate

### *Surgical Options*

Surgical treatment of the LLC is typically differentiated into anatomic or nonanatomic. Nonanatomic reconstructive repairs use local anatomy to restrain range of motion at the subtalar joint often via the Evans tenodesis procedure.<sup>1,5,7</sup> These reconstructions tend not to mimic actual foot anatomy but use present anatomical structures to limit subtalar motion.<sup>6</sup> Limiting inversion/eversion help to prevent chronic inversion sprains, but can subsequently impact

post-operative biomechanics and loading of all other parts of the foot.<sup>1</sup>

Anatomic repairs, such as the Brostrom procedure, involve repair of the injured LLC through shortening the ATFL and other lateral collateral ligaments before reattaching them to the distal fibula.<sup>8</sup> Often, the etiology of inversion sprains include ligamentous laxity and overall attenuation of the ATFL. Therefore, shortening the ATFL helps to correct the pathologically less robust, attenuated ligament. The Gould modification introduced the addition of mobilizing the lateral portion of the inferior extensor retinaculum and fixating it to the distal fibula. Substantial subtalar motion and anatomy is maintained while adequate mechanical restraint is established to prevent chronic ankle instability. Brostrom himself reported an 80% success rate from solely shortening, imbrication, and fixation of the LLC to the fibula. However, subsequent modifications to the Brostrom and Brostrom-Gould procedure have shown success rates of well over 90%.<sup>6,8,9</sup>

### *Arthroscopic Repair*

Minimally invasive surgical techniques have quickly become the standard of care, particularly regarding knee and shoulder arthroscopic repair. Reported advantages of arthroscopic technique in shoulder and knee procedures include a shorter recovery time, decrease in trauma to surrounding

structures, and concomitant resolution of intra-articular pathologic findings.<sup>10,11</sup> These advantages are especially helpful for professional athletes hoping to return to normal athletic activities. On the other hand, some research has revealed that the reported times to return to daily activities in the past have been overly optimistic.<sup>13</sup> While extensive research is available for the efficacy of arthroscopic knee and shoulder repair, there remains a small amount of information regarding the practice of arthroscopic ankle repair. A reason for the lack of a universally practiced arthroscopic ankle repair procedure may be lack of adequate exposure during surgery.<sup>1,2,3</sup> However, there is no definitive consensus on the most efficacious technique for arthroscopy of the ankle and the present techniques require continued refinement.

Acevedo and Mangone provided a detailed report regarding the history and evolution of arthroscopic lateral ankle stabilization. Certain studies have shown that arthroscopic repair of the CFL can lead to extensor tendon and superficial peroneal nerve entrapment.<sup>14</sup> Acevedo and Mangone<sup>12</sup>, on the other hand, stated that Brostrom repair using just the ATFL, inferior extensor retinaculum, and capsule provided adequate long-term results. Despite being clinically successful, there is a small amount of biomechanical data available that assesses the maximum load an arthroscopically repaired ankle can withstand.

Their review successfully outlined some recent procedures up to 2015. The purpose of this literature review is to expose recently published research comparing the arthroscopic versus open modified Brostrom techniques, and to expose the most recent arthroscopic Brostrom surgical techniques that have not been included in other reviews published prior to 2016.

## METHODS

The literature search was performed using PubMed and Cochrane databases. Articles applicable to the arthroscopic lateral ankle instability were found using the search term “Arthroscopic Brostrom”. The Cochrane database search yielded 0 results, while the PubMed search yielded 29 potential articles. Nineteen articles that were not written in the English language along with papers published prior to 2016 were excluded. Of the 10 potential articles that fit this inclusion criteria, 3 articles did not detail a modified Brostrom procedure or were not performed arthroscopically and were subsequently excluded. The 7 remaining articles found at the time this search was performed were included in this systematic review and fit the criteria of elucidating arthroscopically performed Brostrom procedures (or any of its modifications).

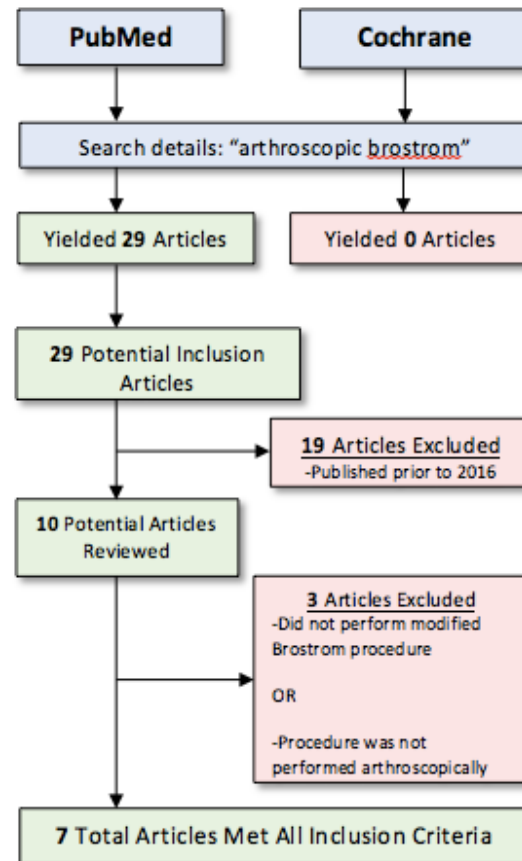


Figure 1. CONSORT diagram. Inclusion and Exclusion Criteria

## RESULTS

### *Labral Tape and Suture anchor constructs (cadaveric)*

In the cadaveric study by Cottom et al., three arthroscopic techniques for lateral ankle stabilization were compared with one being a novel “knotless” approach. From the 36 cadaver limbs obtained (from 18 pairs), 3 groups were formed through random selection with each group containing 12 limbs. The ATFL was intentionally dissected before being repaired by one of the three techniques.<sup>15</sup>



Group 1 underwent repair with a single-row construct with 2 bioabsorbable suture anchors. The first anchor was placed 1 cm dorsal to the tip of the fibula, and the second anchor just proximal to the first anchor. The two corresponding no. 1 suture strands were passed through the ATFL and inferior extensor retinaculum before being knotted to their respective suture anchors.<sup>15</sup>

Group 2 underwent the novel “knotless” approach, which involves a double-row construct with 4 anchors utilizing Labral Tape™ (Arthrex) in the anchors. The first 2 anchors were placed in similar positions as Group 1. The corresponding anchor tape was also passed through the ATFL and inferior extensor retinaculum in a fashion similar to the first group. At this point, a separate more proximal incision was made to visualize the proximal fibula before 2 more drill holes were placed. One strand from each distal anchor was fixated with an anchor proximally in one of the drill holes, while the remaining 2 were fixated in the other proximal drill hole, ultimately resulting in a crossed knotless suture anchor construct.<sup>15</sup>

Group 3 underwent a double-row construct with 3 suture anchors. The first 2 bioabsorbable suture anchors were placed in the anterior fibula in the same manner as Group 1. Again, the sutures were passed through the ATFL and inferior extensor retinaculum. Instead of 2 drill holes placed above the first 2 suture anchors (as in Group 2), only one drill hole

was placed in the proximal fibula whereby the no. 1 suture strands were fixated with a third bioabsorbable anchor.<sup>15</sup>

Mechanical stress was applied to the foot that was placed in 20° of inversion and 10° of plantarflexion. Force (15 N) was applied and held over a period of 15 seconds before additional displacement pulled the foot and ligaments to failure (Table 1). Group 1 resisted the lowest maximum load to failure (156.43 N ± 30.39), followed by Group 2 (206.62 N ± 55.62). Of the 3 groups, Group 3 (double-row with 3 suture anchors) showed moderate stiffness while able to resist the greatest load to failure (246.82 N ± 82.37). Only the difference in strength between Group 1 and Group 3 showed statistical significance (p = .006). There was, however, no statistically significant difference between the stiffness of the groups. Group 1 had the least stiffness (12.10 N/mm ± 5.43), followed by Group 3 (12.55 N/mm ± 4.00), with the Group 2 being the stiffest, although having the greatest variability (13.40 N/mm ± 7.98; Fig. 2).<sup>15</sup>

This was the first study incorporating LabralTape™ (which is primarily used to repair glenohumeral instability) to repair lateral ankle instability. LabralTape™ has lower incidence of tissue tear-through than other suture types, but may have been weaker than the Group 3 construct due to the lack of a tied knot.<sup>15</sup> Additional studies in a

clinical setting are detailed below in Cottom's subsequent research.

*Comparison of Open and Arthroscopic procedures using suture anchors (cadaveric)*

Lee et al. compared the stiffness and strengths of the open and arthroscopic modified Brostrom operations. Authors hypothesized that the arthroscopic modified Brostrom operation using a suture anchor and open modified Brostrom operation would result in equal ligament strength and stiffness. This study evaluated human cadaveric lower extremities from 7 males and 4 females with an average age of 71 years. The individual legs of each cadaver were repaired using one of the two techniques in an alternating fashion. Prior to repair, both the ATFL and calcaneofibular ligaments were uniformly transected.<sup>16</sup>

For the open modified Brostrom procedure, a 5-cm long incision was made between the sural and superficial peroneal nerves, around the anterior aspect of the fibular border. The capsule was then exposed, and any malformations in the ATFL were repaired. Remaining local tissue was repaired with 2-0 Ethibond. Finally, the inferior extensor retinaculum was sutured to the fibula via the "pants-over-the-vest" method used by Gould.<sup>9</sup>

Alternatively, for the arthroscopic Brostrom technique, any intra-articular pathology was treated prior

to LLC repair. The accessory fiber of the distal tibiofibular ligament was also trimmed to aid in anchor insertion. A hole was drilled perpendicularly to the anterior surface of the fibula. The anchor was then inserted through the anterolateral portal. Additional portals were made; an antero-inferior portal near the sinus tarsi, as well as a far lateral portal over the anterior fibula. Two sutures, a FiberWire and TigerWire, were tagged to an absorbable Bio-Suture Tak. The alternate ends of each suture were strung through and fashioned into a knot while the foot was everted and dorsiflexed.<sup>16</sup>

To test the biomechanics of the ankle, a unique jig was created allowing the tibia, fibula, and calcaneus to be fixed with a reinforcing bar. The ankle joint was arrested at 15 degrees of internal rotation and 20 degrees of plantarflexion. Preconditioning of the foot was set to 3 degrees of inversion for 20 cycles at 2 degrees per second (deg/s). The test itself comprised of a steady increase of ankle inversion from 0-70 degrees inverting the ankle at 5 deg/s.<sup>16</sup>

Results (Table 2) showed that there was no significant difference in torque to failure and degrees of failure between the open and arthroscopic modified Brostrom operation ((Torque to failure: 19.9 (SD=8.9) vs. 23.3 (SD=12.1) respectively; Degrees of failure: 46.8 (SD=9.9) vs. 46.7 (SD=7.6) respectively). Average working construct stiffness in the open modified Brostrom operation was 43.7

(SD=21) as compared to 48.7 (SD=26.8; Fig. 3) in the arthroscopic operation (with no marked difference).<sup>16</sup>

*Arthroscopic Brostrom using a Double Row, 3 Suture Anchor Technique in the Clinical Setting*

Cottom et al. extrapolated the findings of their own cadaveric studies by applying them in a clinical setting. They used the most stabilizing suture anchor construct and performed a prospective study with 45 different ankles. Prior to the ankle stabilization, patients underwent a series of non-operative therapies including bracing, rest, ice therapy, and anti-inflammatory medications. On average, the authors' conservative therapy lasted approximately 10.6 months without improvement. Failure to improve allowed inclusion into the prospective study involving arthroscopic Brostrom ankle stabilization with suture anchors. Exclusion factors for this study included (but were not limited to): prior ankle procedures, hyperlaxity, paralysis, history of surgery to treat osteochondral lesions, etc. Due to the nature of arthroscopic procedures, the researcher was able to treat any intra-articular pathologies prior to the stabilization procedure. Any extra-articular pathologies were fixed after the ankle was stabilized.<sup>17</sup>

The Brostrom technique utilized by the researcher involved 2 bioabsorbable suture anchors with a third suture anchor proximally for

additional stability. This was similar to Group 3 of Cottom et al.'s cadaveric study in which a double-row 3 suture anchor construct was utilized. Results revealed a mean of 3.3 (range 2 to 4) days post-op before patients were weight-bearing with the help of crutches and CAM boot. The mean time to full weight-bearing was 14.4 (range 12 to 16) days post-op. Due to the relatively rapid recovery time to weight-bearing, physical therapy could begin 21.6 (range 18 to 23) days post-op. Finally at 28 days post-op patients were encouraged to return to normal footwear with an ankle brace. The American Orthopedic Foot and Ankle Score (AOFAS) improved from 48.7 (pre-op) to 95.4 (post-op) with a decrease in patient-reported Visual Analog Score (VAS) from 8 to 0.6 and an average Karlsson-Peterson (K-P) score of 87 out of 100 (post-op) (Table 4).<sup>17</sup>

*Comparison of the Open and Arthroscopic techniques in a clinical setting*

Yeo et al. compared clinical and radiologic outcomes of modified arthroscopic and modified open Brostrom techniques. Ankles (23) were repaired with an open modified Brostrom and 25 ankles repaired an all-inside arthroscopic modified Brostrom group. Procedures were performed by the same surgeon.<sup>18</sup>

The protocol for the open procedure began with the diagnosis of intra-articular lesions with arthroscopy. The rest of the procedure follows the

standard protocol for the non-arthroscopic Brostrom-Gould procedure.<sup>18</sup>

The arthroscopic procedure employed reflected the procedure used in Lee's cadaveric study. It begins with removal of any osteochondral lesions, before a drill hole was made in the anterior fibula. Insertion of a suture anchor was placed last. Sutures were passed through the anterolateral portal to the anteroinferior portal before it was pulled out through the anterior fibular portal. The sutures were pulled subcutaneously and a knot was tightened and tied.<sup>18</sup>

Clinical evaluations were performed preoperatively, at 6 weeks, at 6 months, and 1 year. All patients were evaluated using the AOFAS score, K-P score, and VAS. Stress radiographs were taken before the operation and at the one year final follow up. The AOFAS score, K-P score, and VAS (Table 4) improved in both groups and there was no significant difference between the two.<sup>18</sup>

The mean VAS scores for the open group were 4.4 at pre-op, 2.2 at 6 weeks, 1.1 at 6 months, and 2.0 at 12 months. The mean VAS scores for the arthroscopic group was 5.2 at pre-op, 1.9 at 6 weeks, 1.5 at 6 months, and 1.7 at 12 months. The mean AOFAS score for the open group was 69.9 preop, 68.6 at 6 weeks, 91.3 at 6 months, and 89.2 at 12 months. The mean AOFAS score for the arthroscopic group was 67.5 at preop, 71.4 at 6 weeks, 89.7 at 6 months, and

90.3 at 12 months. The K-P score for the open group was 48.6 preop, 40.6 at 6 weeks, 78.0 at 6 months, and 73.5 for 12 months. The K-P score for the arthroscopic group was 45 preop, 43.2 at 6 weeks, 75.8 at 6 months, and 76.2 at 12 months. Also, radiographic evaluation of mean anterior talar translation and mean talar tilt showed no significant difference between the two groups.<sup>18</sup>

#### *Arthroscopic Brostrom using an Internal Brace*

The retrospective study conducted by Yoo et al. aimed to assess the efficacy of utilizing an internal brace in conjunction with the arthroscopic Brostrom procedure compared to the procedure without an internal brace utilization. Of the 85 patients that took part, 22 of those patients were placed in the internal brace group, while the remaining 63 patients did not have the additional internal brace.<sup>19</sup>

Ankle joint arthroscopy using classic anteromedial and anterolateral portals was performed in both groups. All intra-articular pathology found was treated prior to continuing with lateral ankle stabilization. A 2-suture anchor system was used: the first anchor being placed at the distal-anterior fibula with the second anchor securing the suture tape (internal brace) to the talus at the point of insertion of the original ATFL. The foot was then held in relative plantarflexion during sealing of the suture tape to ensure that tension between the anchors was adequate while preventing over-

tightening of the internal brace.<sup>19</sup> The internal brace serves as an augmentation, rather than an artificial ligament replacement, to help strengthen plantarflexion and inversion motions of the ankle joint. Patients in the group without internal brace fixation underwent an identical arthroscopic procedure arthroscopically up to, but not including, internal brace placement.

Patients in both groups had AOFAS scores measured both pre-operatively and post-operatively. For the internal brace group, the mean AOFAS score was  $65.8 \pm 21.8$  pre-operatively. The mean score climbed to  $95.9 \pm 20.2$  at 6 weeks,  $96.9 \pm 19$  at 12 weeks, and  $98.0 \pm 16.8$  at 24 weeks. The group without the internal brace had a mean AOFAS score of  $66.7 \pm 15.0$  pre-operatively. Remaining scores were  $72.5 \pm 13.0$  at 6 weeks,  $92.0 \pm 7.6$  at 12 weeks, and  $96.5 \pm 5.4$  at 24 weeks (Table 4).<sup>19</sup>

Interestingly, the pre-operative and post-operative AOFAS scores for both groups demonstrated no significant difference ( $p=0.375$ ). On the other hand, the AOFAS score between the two groups specifically at 6 weeks and 12 weeks showed a significant difference (where the internal brace had a higher AOFAS). The internal brace procedure allowed progressive weight bearing after 2 weeks in a short leg cast, followed by the use of solely an ankle brace at 4 weeks. Physical therapy began at 6 weeks, and return to sports at 3 months. Most importantly, the rate of returning to

sports between the two groups was significantly shorter for the internal brace group ( $p<0.001$ ).<sup>19</sup>

#### *Arthroscopic Brostrom technique using Bone Tunnels*

Lui et al. describes a modified arthroscopic Brostrom procedure using bone tunnels. Following examination and treatment of osteochondral lesions, debridement of the fibular insertion of the anterolateral capsule was performed while preserving the ATFL. Two No. 0 Fiberwire suture loops were then passed through the anterolateral capsule and tightened to create stability. Next, guided by arthroscopy, two 2.5 mm bone tunnels were created 1 cm apart at the lateral malleolus followed by insertion of 2.4 mm femoral eye-loop guide wires with sutures passed through. Holding the foot in an everted position and the ankle in a neutral/dorsiflexed position, the dorsal sutures were paired with the plantar sutures, tightened, and tied. Repair of the anterolateral capsule and the ATFL was then performed.<sup>20</sup> While providing solely qualitative clinical and intra-operative findings, the study offers valuable insight for bone tunnel arthroscopic modification for future consideration.

#### *Arthroscopic repair using suture anchors in a clinical setting*

Sorensen et al. described a 2-suture anchor technique. The method involves stripping of the anterior portion of the distal fibula to provide



<b>Cottom et al (cadaveric)</b>		
<b>Group (number of specimens)</b>	<b>Maximum Load (N)</b>	<b>Stiffness (N/mm)</b>
<b>1 (12)</b>	156.43 ± 30.39	12.10 ± 5.43
<b>2 (12)</b>	206.62 ± 55.62	13.40 ± 7.98
<b>3 (12)</b>	246.82 ± 82.37	12.55 ± 4.00

**Table 2. Results from Cottom et al (cadaveric study)**



<b>Lee et al (cadaveric)</b>			
<b>Test Group</b>	<b>Torque to failure (Nm)</b>	<b>Degree to failure (degrees)</b>	<b>Avg Working Construct Stiffness (Nm/degree)</b>
Open modified Brostrom	19.9 ± 8.9	46.8 ± 9.9	43.7 ± 21
Arthroscopic Brostrom (with suture anchor)	23.3 ± 12.1	46.7 ± 7.6	48.7 ± 26.8

**Table 3. Results from Lee et al (cadaveric study)**

<b>Cottom et al (non-cadaveric)</b>					
<b>Group</b>	<b>Mean time to full weight-bearing (days)</b>	<b>Mean time to begin physical therapy (days)</b>	<b>AOFAS (pre-op → post-op)</b>	<b>Karlsson-Peterson score (post-op)</b>	<b>VAS (pre-op → post-op)</b>
Arthroscopic repair with double row 3-suture anchor construct	14.4 (Range = 12 to 16)	21.6 (Range = 18 to 23)	48.7 → 95.4	87	8.0 → 0.6
<b>Yoo et al (non-cadaveric)</b>					
<b>Group</b>	<b>AOFAS (pre-op)</b>	<b>AOFAS (6 weeks)</b>	<b>AOFAS (12 weeks)</b>	<b>AOFAS (24 weeks)</b>	
Repair with internal brace (n = 22)	65.8 ± 21.8	95.9 ± 20.2	96.9 ± 19	98.0 ± 16.8	
Repair without internal brace (n = 63)	66.7 ± 15.0	72.5 ± 13.0	92.0 ± 7.6	96.5 ± 5.4	
<b>Yeo et al (non-cadaveric)</b>					
<b>Group</b>	<b>AOFAS</b>		<b>Karlsson-Peterson score</b>		<b>VAS score</b>
Open procedure	pre-op = 69.9		pre-op = 48.6		pre-op = 4.4
	6 weeks = 68.6		6 weeks = 40.6		6 weeks = 2.2
	6 months = 91.3		6 months = 78.0		6 months = 1.1
	12 months = 89.2		12 months = 73.5		12 months = 2.0
Arthroscopic procedure	pre-op = 67.5		pre-op = 45		pre-op = 5.2
	6 weeks = 71.4		6 weeks = 43.2		6 weeks = 1.9
	6 months = 89.7		6 months = 75.8		6 months = 1.5
	12 months = 90.3		12 months = 76.2		12 months = 1.7

**Table 4. Results from Cottom et al. (prospective non-cadaveric), Yoo et al. (non-cadaveric) and Yeo et al. (non-cadaveric)**

an anchor placement and to prevent capsule and ligamentous fibrosis post-operatively. The first suture anchor is placed into the anterior portion of the distal fibula right below the distal tibial plafond. The second suture anchor is placed approximately 1 cm distal to the first anchor. It is critical to space the anchors to decrease the risk of stress risers.<sup>21</sup>

For an inside-out technique, a sharp-tipped suture passer is used to pass the four free suture ends through the lateral capsule. To provide stability to the CFL distally, the suture ends are passed through to the inferior anchor. Consequent strengthening of the ATFL and inferior extensor retinaculum, was achieved through attachment of the superior and inferior suture ends. Next, a skin incision is made between the 2 sets of sutures and an arthroscopic probe used to pull the four sutures limbs through the incision. The sutures limbs are tied with their respective pair with the foot held in dorsiflexion and eversion.<sup>21</sup>

This technique allows a patient to be full weight-bearing in a CAM walker just one week post op with a splint applied at night. They would be allowed to dorsiflex and plantarflex at this time as well. By week four to six post-op, patients can begin full weight-bearing with a sports brace. After six weeks, non-ballistic physical activity are allowed, and at month three ballistic activities are allowed.<sup>21</sup>

## DISCUSSION

Cottom et al. described a knotless approach that may decrease the complication rate following arthroscopic Brostrom repair. This was the first study to incorporate LabralTape™, which is primarily used to repair glenohumeral instability, to repair lateral ankle instability. LabralTape™ has lower incidence of tissue tear-through compared to other suture types, but may have been weaker than the Group 3 (double-row 3 anchor construct) construct due to the lack of a tied knot. This construct was based off of a previous study performed by Giza et al. In Giza et al.'s original paper, he used a No. 0 suture and found no statistical difference between the strength of the Brostrom versus suture anchor repair.<sup>22</sup> However, Cottom utilized a thicker gauge No. 1 suture, which decreased the standard deviation of his data bringing his results to statistical significance.

The authors expected the knotless technique would yield the strongest results, but attribute the lack of significant difference in strength to the unfamiliar feel of the suture material used as well as the unconventional lack of a knot being tied through the ATFL. The high variability in stiffness for this group (Group 2) may be due to the use of unfamiliar suture material. Overall, the double-row 3 anchor technique using a No. 1 suture could withstand the highest load<sup>15</sup>, however it is quite possible

that increased operator proficiency using LabralTape™ may potentially yield different results.

Cottom later implemented his Group 3 construct in a clinical setting noting that there was a much earlier return to normal weight-bearing activities. Within approximately 2 weeks, the patients were full weight bearing with the aid of supportive footwear. This technique allowed faster return to physical therapy and faster subsequent return to daily activities. The double-row construct yielded higher AOFAS, and K-P scores with lower VAS than Yeo's single suture technique. Although return to sporting activities was not reported in this clinical study, the author reported a minimal occurrence of complications. Only 7% of patients developed superficial infection, which were later resolved with oral antibiotics and wound care.<sup>17</sup>

The most critical finding from the second cadaveric study (Lee et al.) was the comparable strength between the arthroscopic and open modified Brostrom operation for chronic lateral ankle instability. There was no significant difference in strength between the two techniques. The amount of torque to failure, degrees of failure, and working construct stiffness were nearly identical between the two techniques.<sup>16</sup> This supports the notion that arthroscopic technique is on par with traditional open procedures.

Yoo et al. examined the clinical results of an arthroscopic modified Brostrom

operation with an internal brace versus an arthroscopic modified Brostrom operation without an internal brace. Addition of the internal brace allowed progressive weight bearing after 2 weeks in a short leg cast before an external brace applied at 4 weeks. Physical therapy began at 6 weeks, and return to sports without limitations began at 3 months for 81.8% of the patients that received the internal brace. Of the patients that did not receive internal brace augmentation, just 27.0% were able to return to sports activities at the 3 month mark. This supports the use of an internal brace particularly for athletes. Furthermore, there was a comparable AOFAS to Cottom et al.'s double row suture anchor technique. However, the internal brace group took 6 weeks to begin physical therapy, while Cottom et al.'s patients took approximately 3 weeks. The use of bioabsorbable suture anchors may be the reason for the rapid recovery time. If comparing time to return to sports between open and arthroscopic procedures, arthroscopic procedures still boast a more rapid return to sports. Russo et al.'s long-term study found that patients could resume running at 3 months post-op with return to sports at 4 months.<sup>23</sup>

Yeo et al. also found a decreased time to return to running and sporting activities. At 8 weeks post-op, patients could return to straight running. Sporting activities and cutting drills began at 12 weeks post-op, followed shortly by full return to sports without limitations. Complications were noted



in both groups. In the arthroscopic group two patients had superficial peroneal injuries, and one had sural nerve injury. These were all resolved within 3 months post op. Of the two patients who had knot pain, one improved on their own and one underwent knot removal at 6 months relieving all symptoms. In the open group, two patients had superficial peroneal nerve injuries and one had a suture abscess, all of which improved by 6 months. In the all-inside group, complication rates were 20% compared with 13% of the modified open Brostrom group, resulting in the only study that complication rate were minimally higher in the arthroscopic group. There was no significant difference in the AOFAS scores, K-P scores, or VAS, indicating that the all-inside technique was at least as viable as the open technique. Upon clinical and radiologic examination, no differences were found between the two groups after 1 year post-op.<sup>18</sup>

Lui explored the bone tunnel approach as an alternative to suture anchors which have potential complications including implant dislodgement, fracture of the lateral malleolus, or impingement of the syndesmosis or peroneal tendons.<sup>20</sup> The rate of iatrogenic fracture of the distal fibula (lateral malleolus) is decreased with the use of bone tunnels given the smaller 2.5-diameter of the bone tunnels compared with 3.4mm drill holes necessary for most suture anchors. Despite the decrease in risk of injury to the extensor tendons and superficial peroneal nerve (which is a

risk in most open Brostrom procedures), there may be the increased risk of damaging the sural nerve. Passing the guidewires through the skin just lateral to the Achilles tendon should be noted because it reduces this risk. One downfall of this procedure is that it does not address the CFL injury, but studies indicate this is not essential for long-term stability of the lateral ankle unless subtalar instability is present.<sup>12,20</sup> Open procedures do not generally provide the opportunity to observe the CFL without significant tissue dissection. Instead, subtalar arthroscopy is required to visualize the CFL and any concomitant injury associated with lateral ankle pathology.<sup>24</sup> This offers another advantage to arthroscopic Brostrom over the open Brostrom.

Although Sorenson et al. stated that full weight-bearing with a CAM walker is possible at 1 week post-op, the article does not provide data from controlled trials. Instead the described post-op course is based on the author's own clinical experience. This limits the validity and universality of his results. However, Cottom et al. utilized a well-designed prospective study showing the rapid return to full-weight bearing activities with concomitant AOFAS, VAS, and K-P scores. The difference between the pre-op to post-op scores for each measurement showed the greatest level of improvement when compared with the scores from other studies. Ultimately, the construct used by

Cottom et al. boasts an incredible rate of return to daily activities.<sup>17</sup>

## CONCLUSION

It is clinically imperative to surgically correct lateral ankle instability after conservative therapy fails prior to the development irreversibly diminished joint function. The open modified Brostrom-Gould procedure is currently the surgical gold standard. The idea of performing the modified Brostrom-Gould procedure arthroscopically is evolving and shows similar positive outcomes as the open procedure.<sup>18</sup> Although a slight learning curve exists due to novelty of modifications, arthroscopy provides comparable rates of complications than an all-open technique. While complications still exist with arthroscopy, they may differ from those of the all-open technique, and are generally minimal. The major advantage of arthroscopy lies in the concomitant identification and removal of osteochondral lesions found within the joint, rather than performing an arthroscopy followed by open lateral ankle repair.<sup>24</sup> Given the minimally invasive nature of arthroscopic procedures, there are generally better cosmetic results and less soft tissue damage as well.<sup>20</sup> Lee et al. and Yeo et al. both reported equal or better outcomes using the arthroscopic technique compared to the open technique. Lui's bone tunnel approach minimizes the already rare incidence of iatrogenic fractures, and

may be an alternative for patients with generally smaller lateral malleoli.

Ultimately, the goal of any clinician and patient is to achieve improved lateral ankle stability and a quicker return to full weight-bearing, both of which can be obtained via ankle arthroscopy. Among the arthroscopic procedures explored in this review, Cottom et al.'s double row, 3-suture anchor construct proved to have the most rapid return to full-weight bearing activities. However, it is a purely prospective study without a control group. It would prove useful to provide additional data regarding the post-op course of those subjects. Long term results could further prove the positive outcome of this novel technique. The originality of these arthroscopic approaches lends to the limited data regarding long-term post-op course.

There remains a scarcity of randomized controlled trials for studying fully arthroscopic Brostrom procedures. The novelty of arthroscopic modifications is likely the reason for the lack of such controlled studies. Comparing each technique side-by-side using a uniform method of measurement in a clinical setting is prudent. The present study's attempt to compare was limited by the variability of post-op evaluations. Regardless, current evidence suggests modified arthroscopic Brostrom procedures may eventually evolve into the gold standard for lateral ankle ligament repair.

## AUTHORS' CONTRIBUTIONS

All authors participated equally in the conception of the research topic, literature review, and extraction of data. All authors agreed upon the final submission.

## STATEMENT OF COMPETING INTERESTS

The authors declare that they have no competing interests.

## REFERENCES

1. Sorensen MD, Baca J, Arbuckle K: Arthroscopic Repair of Ankle Instability. *Clinics in podiatric medicine and surgery* 33: 553, 2016.
2. Dubin JC, Dubin RA, Comeau D, McClelland RI, Ferrel E: Lateral and syndesmotomic ankle sprain injuries: a narrative literature review. *Journal of Chiropractic Medicine* 10: 204, 2011.
3. Garrick JG: The frequency of injury, mechanism of injury, and epidemiology of ankle sprains. *The American Journal of Sports Medicine* 5: 241, 1977.
4. Miller A, Raikin SM. Lateral ankle instability. *Operative Techniques in Sports Medicine*. 2014;22(4):282.
5. Carter SR, Stapp MD: ANKLE INSTABILITY The Broström-Gould Procedure.
6. Baumhauer JF, O'Brien T: Surgical considerations in the treatment of ankle instability. *Journal of Athletic Training* 37: 458, 2002.
7. Karlsson J, Bergsten T, Lansinger O, Peterson L: Lateral instability of the ankle treated by the Evans procedure. A long-term clinical and radiological follow-up. *The Journal of bone and joint surgery. British volume* 70: 476, 1988.
8. Broström L: Sprained ankles. VI. Surgical treatment of "chronic" ligament ruptures. *Acta chirurgica Scandinavica* 132: 551, 1966.
9. Gould N, Seligson D, Gassman J: Early and late repair of lateral ligament of the ankle. *Foot & ankle* 1: 84, 1980.
10. Manaka T, Ito Y, Matsumoto I, Takaoka K, Nakamura H: Functional Recovery Period after Arthroscopic Rotator Cuff Repair: Is it Predictable Before Surgery?. *Clin Orthop Relat Res* 469: 1660, 2011.
11. Zhang AL, Montgomery SR, Ngo SS, Hame SL, Wang JC, Gamradt SC: Arthroscopic versus open shoulder stabilization: current practice patterns in the United States. *Arthroscopy : the journal of arthroscopic & related surgery : official publication of the Arthroscopy Association of North America and the International Arthroscopy Association* 30: 436, 2014.
12. Acevedo JI, Mangone P: Ankle instability and arthroscopic lateral ligament repair. *Foot and ankle clinics* 20: 59, 2015.
13. Pihl K, Roos EM, Nissen N, Jørgensen U, Schjerving J, Thorlund JB: Over-optimistic patient expectations of recovery and leisure activities after arthroscopic meniscus surgery. *Acta Orthopaedica* 87: 615, 2016.
14. Drakos M, Behrens SB, Mulcahey MK, Paller D, Hoffman E, DiGiovanni CW: Proximity of arthroscopic ankle stabilization procedures to surrounding structures: an anatomic study. *Arthroscopy : the journal of arthroscopic & related surgery : official publication of the Arthroscopy Association of North America and the International Arthroscopy Association* 29: 1089, 2013.
15. Cottom JM, Baker JS, Richardson PE, Maker JM: A Biomechanical Comparison of 3 Different

- Arthroscopic Lateral Ankle Stabilization Techniques in 36 Cadaveric Ankles. *The Journal of Foot and Ankle Surgery* 55: 1229, 2016.
16. Lee K, Kim E, Kim Y, Ryu J, Rhyu I, Lee Y: All-inside arthroscopic modified Broström operation for chronic ankle instability: a biomechanical study. *Knee Surg Sports Traumatol Arthrosc* 24: 1096, 2016.
  17. Cottom JM, Rigby RB: The "all inside" arthroscopic Broström procedure: a prospective study of 40 consecutive patients. *The Journal of foot and ankle surgery : official publication of the American College of Foot and Ankle Surgeons* 52: 568, 2013.
  18. Yeo ED, Lee K, Sung I, Lee SG, Lee YK: Comparison of All-Inside Arthroscopic and Open Techniques for the Modified Broström Procedure for Ankle Instability. *Foot & Ankle International* 37: 1037, 2016.
  19. Yoo J, Yang E: Clinical results of an arthroscopic modified Brostrom operation with and without an internal brace. *J Orthopaed Traumatol* 17: 353, 2016.
  20. Lui TH: Modified Arthroscopic Brostrom Procedure With Bone Tunnels. *Arthroscopy Techniques* 5, 2016.
  21. Sorensen MD, Baca J, Arbuckle K: Arthroscopic Repair of Ankle Instability. *Clinics in podiatric medicine and surgery* 33: 553, 2016.
  22. Giza E, Whitlow SR, Williams BT, Acevedo JI, Mangone PG, Haytmanek CT, Curry EE, Turnbull TL, LaPrade RF, Wijdicks CA, Clanton TO: Biomechanical Analysis of an Arthroscopic Broström Ankle Ligament Repair and a Suture Anchor–Augmented Repair. *Foot & Ankle International* 36: 836, 2015.
  23. Russo A, Giacchè P, Marcantoni E, Arrighi A, Molfetta L. Treatment of chronic lateral ankle instability using the broström-gould procedure in athletes: Long-term results. *Joints*. 2016;4(2):94.
  24. Ferkel RD, Chams RN. Chronic lateral instability: Arthroscopic findings and long-term results. *Foot & Ankle International*. 2007;28(1): 24-31.

# Treatment of Cystic Osteochondral Lesion of the Talus: A Literature Review

*HyunJi Boo, BS, Michelle Diaz, BS, & Hussain Hussain, BS*

## Abstract

### Introduction

This literature review aims to give an overview of the different methods available for the treatment of talar bone cysts. The methods of treatment will be evaluated for effectiveness in pain reduction. The techniques explored include: arthroscopic debridement and microfracture with or without adjunct therapies, open debridement and microfracture with or without adjuncts, and percutaneous injection of bone cement.

### Study Design

Systematic Review of Literature

### Methods

The PubMed search query "Bone Cysts/complications"[MeSH] OR "Bone Cysts/surgery"[MeSH] OR "Bone Cysts/therapy"[MeSH] AND "Talus"[MeSH] was performed with inclusion criteria of human subjects, English language, and publication date between 2006/01/01 and 2016/12/31. Exclusion criteria included: educational articles without patient information, ambiguous surgical approach, and cysts with clearly non-osteochondral defect etiology.

### Results

18 articles were found with the initial search query and inclusion criteria. The application of exclusion criteria narrowed down the results to the 13 articles reviewed in this paper.

### Discussion and Conclusions

Seven studies concerning the arthroscopic approach to cystic talar lesions all reported good pain reduction. The interventions involved various combinations of arthroscopic debridement, bone marrow stimulation, autograft, demineralized bone matrix gel, and stromal vascular fraction containing mesenchymal stem cells. Of the four studies describing open surgical approaches, the three involving some combination of medial malleolar osteotomy, debridement, bone marrow stimulation, autograft, and metal implant reported good pain reduction. One study of osteotomy, debridement, and biosynthetic scaffold reported complete treatment failure. Two studies approached the talar bone cyst with percutaneous injection of bone cement and reported good pain reduction. Generally, both established and more novel approaches reported good outcomes in the treatment of talar bone cysts. More research in this field is required to establish clear clinical recommendations.

### Key Words

Osteochondral defect, bone cyst, talar lesions, complications, surgery, therapy, talus

*Level of Evidence: 4*

## INTRODUCTION

An osteochondral lesion of the talus (OLT) is described as a defect involving the cartilage and underlying subchondral bone.<sup>1,2</sup> Other terms used to describe this condition include osteochondral defect, osteochondral fracture, osteochondritis dissecans, transchondral fracture, flake fracture, and intra-articular fracture.<sup>3</sup> Traumatic ankle injury is widely accepted as the most common etiologic factor of an OLT.<sup>1,2</sup> Other possible, non-traumatic, etiologic factors include ischemia and necrosis, and genetics.<sup>9</sup> Osteochondral defects of the ankle are most commonly seen in men between the ages of 20 and 30.<sup>8</sup>

Occasionally, in addition to an OLT, there can be formation of a subchondral bone cyst. The pathogenesis of cystic OLTs is not completely understood. Some lesions remain asymptomatic while others cause deep ankle pain upon weight bearing (WB).<sup>1</sup> Several authors have theorized the pathogenesis of these subchondral bone cysts. One theory states that focal ischemia and necrosis leads to mucoid degeneration of intramedullary connective tissue thus causing the formation of a cyst.<sup>7</sup> However, the prevailing theory indicates that there is an extrusion of synovial fluid or herniation of synovial membrane into the talus through the articular lesion, or defect.<sup>1,7</sup>

The combination of liquid and solid matrix components allows articular cartilage to deform and withstand compressive stress. The fluid contained in cartilage is a dialysate of synovial fluid. The matrix consists of collagen and hydrophilic proteoglycan molecules that maintain the water content of cartilage at 75% by weight. When one area of a joint is load bearing, fluid flows to the adjacent unloaded cartilage. The intact subchondral plate prevents the flow of liquid into subchondral bone.<sup>2</sup>

However, when microfractures or openings occur in the subchondral plate, compression on load bearing presses the water from cartilage into subchondral bone. The subsequent high fluid pressure inside bone interferes with normal perfusion and causes osteonecrosis, bone resorption, and bone remodeling around the defect, creating a sclerotic cystic wall. A smaller subchondral bone defect would increase the pressure of fluid flow. Van Dijk et al. also propose that damaged cartilage may be involved in a valve-like mechanism.<sup>2</sup> When the tibial and talar cartilages are in contact during WB, the opposing pressures are theoretically identical. The damaged talar cartilage provides the pathway of least resistance, allowing cartilage fluid to be pushed into the subchondral bone on compression but not back out. Each instance of load bearing pushes more water into the defect, causing the development and enlargement of the cystic lesion.<sup>2</sup>

Scranton refers to the work of researchers Berndt and Harty who, based on radiographic imaging, developed a four-stage classification system to describe OLTs called “transchondral fracture of the talus.”<sup>5</sup>

Subsequent authors, including Anderson and colleagues and Hepple et al., adapted the Berndt and Harty classification (Stages I-IV) for OLTs to include cyst formation.<sup>1, 4, 14, 18</sup> The new classification system, developed through CT or MRI, added a stage IIa, which included all lesions with cyst formation.<sup>1,14,18</sup> Other authors, including Scranton and McDermott utilize a stage V to describe lesions that are formed due to forced synovial fluid intrusion through a defect not a transchondral fracture.<sup>5</sup> However, Raikin noted that the modified classification system did not account for cystic OLTs that exceeded 3 cm<sup>3</sup> in volume and thus proposed that a stage VI be added to the modified Berndt and Harty classification.<sup>6</sup>

Depending on the size of the cyst, the physician can explore conservative or surgical treatment options. Nonoperative treatment is usually indicated for medial talar lesions that fall under stage I, stage II, or stage III of the Berndt and Harty classification system.<sup>11</sup> It is also indicated for patients with minimal to no ankle pain, and lesions with intact cartilage on arthroscopy.<sup>11</sup> Conservative treatment options include rest, ice, limited WB, and orthotics.<sup>11</sup> Surgical treatment is usually indicated only in symptomatic lesions that fail conservative treatment.<sup>10</sup> While

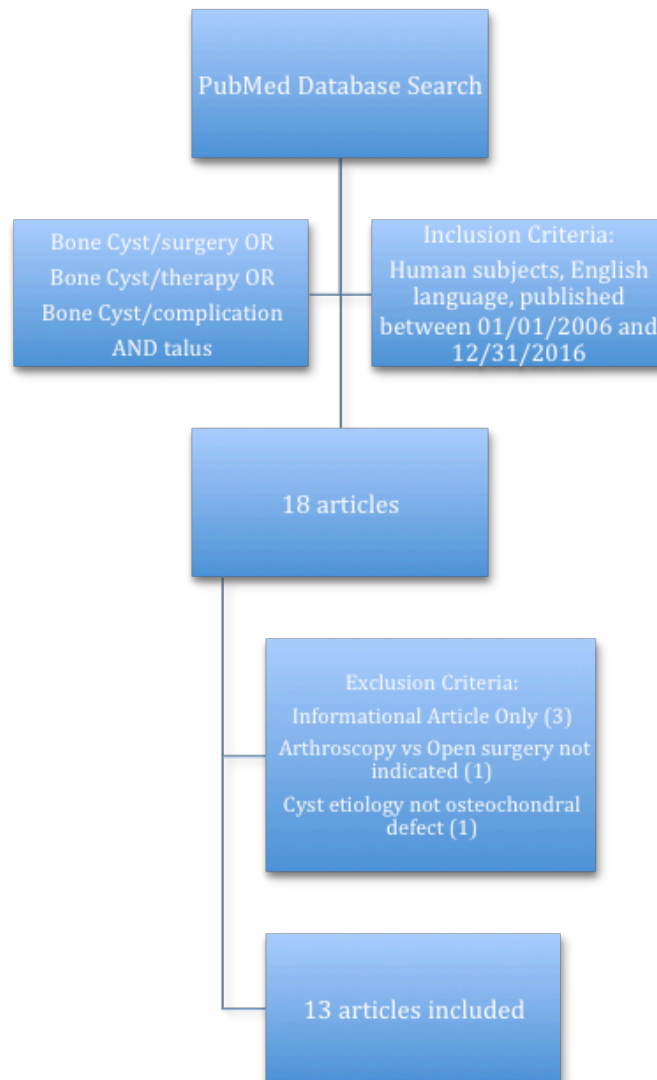
various treatment methods have been explored, a conclusive, and optimal treatment for an OLT with a subchondral cyst has yet to be defined.

7

This article aims to provide an overview of various surgical treatment options for osteochondral defects of the talus with a concomitant cyst. In addition, based on the pain reduction outcomes, we hope to suggest the most optimal treatment for an OLT with a subchondral cyst. The treatment options highlighted are: arthroscopy, open surgery, and percutaneous injection.

## METHODS

A search in PubMed with the query “Bone Cysts/surgery” [MeSH] OR “Bone Cysts/therapy” [MeSH] OR “Bone Cysts/complication” [MeSH] AND “Talus” [MeSH], yielded a return of eighteen articles. The authors used the inclusion criteria of studies involving human subjects and studies published in English with publishing dates restricted by the parameters (2006/01/01 [PDAT] : 2016/12/31 [PDAT]). Of these articles, five were excluded because they were informational, did not indicate if the approach was arthroscopic or open, or did not indicate cystic etiology. As seen in Figure 1, applying the exclusion criteria left the thirteen articles included in this literature review.



**Figure 1:** Article Search and Exclusion Criteria

## RESULTS

### *ARTHROSCOPIC SURGERY*

The results of the arthroscopic surgical approaches are listed in Table 1. The case series by Han et al. and the cohort study by Lee et al. reported on the efficacy of arthroscopic debridement with bone marrow stimulation only (microfracture or abrasion arthroplasty) on osteochondral lesions of the talus (OLT) with or without associated

subchondral cysts. Both studies involve patients with pain history but no surgical history. The Han et al. study shows improvements in the American Association of Foot and Ankle Surgeons hindfoot (AOFAS) score, used to measure pain, function and alignment, in both cystic and noncystic OLT groups.<sup>12</sup> The Lee et al. study showed improvements in both AOFAS score and visual analog scale for pain (VAS) in both groups.<sup>7</sup> Neither study shows significant differences in clinical outcomes between cystic and noncystic OLTs.



The case series and reports by Ogut et al., and Lui et al. reported on the efficacy of arthroscopic debridement with bone marrow stimulation and autograft on cystic OLTs. One patient in the Ogut study was treated with hydroxyapatite rather than autologous bone graft. The patients in the Ogut study demonstrated improvement in AOFAS score and alleviation of moderate pain. One patient reported mild pain with prolonged walking.<sup>13</sup> In the 2013 case report and 2014 case series, Lui et al. reported subsidence of deep ankle pain symptoms in all nine patients after arthroscopic debridement, microfracture and autograft.<sup>14, 15</sup>

The case report by Dawe et al. described the results of the treatment of a large cystic lesion with arthroscopic debridement, microfracture and Grafton gel, a demineralized bone matrix. The patient presented with a one-month history of worsening ankle pain. At last follow-up the patient reported to be pain free.<sup>16</sup> The cohort study by Kim et al. compared the effect of adding stromal vascular fraction (SVF) containing adipose-derived mesenchymal stem cells (MSC) to the standard arthroscopic treatment of debridement and microfracture in OLTs with and without associated cysts. All patients had pain history, but

Author	Ankles (#)	Age (avg.)	Clinical pre-op pain	Tx history	Cyst size or class	Adjunct therapy	Post-op management	Last follow-up pain metrics
Han et al. (2006)	20/38	37	6 m pain	3 m nonsurgical	<15mm	none	OLT <1.5cm <sup>2</sup> : WB to tolerance OLT >1.5cm <sup>2</sup> : 3 w partial WB 1 w: PT 3 m: high impact sports	30 m AOFAS: Increased in both cystic and non-cystic groups. No significant difference between groups. Two patients with cysts reported pain and no functional improvement
Lee et al. (2015)	45/102	34.7	50.6 m pain	nonsurgical	unknown	none	Compressive dressing, posterior plaster splint for 1 w Tolerable WB with walking boot for 2 w Full WB, active ankle ROM and strengthening exercises at 2 w Non-walking boot at 8 w Sport activities at 4-6 m	48.3 m AOFAS: Significant increase in both cystic and non-cystic group VAS: Significant improvement in both cystic and non-cystic group
Ogut et al. (2011)	6	34	pain	nonsurgical	unknown	autograft (hydroxyapatite in 1)	unknown	27 m AOFAS: Significantly increased Pain: All patients free from moderate pain. One patient with mild pain during prolonged walking.
Lui (2013)	1	54	1 y deep ankle pain	nonsurgical	3x2.5x3cm = 22.5cm <sup>3</sup>	autograft	Short leg cast NWB for 8 w	28 m Deep pain symptoms subsided
Lui (2014)	8	53	Deep ankle pain	unknown	large	autograft	Short leg cast NWB for 8 w	13 m All preoperative symptoms subsided, cyst healed.
Dawe et al. (2014)	1	28	1 m worsening ankle pain	unknown	large	demineralized bone matrix gel (Grafton gel)	Below-knee plaster backslab NWB for 6 w	3.5 y Pain free
Kim et al. (2014)	19/50	46	22.2 w pain	>3 m nonsurgical	unknown	mesenchymal stem cells (MSC)	Short leg splint NWB for 2 w Passive, active ankle ROM at 2 w Sports, high impact activity at 3 w	21.9 m AOFAS: MSC group had significantly larger improvement VAS: MSC group had significantly larger improvement

d = day, w = week, m = month, y = year, PT = physical therapy, ROM = range of motion, WB = weight bearing, NWB = non-weight bearing

**Table 1:** Treatment- Arthroscopy with Bone Marrow Stimulation

no previous surgical intervention. At final follow-up the treatment group with adjunctive MSC reported a significantly larger improvement in both AOFAS and VAS parameters compared to the standard treatment group. Within each treatment group, the cystic OLTs were separated from noncystic only in regards to the magnetic resonance observation of cartilage repair tissue (MOCART) score. In the standard treatment group, the cystic OLTs had significantly worse MOCART scores than noncystic. However, in the MSC treatment group, no such outcome difference was found in the MOCART scores.<sup>17</sup>

### OPEN SURGERY

The results of the open surgical approaches are listed in Table 2. Scranton et al. reported on 50 patients who underwent open surgery for debridement and autograft for stage V

cystic OLTs between 8-20mm. A medial malleolar osteotomy was performed if necessary to access the lesion. Most patients presented with a pain history longer than one year. The treatment history was a mix of nonsurgical, arthroscopic and open interventions. At last follow-up, 45 patients reported satisfaction with pain reduction.<sup>18</sup> In a case series of 17 patients, Hu et al. describe success in the treatment of cystic lesions with debridement, bone marrow stimulation, and autograft. Arthrotomy or medial malleolar osteotomy was performed to access the talar lesion. The patients presented with an average cyst size of 13.5 mm, persistent ankle pain, and mixed nonsurgical and arthroscopic treatment history. The last follow-up exam, at an average of 32.6 months postoperative, showed significant improvements in both AOFAS score and VAS.<sup>21</sup> Garcia et al. reported on four patients in the military receiving

Author	Ankles (#)	Age (avg.)	Clinical pre-op pain	Tx history	Cyst size or class	Therapy	Post-op management	Last follow-up pain metrics
Scranton et al. (2006)	50	36	> 1 y pain: 40 patients <1 y pain: 10 patients	> 6 m nonsurgical, open, and arthroscopic	8-20 mm, stage V	medial malleolar osteotomy*, debridement, autograft	Bootwalker immobilization NWB for 3 w No bootwalker NWB for 3 w Bootwalker WB for 3 w PT at 9 w	36 m 45 patients reported satisfaction with pain reduction
Garcia et al. (2010)	1/4	27.75	unknown	12 m nonsurgical, arthroscopic (33.6 m prior)	Large, stage V	medial malleolar osteotomy, debridement, biosynthetic scaffold (TRUFIT plug)	Plaster splint immobilization for 2 w Short leg cast for 4 w PT at 6 w NWB for 8-12 w	30.5 m All patients had remaining or worsening symptoms requiring discharge or additional interventions
Van Bergen et al. (2011)	1	20	Deep ankle pain	arthroscopic (14 m prior)	17x8x8mm = 1.09cm <sup>3</sup>	medial malleolar osteotomy, debridement, implant (HemiCAP)	Plaster cast for 1 w Functional brace for 5 w PT w/ advance to WB at 4 w	2 y AOFAS: Improved from 74 to 90 Numeric pain rating scales: almost no pain at rest, walking, running
Hu et al. (2013)	17	37.3	Persistent ankle pain	nonsurgical (15) arthroscopic (1)	Average, 13.5mm	arthrotomy or medial malleolar osteotomy, debridement, bone marrow stimulation, autograft	Cast immobilization for 2 w (osteotomy patients) Passive ROM at 3 d NWB for 6 w Partial WB at 7 w Full WB at 8 w	32.6 m AOFAS: Improved significantly VAS: Improved significantly

d = day, w = week, m = month, y = year, PT = physical therapy, ROM = range of motion, WB = weight bearing, NWB = non weight bearing, \* = if necessary

**Table 2:** Treatment - Open Surgery

open debridement and TruFit biosynthetic scaffold for OLTs. One patient had a stage V cystic lesion and also received a medial malleolar osteotomy. Patients had a mixed history of nonsurgical and arthroscopic interventions. At final follow-up, all patients had remaining or worsening symptoms requiring discharge or additional interventions.<sup>19</sup> The case report by van Bergen et al. described the outcome of open medial malleolar osteotomy, debridement, and placement of a HemiCAP, a contoured articular inlay implant, on a 1.09cm<sup>3</sup> cystic OLT. Two previous arthroscopic interventions had failed to alleviate deep ankle pain. At last follow-up the patient demonstrated an improved AOFAS score, from a preoperative 74 to a 90. The patient also reported little to no pain at rest, walking, or running on a numeric pain scale.<sup>20</sup>

*PERCUTANEOUS BONE CEMENT INJECTION*

The results of the percutaneous injection approaches are listed in Table 3. The case report by He et al. described the outcome of percutaneous injection of Simplex P, a

polymethyl methacrylate (PMMA), to treat a 1.9cm<sup>3</sup> cystic lesion in a patient presenting with a history of nonsurgical intervention for four years of ankle pain. The preoperative VAS of 7 dropped to 4 at three days postoperative, 2 at 1 month postoperative, 1 at 3 months postoperative, and 0 at 10 months postoperative.<sup>22</sup> Maurel et al. reported on five patients with cystic osteochondral lesions treated with percutaneous injection of JectOS+, a calcium phosphate cement. One patient had a cystic OLT of 8 mm and reported one year of pain and nonsurgical treatment. At final follow-up, the patient was pain free and showed an improved VAS of 8 preoperative to 0.<sup>23</sup>

**DISCUSSION**

*ARTHROSCOPIC*

One reported surgical approach to treating a cystic OLT is arthroscopy with bone marrow stimulation. An arthroscopic procedure allows for debridement, microfracture, and abrasion arthroplasty of the affected lesion area and offers a less invasive approach to graft implantation. Bone

Author	Ankles (#)	Age (avg.)	Clinical pre-op pain	Tx history	Cyst size or class	Type of cement	Post-op management	Last follow-up pain metrics
He et al. (2012)	1	32	4 y pain worsening over 2 m	nonsurgical	1.4x1.7x0.8cm = 1.9cm <sup>3</sup>	Polymethyl-methacrylate (Simplex P)	unknown	10 m VAS: improved from 7 to 0
Maurel et al. (2013)	1/5	38	1 y ankle pain	nonsurgical	8mm	Calcium phosphate (JectOS+)	unknown	8 m VAS: improved from 8 to 0 Pain free at 4 w

w = week, m = month, y = year, VAS = visual analog scale

**Table 3:** Treatment- Percutaneous Bone Cement Injection

marrow stimulation by drilling or microfracture works to disrupt vasculature in the area and promote release of growth factors to develop a new fibrocartilaginous layer in the area of the defect.<sup>8</sup> Arthroscopic debridement and bone marrow stimulation has been shown effective as a sole treatment in some cases, but can be supplemented by adjunctive therapies.<sup>7, 12</sup>

Han et al. included twenty patients with symptomatic Stage V cystic lesions who underwent arthroscopy with curettage and debridement. All patients had attempted at least three months of failed nonsurgical treatment. Small 3mm incisions were used to create anteromedial and anterolateral portals for the arthroscope, using the portal on the side of the talar lesion for removal of cystic material and subsequent debridement. Patients also received microfracture where subchondral bone was intact or abrasion arthroplasty where subchondral bone was not intact.<sup>12</sup> Depending on the size of the cyst, patients were either left WB or partial WB for three weeks after the procedure, with physical therapy beginning at one week and return to sports after three months. At an average follow-up of thirty months, the twenty patients with cystic lesions reported an improved AOFAS score.<sup>12</sup> The study also included eighteen patients with noncystic lesions, who also reported an increase in AOFAS score, but there was no significant difference in improvement between cystic and noncystic groups. Two

cystic patients still reported pain with no functional improvement. Importantly, the authors noted that pre and postoperative radiographic changes in cyst size were not correlated with observed clinical score improvements, postulating that initial cyst size may not predict clinical results.<sup>12</sup>

Lee et al. also examined two groups of patients with OLTs either with or without a cyst. Forty-five patients were included in the cystic OLT group with a reported average of 50.6 months of preoperative pain. Fifty-seven patients were included in the noncystic OLT group with an average of 49.2 months of pain. All patients had lesions smaller than 2cm and underwent arthroscopy with microfracture as a primary surgical treatment after failure of nonsurgical treatments.<sup>7</sup> The procedure was performed with anteromedial, anterolateral, and posterolateral portals used for debridement of lesion area and microfracture in all patients. All ankles were splinted in the neutral position for one week post-procedure with partial WB to tolerance in a boot walker for two weeks, full WB with range of motion exercises beginning after two weeks, and return to sports at four to six months.<sup>7</sup> A significant improvement in AOFAS score was seen in both cystic and noncystic groups at average follow-up times of forty-eight and forty-seven months, respectively. A VAS pain scale was also assessed and found to improve significantly in both groups, but there were no significant differences in

improvements between groups.<sup>7</sup> Both groups included three patients who reported persistent pain and limited activity at final follow-up. This suggests arthroscopic microfracture may be a successful treatment of small to midsize OLTs both with and without cysts.

As mentioned, arthroscopic debridement can be supplemented by adjunctive therapies. One such additional intervention is to fill the cystic defect with an osteochondral autograft implant.<sup>8</sup> In Ogut et al., six ankles with posteriorly localized cystic talar lesions underwent debridement, stimulation with K-wire drilling, and autograft implantation through an arthroscopic approach. All patients had failed previous nonsurgical treatments and complained of pain. They all had a mixed pathology complicated by the presence of either an edematous os trigonum or flexor hallucis longus (FHL) tendinitis.<sup>13</sup> Posteromedial and posterolateral portals were used for arthroscopy, which involved curettage and debridement of the cystic cavity as well as os trigonum excision or adhesion removal from the FHL where appropriate. Five ankles then received an autograft transplant from the posterior superior iliac spine (PSIS), and one ankle was filled with hydroxyapatite.<sup>13</sup> Follow-up at twelve months showed significantly improved AOFAS scores in all patients, and, at an average final follow-up of twenty-seven months, all patients noted no severe or moderate pain, while one patient reported mild

pain with extensive walking.<sup>13</sup> This study highlights the potential of arthroscopy in successfully treating cystic talar lesions and other hindfoot pathologies in one minimally invasive procedure.

Arthroscopy with autograft implantation was the method utilized in two case studies by Lui.<sup>14, 15</sup> In one case, a patient complained of one year of deep ankle pain after walking that persisted after conservative treatments. MRI confirmed a posterior cystic talar lesion, thus posteromedial and posterolateral portals were used for arthroscopy. The articular cartilage in the ankle joint was found intact, and the subchondral bone below the cyst was opened to enhance communication between the joint and the cyst to prevent recurrence.<sup>14</sup> An osteotomy of a portion of the posterolateral talar process was performed along with arthroscopic debridement of cystic debris and bone marrow stimulation with K-wire drilling. An autograft of cancellous bone from the iliac crest was then implanted.<sup>14</sup> The patient was kept NWB in a short leg cast for two weeks with cast removal at eight weeks. Follow-up at twenty-eight months reported the patient had no cyst or pain recurrence.<sup>14</sup> In a case series, Lui performed arthroscopy on eight patients with deep ankle pain after exercise.<sup>15</sup> An anterior approach with anteromedial and anterolateral portals was used in five patients, while a posterior approach with posteromedial and posterolateral portals was used in three patients. In each case, the cysts

were drilled, drained, debrided of debris, stimulated with K-wire, arthroscopic burr and arthroscopic awl, then filled with autologous cancellous bone graft. Again, the subchondral bone below the lesion was opened with an awl in hopes of preventing cyst recurrence and the patients were kept NWB in a short leg cast for eight weeks.<sup>15</sup> At an average follow-up of thirteen months, all patients had no pain symptoms, but some reported mild post-static dyskinesia. Both Lui studies present positive clinical outcomes from arthroscopic talar cyst debridement with autograft implantation.

Dawe et al. approached a cystic OLT with arthroscopic decompression and implantation of a demineralized bone matrix gel.<sup>16</sup> The patient complained of ankle pain worsening over one month, especially after prolonged standing, and was diagnosed with a large posterior talar cystic lesion by MR and CT imaging. A posterior two-portal approach to arthroscopy was used, and the posterior talus was drilled for bone marrow stimulation without perforating the ankle joint.<sup>16</sup> The defect was then filled with a demineralized bone matrix gel (Grafton gel), and the patient was fitted with a below the knee plaster backslab for six weeks while NWB. Return to regular activity level was reported as gradual. At a follow-up of three and a half years, the patient had no pain at rest and mild pain while running.<sup>16</sup> The use of a matrix gel to fill an OLT defect is not a commonly

used approach, but these results may warrant further studies with its use.

Another novel adjunctive therapy to arthroscopy was investigated in Kim et al. with the use of a mesenchymal stem cell injection.<sup>17</sup> This study included fifty ankles with OLTs, nineteen of which were cystic, that had all remained symptomatic after at least three months of nonsurgical treatments. Patients were divided between a group receiving conventional arthroscopy with bone marrow stimulation and a group including injection of a stromal vascular fraction (SVF) containing mesenchymal stem cells (MSC).<sup>17</sup> The SVF injection was derived from the patient's buttock adipose tissue collected one day prior to the procedure. All patients received standard arthroscopic debridement and microfracture, including abrasion arthroplasty in cases with subchondral bone loss, and removal of all cystic material where appropriate. Lastly, after extraction of arthroscopic fluid within the ankle joint, the MSC group received the SVF injection.<sup>17</sup> Patients were left NWB in a short leg splint for two weeks with ankle range of motion exercises begun at four weeks and return to sports at three months. At an average follow-up time of 21.9 months, both groups had significantly increased AOFAS and VAS scores; however, the MSC group had a significantly higher improvement in both metrics.<sup>17</sup> There was also a significantly higher MOCART score increase in the MSC group, though both groups did see a significant

improvement. The MOCART score improvement was correlated to the clinical outcome measures (AOFAS and VAS scores). Fifteen patients overall underwent lateral ligament reconstruction during the OLT procedure, but these outcomes were not separately reported, thus complicating reported results. This study suggests adipose-derived MSCs can significantly enhance cartilage growth and repair and may be useful as effective adjunctive therapy for arthroscopic OLT treatment.<sup>17</sup>

Arthroscopy with bone marrow stimulation alone may be useful in treating symptomatic small or midsize talar bone cysts, as well as arthroscopy with autograft or hydroxyapatite implantation.<sup>7, 12, 13, 14, 15</sup> In mixed hindfoot pathologies, os trigonum edema or FHL tendinitis may contribute to the presence of ankle pain. In those cases, arthroscopy can provide a less invasive procedural approach to treatment.<sup>13</sup> When supplemented by bone matrix gel or stem cell injections, arthroscopy with bone marrow stimulation can provide significant pain reduction in symptomatic cystic OLTs.<sup>16, 17</sup> However, there are some practical limitations to arthroscopy for treatment of cystic talar lesions. Depending on the location and size of the lesion, access for adequate debridement or graft implantation may require a medial malleolar osteotomy and thus open surgery.

#### *OPEN SURGERY*

Autologous osteochondral transplantation is a technique in which the defect is filled by one or more harvested cylindrical osteochondral grafts, most commonly from the ipsilateral knee.<sup>24, 25</sup> It is attempted on large, primary cystic lesions or failed secondary lesions in order to replace damaged cartilage with a graft that has similar biological and mechanical properties to the native cartilage.<sup>24, 25</sup> As such, an advantage of this procedure is the ability to replace the defect with viable cartilage in a one-stage procedure.<sup>24</sup> Disadvantages include the need for graft harvest, associated donor site morbidity, differences in surface curvature between the graft and intended tissue, poor healing potential at the cartilage interface of the graft, and possible need for osteotomies.<sup>24</sup>

The site of the lesion determines whether a medial or lateral approach is used. If the lesion is posteromedial, a medial malleolar osteotomy is usually required. A lateral malleolar osteotomy is less likely to be required as adequate exposure can be obtained with release of the anterior talofibular ligament, anterior subluxation, and forced plantar flexion.<sup>18, 21</sup> Anteromedial or lateral lesions usually require only an arthrotomy.<sup>18, 21</sup> Once sufficient exposure has been obtained, the lesion is debrided.<sup>18, 21</sup> By correlating previously obtained images (CT or MRI) and intraoperative findings, the center of the cystic lesion is determined and drilled perpendicularly.<sup>18</sup> Scranton et al. pointed out that conventionally, the

cyst is cored rather than drilled.<sup>18</sup> They postulate that drilling is better than coring because it allows for the creation of a more cylindrical recipient hole for the graft.<sup>18</sup> It also allows for the treatment of larger cysts using only one plug.<sup>18</sup> However, a second or even a third hole can be created adjacent to the first if “nesting” of grafts is necessary.<sup>18</sup> The number of additional grafts needed is determined by the nature of the cyst. An oblong cyst will allow for two grafts to be nested side by side whereas a larger (i.e.  $\leq 20\text{mm}$ ) cyst will allow for three.<sup>18</sup> The donor graft is measured to carefully match the size of the recipient hole in the talus. It should be noted that improper matching could be the difference between success and failure. The next step, arguably the most important step in the procedure, is the placement of the donor graft(s) in the most congruent position possible to avoid surface incongruities on the talus.<sup>4</sup> Finally, the medial malleolus is reduced and fixed with cannulated screws.<sup>18, 21</sup>

In the Hu et al. study, the authors investigated the outcomes of autologous iliac crest osteoperiosteal cylinder graft transplantation for the treatment of medial osteochondral lesions of the talus with large subchondral cysts.<sup>21</sup> They reported a reduction in VAS and improvement in AOFAS scores.<sup>21</sup> Similarly, Scranton et al. retrospectively investigated the outcomes of an autologous knee osteochondral graft for the treatment of type V cystic osteochondral lesions

of the talus.<sup>18</sup> They also reported an improvement in pain symptoms.<sup>18</sup> However, Scranton reported that many patients needed subsequent surgery. Seventeen patients needed further surgery while ten underwent arthroscopic debridement. Four patients had malleolar screws removed while two patients had degenerative changes and underwent arthrodesis after osteochondral autograft failure.<sup>18</sup> These studies demonstrate the potential for autologous transplantation for the treatment of a cystic lesion of the talus. However, the techniques are demanding and could necessitate future procedures to correct any complications.<sup>18, 21</sup>

In their study, Garcia et al. detailed the first clinical report regarding treatment outcome of biosynthetic scaffold (TRUFIT plug) for osteochondral lesion of the talus.<sup>19</sup> Theoretically, the scaffold provides a three-dimensional platform for the chondrocytes to proliferate while maintaining the articular surface.<sup>26</sup> The indications for surgery were recurrent lesion after failed surgical treatment or a primary Berndt and Harty Stage-V lesion.<sup>19</sup> One patient had a cystic lesion of the talus. To get adequate exposure, a chevron osteotomy of the medial malleolus was performed.<sup>19</sup> The lesion was visualized, measured, and the underlying sclerotic cyst removed using a reamer.<sup>19</sup> The implant was then placed into the talus, flush with the chondral surface, and then irrigated with sterile saline solution.<sup>19</sup>



The medial malleolar osteotomy was repaired using 4.0mm cannulated screws.<sup>19</sup> At final follow-up, the patient reported preoperative pain levels and demonstrated clinical and radiographic evidence of implant failure.

Although previous studies demonstrated the potential for successful treatment of osteochondral defects, in this study by Garcia et al., the treatment did not work.<sup>19</sup> The authors theorize that graft failure occurred due to the location of the implantation.<sup>19</sup> Since the talus is part of a very mobile joint, the inherently higher joint reaction forces caused graft failure.<sup>19</sup> Furthermore, the patients, who were active-duty soldiers, had an increased tendency to participate in demanding physical activities thereby increasing the chance of graft failure. Stronger and more robust scaffolds could address the aforementioned problems. The study by Garcia et al. highlighted the need for the physician to choose a treatment based on the circumstances of an individual patient.

In their prospective case report, van Bergen and colleagues described the first use of a contoured metallic implant (HemiCAP) for the treatment of a large cystic osteochondral defect of the medial talar dome.<sup>20</sup> To get adequate exposure for proper implantation of the device, van Bergen et al. performed an oblique osteotomy of the medial malleolus and excision of the necrotic fragment.<sup>20</sup> The prosthetic device was placed onto

a previously inserted screw at an implantation level of 0.5mm below the adjacent cartilage.<sup>20</sup> The prosthetic device was placed slightly below the surrounding surface of the articular cartilage because the talar cartilage undergoes deformation during WB while the metallic implant does not. The patient recovered well and reported little to no pain at final follow-up.<sup>20</sup>

Though the patient, a twenty year old female, presented with deep ankle joint pain during and after activity, the exact indications for treatment with a metallic implant have yet to be determined.<sup>20</sup> Van Bergen and colleagues suggest this approach in patients who have had continuing severe pain for more than one year after failed treatment through arthroscopic debridement and bone marrow stimulation.<sup>20</sup> The same authors do not recommend this procedure for patients who are under the age eighteen or who present with an osteochondral defect larger than 20mm, ankle osteoarthritis grade II or III, accompanying ankle pathology, advanced osteoporosis, infection, diabetes, or known allergy to the implant material.<sup>20</sup> However, these guidelines need to be substantiated with more evidence and long-term studies before this procedure can be recommended as a standard approach.

#### *PERCUTANEOUS BONE CEMENT*

He et al. reported clinical success with percutaneous injection of PMMA into

a cystic lesion. The patient sustained a traumatic injury four years prior. MRI one year post-injury revealed no abnormalities, despite recurrent pain. The patient sought treatment due to one month of intolerable pain after jogging. CT and MRI studies demonstrated presence of a cystic OLT. Due to the wide use of percutaneous vertebroplasty (PVP) for the immediate and long-term pain relief in malignant bone lesions of the spinal column, He et al. opted to treat the patient with percutaneous osteoplasty (POP), an extension of PVP for bone lesions outside of the spine.<sup>22</sup>

The cyst was punctured and aspirated with a large gauge needle under a fluoroscope with digital subtraction angiography. The injection of contrast material revealed a small channel of communication between the cyst and the ankle joint space. The PMMA was then slowly injected into the cavity. Care was taken to avoid extravasation of PMMA due to the potential for chondrolysis. Postoperative x-ray confirmed that the PMMA completely filled the cavity without escaping into the joint space. Patient reported VAS of 0 at final follow-up.<sup>22</sup>

Maurel et al. used a similar percutaneous approach for the treatment of cystic lesions in patients presenting with intense mechanical pain not improved by analgesics. However, Maurel et al. used a calcium phosphate cement (CPC) rather than PMMA. Experimental and clinical data suggest that CPC is a potential

alternative for autologous bone grafting due to its bioactive and biodegradable alloplastic properties. Thus, the authors determined that CPC was preferable because of the potential for leakage into the joint space and subsequent chondrolysis. The procedure was performed under fluoroscopic guidance with contrast and no articular cement leak was observed. The patient with a cystic talar lesion reported a VAS of 0 at final follow-up. Interestingly, the final CT showed complete absorption of cement and formation of new bone, suggesting that CPC may stimulate bone growth.<sup>23</sup>

The abundant innervation of bone marrow could explain the presence of pain symptoms before radiological detections of cystic osteolysis as seen in the case report by He et al.<sup>2,22</sup> Research shows that mineralized bone is innervated by both unmyelinated and myelinated A-b, A-delta, and C-type nociceptive fibers. Areas of bone with the most WB have the most vasculature and innervation. The sequence of increased bone fluid pressure, osteonecrosis, and bone remodeling has been proposed as the cause of cystic OLTs. The subsequent chronic activation of macrophages and alterations in vasculature and pH would lead to the activation of nociceptive fibers. Therefore, because the talus is under a large amount of mechanical stress and loading on WB, the talus is highly innervated.<sup>2</sup>

Bone cement is known to provide pain relief in benign and malignant lesions

of axial and appendicular bones. He et al. and Maurel et al. propose several mechanisms for the efficacy of bone cement in pain relief. Bone cement may provide stabilization to the bone matrix, preventing microfractures and associated bone pain. It may also lead to thermal necrosis of nerves in the area, effectively providing nerve ablation.<sup>22, 23</sup> Percutaneous injection of bone cement avoids many of the disadvantages of surgical interventions, such as harvest site morbidity, infection, and cost, while providing immediate and long-term pain relief. Although not yet supported by conclusive studies, these preliminary studies suggest that the percutaneous injection of bone cement should be considered a minimally invasive intervention for talar bone cysts.

## CONCLUSION

Although the definite etiology of talar bone cysts is unknown, it is postulated that cartilage defect and subsequent intrusion of cartilage fluid into the bone contribute to the development of a cystic lesion. The increased fluid pressure and osteonecrosis leads to the symptom of pain and the sign of a slowly enlarging cyst.<sup>1, 2, 7</sup> The surgical approaches outlined in this paper are arthroscopic, open, and percutaneous injection, and the main outcome reviewed was successful pain reduction.

Arthroscopic debridement with a combination of bone marrow

stimulation and/or autograft, bone marrow matrix gel, or MSC all showed good postoperative pain reduction. The Han et al. and Lee et al. studies report that there was no difference in the outcome of debridement and bone marrow stimulation between patients with cystic and noncystic OLTs.<sup>7,12</sup> Their studies suggest that this surgical approach is indicated in the treatment of OLTs regardless of the presence of an associated cystic lesion. Two studies by Lui et al. and one by Ogut et al. demonstrate that debridement and bone marrow stimulation with autograft also gives good outcomes.<sup>13, 14, 15</sup> However, it is unclear when the adjunct of autograft is indicated in the treatment of a talar bone cyst. Dawe et al. and Kim et al. describe novel adjuncts to standard arthroscopic debridement and stimulation.<sup>16,17</sup> Although both report good outcomes, further studies are needed to corroborate their findings.

The studies on open surgical approaches were more varied in outcome. The Scranton et al. and Hu et al. studies reported good outcomes with open placement of autograft.<sup>18, 21</sup> The use of a metallic implant also had good outcomes but was the first study of its kind.<sup>20</sup> Garcia et al. had complete failure of implant in a Stage V lesion after an off-label use of a biosynthetic scaffold plug.<sup>19</sup> Both studies on the percutaneous injection of bone cement had good postoperative pain reduction.<sup>22, 23</sup> However, percutaneous injection does not allow for direct visualization of

the articular surface. The cystic lesions described by He et al and Maurel et al. may be associated with small undetected cartilage defects that may, over time, produce another cystic defect.<sup>22, 23</sup> Alternatively, cystic lesions with little cartilage involvement may indicate the percutaneous approach. Longer follow up studies are needed to determine the indications for percutaneous bone cement injection.

There are some limitations to the studies investigated for this systematic review. Many of the studies lacked control groups, used different postoperative management regimens, and reported different pain and ankle function metrics. The studies also varied in their approach to reporting cyst size. Some studies did not report specific measurements at all, opting for subjective terms like “large,” and the studies that did report measurements did not take a consistent approach, some reporting one dimension of measurement while others reported two or three dimensions. This makes it difficult to draw comparisons between study outcomes. Some study results are also complicated by other surgical interventions performed concomitantly to or as a postoperative consequence of the approach under investigation. The intervening surgical interventions included FHL debridement, os trigonum excision, and lateral ligament reconstruction.<sup>13, 17, 18</sup> Due to these extra variables it is difficult to determine if the outcome can be correlated to the specific

treatment under question. Some studies also included the presence of cysts as a secondary variable to treatment type. In these studies patients were divided into two treatment groups, standard and standard with adjunct, with each group containing some noncystic and cystic lesions.<sup>7, 12</sup> The studies did not consistently report on the subset of patients with cystic lesions as a group distinct from the subset with noncystic lesions, making it difficult to determine if the outcomes were related to the treatment, presence of cyst, or both. In general, longer post-procedure follow-up would be beneficial. Due to the relative rarity of talar bone cysts, larger studies have been difficult to conduct, but there is potential for future multi-center research studies that pool patients with symptomatic talar bone cysts.

## AUTHORS’ CONTRIBUTIONS

All authors participated equally in the conception of the research topic, literature review, and extraction of data. All authors agreed upon the final submission.

## STATEMENT OF COMPETING INTERESTS

The authors declare that they have no competing interests.

## REFERENCES

1. McCollum GA, Myerson MS, Jonck J. Managing the cystic osteochondral defect: allograft or autograft. *Foot and Ankle Clinics*. 2013; 18(1): 113-133.
2. Van Dijk CN, Reilingh ML, Zengerink M, van Bergen CJA. Osteochondral defects in the ankle: why painful? *Knee Surgery, Sports Traumatology, Arthroscopy*. 2010; 18(5): 570-580.
3. Zengerink M, Szerb I, Hangody L, Dopirak RM, Ferkel RD, van Dijk CN. Current concepts: treatment of osteochondral ankle defects. *Foot and Ankle Clinics*. 2006; 11(2): 331-359.
4. Anderson IF, Crichton KJ, Grattan-Smith T, Cooper RA, Brazier D. Osteochondral fractures of the dome of the talus. *J Bone Joint Surg Am*. 1989; 71(8): 1143-1152.
5. Scranton PE, McDermott JE. Treatment of type V osteochondral lesions of the talus with ipsilateral knee osteochondral autografts. *Foot & Ankle International*. 2001; 22(5): 380-384.
6. Raikin, SM. Stage VI: massive osteochondral defects of the talus. *Foot and Ankle Clinics*. 2004; 9(4): 737-744.
7. Lee K, Park H, Cho H, Seon J. Comparison of arthroscopic microfracture for osteochondral lesions of the talus with and without subchondral cyst. *The American Journal of Sports Medicine*. 2015; 43(8): 1951-1956.
8. McCullough CJ, Venugopal V. Osteochondritis dissecans of the talus: the natural history. *Clinical orthopaedics and related research*. 1979; 144: 264-268.
9. Schachter AK, Chen AL, Reddy PD, Tejwani NC. Osteochondral lesions of the talus. *Journal of the American Academy of Orthopaedic Surgeons*. 2005; 13(3): 152-158.
10. Myerson, MS. Reconstructive foot and ankle surgery: management of complications. 2nd edition. Philadelphia: Elsevier; 2010. 397-408.
11. Tol JL, Struijs PA, Bossuyt PM, Verhagen RA, van Dijk CN. Treatment strategies in osteochondral defects of the talar dome: a systematic review. *Foot & Ankle International*. 2000; 21(2): 119-126.
12. Han SH, Lee JW, Lee DY, Kang ES. Radiographic changes and clinical results of osteochondral defects of the talus with and without subchondral cysts. *Foot Ankle Int*. 2006; 27(12): 1109-14.
13. Ogut T, Seker A, Ustunkan F. Endoscopic treatment of posteriorly localized talar cysts. *Knee Surg Sports Traumatol Arthrosc*. 201; 19(8): 1394-8.
14. Lui TH. Arthroscopic bone grafting of talar bone cyst using posterior ankle arthroscopy. *J Foot Ankle Surg*. 2013; 52(4): 529-32.
15. Lui TH. Endoscopic curettage and bone grafting of huge talar bone cyst with preservation of cartilaginous surfaces: surgical planning. *J Foot Ankle Surg*. 2014; 20(4): 248-52.
16. Dawe EJ, Jukes CP, Gougoulis N, Wee A. Successful arthroscopic decompression and synthetic grafting of a posterior talar cyst: a case report. *J Foot Ankle Surg*. 2014; 20(2): e35-6.
17. Kim YS, Lee HJ, Choi YJ, Kim YI, Koh YG. Does an injection of a stromal vascular fraction containing adipose-derived mesenchymal stem cells influence the outcomes of marrow stimulation in osteochondral lesions of the talus? A clinical and magnetic resonance imaging study. *Am J Sports Med*. 2014; 42(10): 2424-34.
18. Scranton PE Jr, Frey CC, Feder KS. Outcome of osteochondral autograft transplantation for type-V cystic osteochondral lesions of the talus. *J Bone Joint Surg Br*. 2006; 88(5): 614-9.
19. Garcia EJ, Bear RR, Schoenfeld AJ, Owens BD. Treatment of osteochondral lesions of the talus with a biosynthetic scaffold: a report of

- four cases. *J Bone Joint Surg Am*. 2010; 92(8): 1774-9.
20. van Bergen CJ, Reilingh ML, van Dijk CN. Tertiary osteochondral defect of the talus treated by a novel contoured metal implant. *Knee Surg Sports Traumatol Arthrosc*. 2011; 19(6): 999-1003.
  21. Hu Y, Guo Q, Jiao C, Mei Y, Jiang D, Wang J, Zheng Z. Treatment of large cystic medial osteochondral lesions of the talus with autologous osteoperiosteal cylinder grafts. *Arthroscopy*. 2013 Aug;29(8):1372-9. doi:10.1016/j.arthro.2013.05.014. PubMed PMID: 23906276.
  22. He Y, Wu C, Gu Y, Cheng Y. Percutaneous osteoplasty for the treatment of symptomatic subchondral cyst. *J Vasc Interv Radiol*. 2012; 23(6): 848-50.
  23. Maurel B, Le Corroller T, Bierry G, Buy X, Host P, Gangi A. Treatment of symptomatic para-articular intraosseous cysts by percutaneous injection of bone cement. *Skeletal Radiol*. 2013; 42(1): 43-8.
  24. Murawski, C. D., & Kennedy, J. G. (2013). Operative treatment of osteochondral lesions of the talus. *J Bone Joint Surg Am*, 95(11), 1045-1054.
  25. Hannon, C. P., Smyth, N. A., Murawski, C. D., Savage-Elliott, I., Deyer, T. W., Calder, J. D. F., & Kennedy, J. G. (2014). Osteochondral lesions of the talus. *Bone Joint J*, 96(2), 164-171.

# A Systematic Qualitative Literature Review on the Surgical Management of an Acute Achilles Tendon Rupture

*Kenny Luong, BA, Wesley Nesbit, BA, & Jones Thomas, BS*

## Abstract

### **Introduction**

In recent years, numerous techniques and materials have been introduced for the surgical treatment of Achilles tendon ruptures. This systematic review aims to present the efficacy and limitations of the latest surgical methods so that the surgeon can make the most informed decision possible.

**Study design:** Systematic Qualitative Review of the Literature

### **Methods**

An English language literature search was conducted on the PubMed database. Papers relating to surgical Achilles tendon repair were found using the search terms “achilles tendon\$ repair AND (Kessler or Bunnell or Krackow)”. The search was further restricted to include papers from January 2010 to the present and humans only.

### **Results**

The PubMed database search resulted in 26 articles. After a preliminary screening three were excluded because they were not in English. After reviewing all the articles, four did not pertain to acute Achilles tendon ruptures. As a result, 19 articles were used in this systematic qualitative literature review comparing open wound and minimally invasive surgical options for an acute Achilles tendon rupture.

### **Discussion and Conclusion**

Many surgical options are available for the repair of an acute Achilles tendon rupture. The two main surgical options are open wound repair and minimally invasive repair. With open wound repair, there are variations in techniques, suture types and augmentation with grafts. With minimally invasive repair, numerous different techniques are available, all aimed to prevent post-operative complications seen in open repair. This overview may be helpful in guiding the surgeon in deciding which surgical option is suitable for the repair of an acute Achilles tendon rupture.

**Key Words:** Achilles Tendon, Acute Achilles Tendon Rupture, Open Wound Repair, Minimally Invasive Repair

*Levels of Evidence: 4*

## INTRODUCTION

Acute Achilles tendon (AT) ruptures are one of the most common tendon injuries of the foot and ankle and among the most commonly ruptured tendons in the human body.<sup>1, 2</sup>

Ruptures of the Achilles tendon occur in the third to fourth decade of life, mostly in men, and have an annual incidence of 18 to 37 cases per 100,000 persons.<sup>3</sup> It is possible for the Achilles tendon to rupture with intact tibialis posterior, flexor hallucis longus, and flexor digitorum longus allowing for weak plantarflexion. This can complicate the diagnosis of Achilles tendon rupture along with the lack of pain and swelling.<sup>1</sup> Some common diagnostic tests used by surgeons include Thompson calf-squeeze test, Matles test, O'Brien needle test, and Copeland sphygmomanometer test as well as imaging.<sup>1</sup>

There are many different treatment options available for Achilles tendon ruptures and it may be difficult to decide which one is most appropriate. Treatment options can be classified into non-surgical and surgical types. Non-surgical management includes cast immobilization or functional bracing with functional rehabilitation.<sup>2</sup>

Non-surgical management requires the patient to be immobilized for an extended period and has a risk of re-rupture as late as six months.<sup>4</sup> Therefore it can be difficult for physically active patients to receive non-surgical treatment. Surgical management can be divided into open

repair and percutaneous or minimally invasive. When compared to non-surgical treatment, surgical treatment will decrease the tendon re-rupture rate and calf atrophy, provide early functional treatment, and stronger push off.<sup>2</sup> The complications of surgical treatment include injury to the sural nerve and possible wound breakdown and infection. Minimally invasive techniques have the advantage of having a decreased risk of wound breakdown. However, there is a greater chance of tendon re-rupture when compared to open tendon repair.<sup>2</sup>

There have been greater than 60 different surgical methods with various suture combinations that have been described so far.<sup>4</sup> New suture materials have been used with new suture techniques with varying amounts of success. It can be difficult for the surgeon to gather all the information needed in order to decide which surgical procedure is best for them. The objective of this literary review is to assess the efficacies and restrictions of the current surgical treatment options in order for the surgeon to be able to make an informed decision to create the most stable surgical construct.



## METHODS

An English language literature search was conducted on the PubMed database. Papers relating to surgical Achilles tendon repair were found using the search terms “achilles tendon\$ repair AND (Kessler or Bunnell or Krackow)”. The search was further restricted to include papers from January 2010 to the present and humans only.

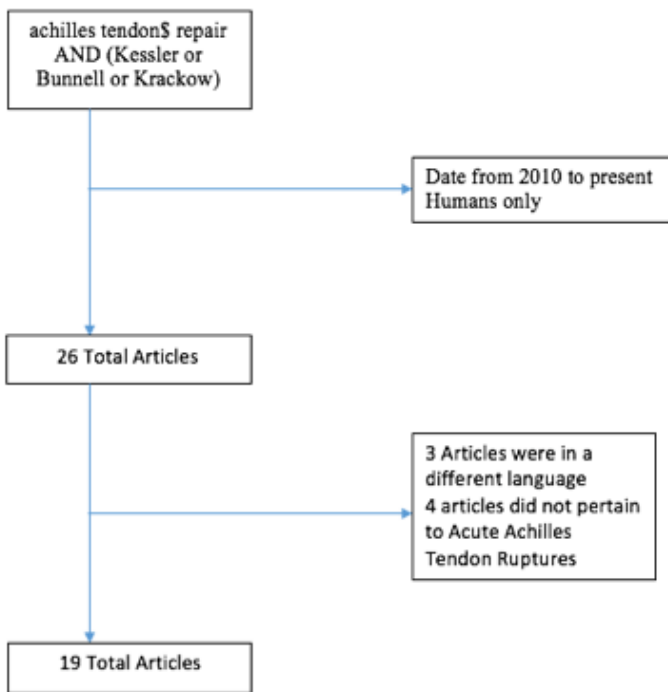
## RESULT

The PubMed database search resulted in 26 articles. After a preliminary screening three were excluded because they were not in English. After reviewing all the articles, four did not pertain to acute Achilles tendon ruptures. As a result, 19 articles were used in this systematic qualitative literature review comparing open wound and minimally invasive surgical options for an acute Achilles tendon rupture.

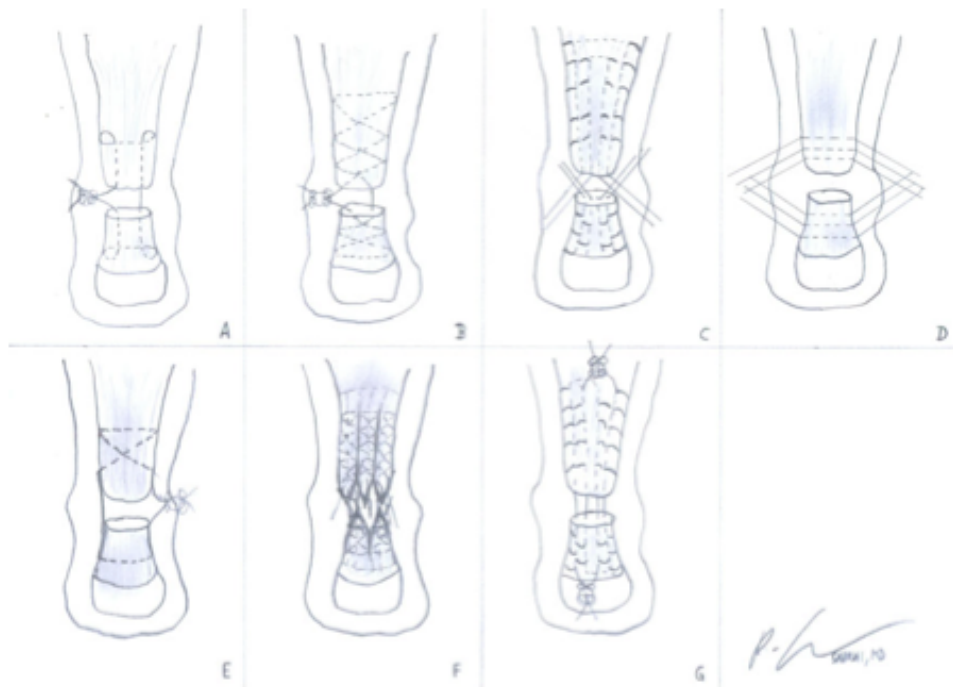
## DISCUSSION

### Open Wound Repair

Open wound repair is the preferred option for many physicians in repairing acute Achilles tendon (AT) ruptures.<sup>5</sup> Among many benefits, the main advantages of open wound repair include a lower risk of AT re-rupture, the ability to set the tension of the repaired tendon, and confidence in early motion rehab with less risk to the repair site.<sup>6</sup> Also, it allows the surgeon to more precisely secure the approximation of the tendon which results in a lower re-rupture rate.<sup>7</sup> The open wound repair technique offers the surgeon the ability for great customization tailored to their patient's needs. Not only are there several different techniques for the surgeon to choose from for an open wound repair, but there are also several varying options of suture materials to use, and whether or not grafts should be incorporated.



**Fig. 1** Literature search on PubMed Database



**Fig. 2** Illustration of different surgical techniques for an Achilles tendon repair: A) Open Kessler suture, B) Open Bunnell suture, C) Open Krackow suture, D) Percutaneous Achillon Device, E) Percutaneous Ma-Griffith technique, F) Open Triple Bundle suture, G) Open “Gift Box” suture

### *Bunnell, Krackow, and Kessler Suture techniques*

The Bunnell, Krackow and Kessler Suture techniques are the techniques most commonly used today. Studies have shown that the aforementioned three approaches differ in their results. The physician using these techniques, should first understand these differing results in order to provide for the most effective technique as possible. Herbort et. al reported that the Bunnell method shows the capability to maximize biomechanical behavior when stronger suture material is used compared to the other techniques.<sup>4</sup> Likewise, Gebauer et al. reported that the Bunnell suture was stronger than Kessler technique in its primary suture stability,<sup>4, 8</sup> while Sadoghi et al. found that for direct end to end repair, the

Bunnell technique had the highest tensile strength.<sup>4</sup> Villarreal et al. states that the Bunnell suture is the gold standard.<sup>1</sup> However, Hsu et al. stated that the Krackow suture is the most commonly used technique in an open wound repair.<sup>9</sup> Based on these studies, it seems as though the Kessler method has poor results, but McCoy and Haddad described no difference in average failure load between the three approaches.<sup>4, 6, 8</sup> In addition, there are variations within each suture type. With Bunnell, Krackow and Kessler, a single or a double approach can be used, meaning the suture can consist of either one loop or two loops. McCoy and Haddad though, found that the Double Bunnell and the Double Kessler techniques were stronger than their single approach counterparts.<sup>8</sup> From the many sources,

though the Bunnell technique may have the best lab results, while the Krackow suture is used most common, all three techniques are widely used when performing an open wound Achilles tendon repair.

However, with open wound repair procedures like Bunnell, Krackow and Kessler, there are some disadvantages and risks. There is always a risk of superficial and deep wound complications<sup>9</sup> including infections and ankle stiffness from seriously compromised blood supply.<sup>5</sup> Additionally, these techniques can undermine otherwise intact tissue, thus causing an underlying blood circulatory disorder and impaired tendon healing.<sup>5</sup> Another disadvantage is that repair methods like these three methods where sutures sit on the surface of the tendon leads to a possible nidus for adhesion.<sup>5, 10</sup> A disadvantage specific to the Bunnell, Krackow and Kessler techniques is that all three suture knots are tied within the rupture site which increases the risk for early failure.<sup>3</sup>

#### *Gift Box Open Achilles Repair Method*

The Gift Box method resembles the Krackow technique but differs in 3 aspects.<sup>3</sup> First, the transverse limb of the gift box is passed through the tendon during the transition from one side to the other side, rather than passing over the tendon. Second, 4 suture strands cross the rupture site in the gift box technique whereas 2 suture strands cross the rupture site in the Krackow technique. Lastly, each

pair of crossing strands are passed 1 limb superficially and 1 limb deep to the other transverse limb, and the knots are secured on the superficial surface.<sup>3</sup> It was reported that the Gift Box method was twice as strong as the Krackow technique.<sup>3, 4</sup> Labib et al. states numerous advantages over the Krackow technique, including an improved repair strength and less gap formation from increased strands across the repair site. Having the sutures tied away from the repair site avoids possible early failure from stress at the rupture site, and passing sutures around the transverse limb of the counter suture improves the repair strength.<sup>3</sup> However, disadvantages still exist. Like with the Bunnell, Krackow and Kessler techniques, there is always an increased risk of wound complications.<sup>9</sup> Though this method may be different from Krackow's method, there still is substantial amount of suture material on the surface of the tendon giving rise to the risk of a possible nidus for adhesion.<sup>5, 10</sup>

#### *Other Suture Techniques*

Hong et. al looked to find an alternative to the Krakow technique and describes a core stitch weave that is a modification of the Krackow stitch, which he states exposes too much of the suture on the surface giving to a possible nidus for adhesion.<sup>10</sup> With the core stitch weave, the suture crosses through the tendon with most of the suture buried within the tendon.<sup>10</sup> It was reported that there was no significant difference in functional strength

between the core stitch weave and the Krackow suture.<sup>10</sup> Furthermore, sutures elsewhere could help the post op results of an Achilles tendon repair. Shepard et al. solidified this point when they described the addition of epitenon sutures to significantly increase the force necessary to produce a 2-mm gap.<sup>4</sup>

### *Suture types*

Researchers and physicians have been looking into other ways to improve the repair of an acute AT rupture by testing different material and types of sutures. Conventionally, braided non-absorbable sutures are used in an Achilles tendon repair with many different brands. No. 2 FiberWire suture is used in a study by Kanz et al. and it was reported that Fiberwire is quite strong at peak loads, remaining intact beyond 5 mm of gapping.<sup>11</sup> Kanz et al. compared the No.2 FiberWire to a single strand of knotless barbed suture, specifically the bidirectional, knotless barbed No. 2 Quill polypropylene suture.<sup>11</sup> When compared to a No. 2 FiberWire suture, the No. 2 Quill polypropylene suture was reported to have a greater mean load sustained at initial gapping, a greater resistance to gap formation, and was quicker to suture in, however, the No. 2 Quill polypropylene was unable to reach 5 mm of gapping without breaking at the repair site.<sup>11</sup> Cook et al. also looked into different suture materials to see how different suture materials would affect the repair. They compared a 2-0 FiberLoop, which was a type of FiberWire, and a braided polyester

suture, called Ethibond.<sup>4, 12</sup> It was reported that the smaller-caliber 2-0 FiberLoop was stronger than the Ethibond suture.<sup>4, 12</sup>

### *High Tensile Strength Tape*

Gnandt et al. looked into using high tensile strength tape, specifically FiberTape by Arthrex, rather than sutures for closing the gap of a ruptured Achilles tendon. The tape consists of high strength, non-absorbable polyblend suture core. This core is centrally incorporated within a flat braided construct of an ultra-high molecular weight polyethylene (UHMWPE) fiber, blended with fibers of one or more long chain synthetic polymers, polyester being preferred.<sup>13</sup> The suture tape allows for larger tissue contact area, which spreads the force out over a broader area improving performance.<sup>13</sup> Gnandt et al. compared the suture tape to No. 2 braided non-absorbable polyblend high-tensile strength suture, with the suture tape having a greater maximal load to failure.<sup>13</sup> However, a disadvantage not stated by Gnandt et al. is the issue of cost efficiency. Braided non-absorbable polyblend high-tensile strength suture is readily available in the operating room, and does not need to be purchased as would high tensile strength tape need to be.

### *Augmentation with Grafts*

Another open wound technique for the repair of an acute Achilles tendon rupture repair is the use of a graft. Augmentations are used instead of using just sutures, because the sutures themselves are the weak link of the repair.<sup>6</sup> Allografts, autografts and xenografts have all been talked about in the literature.<sup>6</sup> Berlet et al. looked into the use of Trellis Collagen Ribbon, a collagen ribbon xenograft, augmented with a Krackow suture.<sup>6</sup> Berlet et al. wove the xenograft into the AT in a box pattern. The collagen ribbon xenograft showed improved cyclic loading performance as well as in the pull to failure test compared to just sutures.<sup>6</sup> Wisbeck et al. looked into the use of an AT repair by using a Krackow technique repair augmented with a xenograft scaffold in a full-wrap configuration called Conexa, which is a porcine dermal matrix.<sup>14</sup> The Conexa xenograft had higher stiffness, load to clinical failure and load to ultimate failure compared to a standard Krackow suture.<sup>14</sup> Wisbeck et al.'s research supported the research of Barber et al., who reported that an Achilles repair is stronger with the use of an allograft dermal matrix augmentation.<sup>14, 15</sup> Barber et al. also researched the use of GraftJacket, an acellular dermal matrix allograft, which was reported to have an increased repair strength and stiffness. Magnussen et al. researched the use of TissueMend Soft Tissue Repair Matrix, which is a bovine extracellular matrix xenograft.<sup>15</sup> Results showed that the bovine extracellular matrix xenograft augmentation performed better in a

minimum ultimate failure load test and showed less gap formation compared to a Krackow technique repair.<sup>15</sup> However, there are a few disadvantages in using a graft augmentation. These procedures require longer surgical times, which can ultimately lead to an increased risk of wound complications.<sup>14</sup> Moreover, with the use of grafts, there is an increased cost factor.<sup>15</sup>

Studies have shown the advantages of an open wound repair, which include a lower risk of re-rupture, the ability to set the tension of the repaired tendon, and confidence in early motion rehab with less risk to the repair site, among many other benefits.<sup>6</sup> Also, it allows the surgeon to be more precise with securing the approximation of the tendon, which results in a lower re-rupture rate.<sup>7</sup> However, this treatment protocol also carries with it, its own fair share of complications such as the development of infections from the wounds inflicted, hypertrophic scars, skin tethering, and most importantly, the possibility of a sural nerve lesion.<sup>5,7</sup>

### **Minimally Invasive Repair**

An alternative to open wound repair of an acute AT rupture is a percutaneous or minimally invasive repair. Studies have shown that minimally invasive Achilles repair compared to open wound repair have lower complication rates and improved cosmetic appearance.<sup>9</sup> Due to the complications associated with the open treatment protocol, many surgeons have elected to follow the minimally invasive route which offers less of a chance for their

patients to develop infections. Like with open wound repair, minimally invasive repair offers multiple options.

### *Ma and Griffith Technique*

In 1977, the researchers Ma and Griffith were the first to describe a percutaneous technique based on Bunnell sutures, as a treatment for AT rupture. This technique was thought to decrease adhesion and wound scarring as well as other complications associated with open wound repair.<sup>16, 17</sup> After reports came out that it caused a high rate of iatrogenic sural nerve complications, the procedure was heavily modified. Today, this modified technique is still used frequently in practice.<sup>7</sup>

### *Achillon ® Device*

Whereas the technique of the first percutaneous treatment of AT rupture by Ma and Griffith was based on using Bunnell Sutures<sup>1</sup>, there is a newer technique on the market based on the Box suture which uses 6 strands to cross the repair site<sup>18</sup>. This technique, known as the Achillon ® technique, seeks to lower the risk of sural nerve injury while offering a secure AT repair.<sup>18</sup> However, though there have been no findings that have shown a clear relationship between this device and sural nerve lesions, Chen et al. states that one should still be aware of the inherent risk of possible sural nerve injury as the suture needle is placed into the tissues.<sup>7</sup> Research has shown that the Achillon ® suture technique provides a stronger repair of the Achilles tendon than other repairs such

as the Krakow repair even when using identical sutures.<sup>4</sup> Results have shown that the Achillon ® suture system has been highly successful overall with minimal to zero infection or healing complications.<sup>18</sup> The major disadvantage associated with the Achillon ® technique however, is that though it may be stronger when compared to a 4 suture Krakow technique, it is not as strong as a 6 suture Krakow technique. Additionally, when the Achillon ® device fails, the sutures don't typically break, but due to the design of the device, they tend to simply rip right through the skin.<sup>18</sup> This tells us that the 6 sutures used with the Achillon ® device, and not the Achillon ® device itself, are what actually leads to its efficacy. Heitman et al. states that when properly performed, the Achillon device provides a stronger and more stable approach of AT rupture repair than one would find with a typical Krakow locking loop technique.<sup>18</sup> However, he then goes on to note that the advantage of a Krakow repair is that it results in a much stiffer construct when first loaded.<sup>18</sup>

### *Channel-assisted minimally invasive repair of acute Achilles tendon rupture (CAMIR)*

In the attempt to avoid a sural nerve damage that has typically plagued percutaneous procedures, a relatively new procedure designed by Chen et al. known as Channel-assisted minimally invasive repair (CAMIR) of acute Achilles tendon rupture was devised.<sup>7</sup> Chen et al. described the CAMIR

procedure as follows.

First, a transverse incision of approximately 1.5cm over the area of the AT rupture is made, exposing the paratenon. Next, through the CAMIR targeting hole in the limb, a series of 5 mm stab incisions are made. The paratenon sheath is cut open longitudinally approximately 1 cm while pushing proximally or pulling distally. Next, the sleeve is placed through the skin while also allowing the sheath to make its way through the hole of the internal limb of the CAMIR system. With the help of CAMIR, a Bunnell suture technique is performed.<sup>7</sup> These steps allowed for the suture to come out through the incision and sit between the proximal AT stump and the inside of the paratenon sheath. By having the suture knots outside of the AT, there is less possibility of destruction of the tendon's blood supply. In the follow-up of the patients who underwent the CAMIR procedure versus patients who underwent an invasive repair of the AT, Chen et al. described that the CAMIR patients showed greater strength of the AT and faster rehabilitation. Because the CAMIR procedure causes less injury to the paratenon, it keeps the blood supply fully intact to promote healing to the AT, and no wound infection complications were noted. Also, the suture knots in this procedure are placed on the outside portion of the AT, whereas suture knots in a typical Open Bunnell technique are placed between the proximal and distal AT tears. The placing of the suture knots outside of the AT, according to Chen et al., helps in the healing process of the AT by causing minimal destruction to the

blood supply. This technique allows for a very tight paratenon closure which adds significantly to its efficacy, as previous percutaneous techniques did not have this capability of such tight closure.<sup>7</sup>

#### *Tenocutaneous Suture*

W.-G. Ding et al. devised a study to help the surgical community understand the efficacy and drawbacks of a Tenocutaneous Suture method. Unlike in the CAMIR procedure which called for a 1.5cm transverse incision<sup>7</sup>, this procedure begins with a 3 cm transverse incision through the skin at the AT rupture site<sup>5</sup>. The sheath is longitudinally divided and the ruptured tendon is cleaned at the distal and proximal AT ends. Then a large triangular needle is used along with a double-stranded 10-gauge suture 4-5 cm from the distal end. The patient's foot is placed in plantarflexion in order to allow sufficient overlap of the proximal and distal AT ruptured ends of approximately 1 cm. When suturing, the knots are placed outside of the skin with a catheter sitting between the suture knots and the skin to prevent possible skin lesions at those sites.<sup>5</sup> In determining the efficacy of the Tenocutaneous Suture method, W.-G. Ding et al. compared the results of their patients who underwent the Tenocutaneous procedure versus another subset of patients under their care that only were treated by the Kessler Suture method. They found that the patients who underwent the Tenocutaneous procedure had similar results as those who underwent the Kessler suture.<sup>5</sup>

W.-G. Ding et al. found that patients who underwent the Tenocutaneous procedure experienced three main benefits over the patients who underwent other procedures such as the Kessler suture method.

- (1) This repair has minimal effect on the AT's blood supply which allows it to heal more efficiently.
- (2) This repair minimizes the number of sutures used to bring the torn AT ends together, thus, a lower risk for post-op complications.
- (3) The proximal and distal ruptured AT ends are saved and cleaned before overlap of the ends occurs. This allows for a more effective maintaining of continuity.<sup>5</sup>

Though this procedure has plenty of advantageous aspects to it in treating a ruptured AT, one should be aware that it also shares some of the drawbacks associated with many percutaneous procedures including minimized visibility compared to an open procedure, with the additional possibility for sural nerve damage.

#### *Percutaneous Achilles Repair System (PARS)*

Hsu et al. conducted research comparing typical Open Invasive surgical repair of an Achilles tendon and Achilles tendon repair by Percutaneous Achilles Repair System (PARS).

They found that one advantage PARS has compared to an open wound repair is that PARS uses an initial 2cm transverse skin incision whereas

typical open AT repairs utilize a 5-8cm longitudinal posteromedial incision.<sup>9</sup> The smaller incision used in PARS allows for a smaller wound size than would be found in a typical open invasive procedure, though it compares with the wound size of other minimally invasive techniques.

As compared to the Achillon ® technique, PARS showed improved construct strength under cyclic and ultimate loads.<sup>9</sup> Hsu et al. believes that due to the PARS procedure limiting wound size, that aspect led to more patients being able to resume their normal physical activities earlier at approximately 5 months post-op.<sup>9</sup> Also, it should be noted that while the typical open Achilles tendon repairs use suturing in a Krackow fashion, the PARS uses a PARS jig which itself is reusable but it also requires multiple locking and nonlocking FiberWire sutures which tend to drive the cost of the procedure up significantly.<sup>9</sup> Hsu et al., though they acknowledge that PARS procedures typically have a faster recovery time due to a smaller wound size, they also state that it may be the only advantage that PARS has because in their research they found that results from PARS procedures were very similar to those of a typical open AT repair. They did not find any evidence of significant differences in post-op complications for PARS compared to open repair procedures, though they did note evidence pointing to a small decrease in complications when using PARS. Their studies showed that though there was a higher incidence in open surgical techniques of minor complications such as sural neuritis, there was no distinguishing



difference between PARS and open repair in terms of major complications.<sup>9</sup> This suggests the question, does the possibility of a smaller wound site warrant the more expensive costs associated with the PARS in comparison to an open procedure? Hsu et al. says that to answer such a controversial question, more research needs to be done.<sup>9</sup>

#### *Mini-incision repair with double-Tsuge loop suture*

The Tsuge suture application is a continuous locking-loop suture pattern that is simple to complete and suitable for minimally invasive operations.<sup>19</sup> According to Fu and Qu, the mini-incision repair with double-Tsuge loop sutures is a promising minimally invasive treatment protocol for AT ruptures.<sup>19</sup> The study followed post op efficacy of patients after an open repair with modified Kessler sutures and patients who received mini-incision repair with double-Tsuge loop sutures.

The operational method of this procedure involves 2 incisions accompanied with 2 stab incisions. The tissue at the ruptured AT site is debrided which allows the tendon to be repaired with the double-Tsuge suture. Fu and Qu states that while the tendon is being sutured the ankle should be positioned at 30 degrees of plantar flexion.<sup>19</sup> The results of this study demonstrated that mini open repair when used with a double-Tsuge suture technique, can provide results that are as effective as one would find of an open repair technique. However, the

mini repair technique has less complications associated with it than does a typical open repair technique.<sup>19</sup> In comparing it to the patients who received open Kessler suture procedures, the patients who underwent the mini incision repair experienced an earlier ability to perform 20 continuous heel raises, smaller incision, and noticeably shorter time in the operating room. Finally, it should be noted that the breaking force by Tsuge sutures was found to have a much greater strength than the modified Kessler sutures used in the open procedure. Their strength allows for minimal gap resistance and less risk for re-rupture.

#### *Endoscopy Assisted Percutaneous Repair*

It is well known that the rate of tendon re-rupture is higher in percutaneous repairs than in open invasive repairs of the AT.<sup>17</sup> According to Chiu et al. some surgeons equate percutaneous procedures to be that of a blind technique due to not having a clear view of the operation like one would have in an open invasive procedure.<sup>17</sup> This blind hindrance is believed to lead to a less secure suturing of the AT stumps which then tends to lead to a AT re-rupture event. However, with the advent of endoscopy into the realm of percutaneous AT repairs there is hope that the surgeon may be able to have the precision that they are accustomed to when performing an open procedure. Endoscopy Assisted Percutaneous Repair offers the possibility to drastically improve percutaneous treatment of AT ruptures.

Chiu et al. used an endoscopy Assisted Percutaneous Repair with a modified Bunnell suture technique. The operative technique consists of using a knee arthroscope (30 degrees, 4.0 mm), arthroscopic shaver, radiofrequency electrode, arthroscopic grasp, bird beak, knot pusher, and No. 5 Ethibond. After marking the site of the AT tear, 8 stab wounds are made, with 4 located on each side of the AT to function as portals.<sup>17</sup> Then the severity of the AT tear is examined with the use of the endoscope which is placed through one of the portals nearest to the AT tear. During the entire surgery, endoscopy is used to ensure precise channeling of the Ethibond sutures.<sup>17</sup> In order to protect against a possible sural nerve injury, retractors are used when the suture is progressed from a medial to lateral direction. Once the sutures from both the distal stump and the proximal stump are passed through their respective portals, the sutures are tied using endoscopic examination.<sup>17</sup> The endoscopic tool allows for excellent approximation of the gap between the proximal and distal stumps and thereby allowing the surgeons to minimize the gap as precisely as possible. Chiu et al. found that this procedure not only had a lower rate of wound complications, but also a lower rate of re-rupture not only compared to open procedures but also to other percutaneous procedures.

Studies have shown that minimally invasive Achilles tendon repair compared with open wound repair have lower complication rates and improved cosmetic appearance.<sup>9</sup> Due to the complications associated with the open treatment protocol, many surgeons

have elected to follow the minimally invasive route which offers a decreased risk of developing infections. Though there are typically less complications with the minimally invasive protocol as compared to the open protocol of treatment, the most significant issue that plagues a percutaneous minimally invasive technique is the possibility of a sural nerve lesion.<sup>7</sup> It should also be noted that there is a higher rate of tendon re-rupture in patients undergoing percutaneous AT repair than the open repair.<sup>17</sup> Additionally, there is an increased cost factor with minimally invasive techniques as many have their own instruments that need to be purchased.

## CONCLUSION

Currently, there are many different surgical options in repairing an acute Achilles tendon rupture. There are different techniques and materials that have been presented in the literature. There are however, some potential limitations in this study. One limitation is that this study was not able to include all of the surgical options used in past and present for an Achilles tendon repair due to the study's exclusion criteria. A second limitation in this study was that the search terms Kessler or Bunnell or Krackow limited the results to papers that used one of these techniques or compared their technique to one of these techniques. Additionally, there is heterogeneity amidst the primary studies, most notably the use of cadavers rather than live patients in some primary studies. Due to these limitations, a definitive

cannot be made on which surgical option has more of an advantage than the rest. However, this study provides an overview of the different surgical techniques and surgical materials that can be used. This overview may be helpful in guiding the surgeon in deciding which surgical option is suitable for the repair of an acute Achilles tendon rupture.

## AUTHORS' CONTRIBUTION

The authors equally contributed to the production of this article.

## STATEMENTS OF COMPETING INTERESTS

The authors declare that they have no competing interests.

## REFERENCES

1. Villarreal AD, Anderson CR, Panchbhavi VK. A Survey on Management of Chronic Achilles Tendon Ruptures. *American Journal of Orthopaedics*. 2012;41(3): 126-31.
2. Lui TH. Surgical Tip: Repair of Acute Achilles Rupture With Krackow Suture Through a 1.5 cm Medial Wound. *Foot and Ankle Surgery*. 2010;16(1): 28-31: doi: 10.1016/j.fas.2009.04.004.
3. Labib SA, Hoffler CE 2nd, Shah JN, Rolf RH, Tingan A. The Gift Box Open Achilles Tendon Repair Method: A Restrospective Clinical Series. *Journal of Foot and Ankle Surgery*. 2016;55(1): 39-44. doi: 10.1053/j.jfas.2015.04.024.
4. Sadoghi P, Rosso C, Valderrabano V, Leithner A, Vavken P. Initial Achilles Tendon Repair Strength- Synthesized Biomechanical Data From 196 Cadaver Repairs. *International Orthopaedics*. 2012;36(9): 1947-51: doi: 10.1007/s00264-012-1533-6.
5. Ding WG, Li H, Zhu YP, Liu ZW. Comparison Between Tenocutaneous Suture and Kessler Suture Techniques in Treating Acute Closed Achilles Tendon Rupture. *Foot and Ankle Surgery*. 2014;20(2): 105-108: doi: 10.1016/j.fas.2013.12.007.
6. Berlet GC, Hyer CF, Lee TH, Blum BE. Collagen Ribbon Augmentation of Achilles Tendon Tears: A Biomechanical Evaluation. *Journal of Foot and Ankle Surgery*. 2014;53(3): 298-302.
7. Chen H, Ji X, Zhang Q, Liang X, Tang P. Channel-Assisted Minimally Invasive Repair of Acute Achilles Tendon Rupture. *Journal of Orthopaedic Surgery and Research*. 2015;10: 167. doi:10.1186/s13018-015-0310-9.
8. McCoy BW, Haddad SL. The Strength of Achilles Tendon Repair: A Comparison of Three Suture Techniques in Human Cadaver Tendons. *Foot and Ankle International*. 2010;31(8): 701-5: doi: 10.3113/FAI.2010.0701.
9. Hsu AR, Jones CP, Cohen BE, Davis WH, Ellington JK, Anderson RB. Clinical Outcomes and Complications of Percutaneous Achilles Repair System Versus Open Technique for Acute Achilles Tendon Ruptures. *Foot and Ankle International*. 2015;36(11): 1279-86.

10. Hong Y, Hermida L, White KL, Parks BG, Carmire LM, Guyton C. Core Weave Versus Krackow Technique for Achilles Tendon Repair: A Biomechanical study. *Foot and Ankle International*. 2010;31(11): 1006-13: doi: 10.3113/FAI.2010.1107.
11. Kanz BN, Morris RP, Lewis T, Panchbhavi VK. Biomechanical Evaluation of a Knotless Barbed Suture Repair in a Human Achilles Tendon Rupture Model. *Foot and Ankle Specialist*. 2014;7(3): 176-81. doi: 10.1016/j.surge.2014.03.010.
12. Cook KD, Clark G, Lui E, Vajaria G, Wallace GF. Strength of Braided Polyblend Polyethylene Sutures Versus Braided Polyester Sutures in Achilles Tendon Repair: A Cadaveric Study. *Journal of American Podiatric Medical Association*. 2010;100(3): 185-88.
13. Gnanth RJ, Smith JL, Nguyen-Ta K, McDonald L, LeClere LE. High-Tensile Strength Tape Versus High-Tensile Strength Suture: A Biomechanical Study. *Arthroscopy*. 2016;32(2): 356-63. 10.1016/j.arthro.2015.08.013.
14. Wisbeck JM, Parks BG, Schon LC. Xenograft Scaffold Full-Wrap Reinforcement of Krackow Achilles Tendon Repair. *Orthopaedics*. 2012;35(3): 331-34. doi: 10.3928/01477447-20120222-41.
15. Magnussen RA, Glisson RR, Moorman CT 3rd. Augmentation of Achilles Tendon Repair With Extracellular Matrix Xenograft: A Biomechanical Analysis. *American Journal of Sports Medicine*. 2011; 39(7): 1522-27.
16. Hegewald KW, Doyle MD, Todd NM, Rush SM. Minimally Invasive Approach to Achilles Tendon Pathology. *Journal of Foot and Ankle Surgery*. 2016;55(1): 166-68. doi: 10.1053/j.jfas.2015.08.001.
17. Chiu CH, Yeh WL, Tsai MC, Chang SS, Hsu KY, Chan YS. Endoscopy-Assisted Percutaneous Repair of Acute Achilles Tendon Tears. *Foot and Ankle International*. 2013; 34(8):1168-76.
18. Heitman De, Ng K, Crivello KM, Gallina J. Biomechanical Comparison of the Achillon Tendon Repair System and the Krackow Locking Loop Technique. *Foot and Ankle International*. 2011;32(9): 1522-27.
19. Fu C, Qu W. Acute Achilles Tendon Rupture: Mini-Incision Repair With Double-Tsuge Loop Suture Vs. Open Repair With Modified Kessler Suture. *Surgeon*. 2015;13(4): 207-12 : doi: 10.1016/j.surge.2014.03.010.

# Surgical Correction of Bilateral Postaxial Polydactyly in a Six-Year-Old Female with Polydactyly of the Hands and Feet: A Case Report and Literature Review

Victoria Solomon, BA, Joseph Waterhouse, BS & Asher Wiederkehr, BS

## Abstract

### Introduction

Polydactyly is an abnormality characterized by the presence of extra fingers or toes. This condition may be inherited by itself or as part of a syndrome. When inherited alone, polydactyly typically demonstrates autosomal dominant inheritance.

### Case Presentation

This case report describes a six-year-old female who presented with bilateral postaxial polydactyly of the hands and feet, a rare occurrence. Radiographs demonstrated a sixth metatarsal, which split from the fifth metatarsal bilaterally. Surgical removal of the supernumerary digits included disarticulation of the sixth digit bilaterally at the level of the metatarsophalangeal joint. Fluoroscopy and a sagittal saw were used to resect the accessory metatarsal.

### Conclusion

This case demonstrated successful surgical correction of bilateral postaxial polydactyly, which was most likely the result of a mutated gene passed through autosomal dominant inheritance.

**Key Words:** polydactyly, postaxial, supernumerary digit, congenital foot abnormality

*Levels of Evidence: 5*

## INTRODUCTION

Polydactyly is a congenital deformity with the presentation of supernumerary digits. This condition is the most common congenital digital deformity in children.<sup>1,2</sup> Polydactyly most commonly presents as part of a syndrome involving other congenital abnormalities.<sup>3</sup> An isolated polydactyly without other syndrome features is primarily a result of a genetically inherited autosomal dominant trait.<sup>3</sup> The correction of supernumerary digits is often achieved by surgical intervention, and is commonly performed when the child is about one year in age.<sup>3</sup>

Syndromes which commonly include postaxial polydactyly are the following: Bardet-Biedl, Ellis van Creveld, Meckel, McKusick-Kaufman, and Greig cephalopolysyndactyly syndrome. Bardet-Biedl is characterized by rod-cone dystrophy, postaxial polydactyly, central obesity, mental retardation, hypogonadism and renal dysfunction.<sup>4</sup> In addition to postaxial polydactyly, Ellis van Creveld presents with short ribs, growth retardation and ectodermal and cardiac defects.<sup>5</sup> Meckel syndrome has three characteristic findings: encephalocele, polycystic kidneys and polydactyly.<sup>6</sup> Postaxial polydactyly can occur with McKusick-Kaufman syndrome, which also causes hydrometrocolpos.<sup>7</sup> Greig

cephalopolysyndactyly syndrome is characterized by preaxial or mixed preaxial and postaxial polydactyly with or without syndactyly and craniofacial features including hypertelorism and macrocephaly.<sup>8</sup> All of these syndromes are rare in the general population and some are found in only certain populations, such as McKusick-Kaufman found in the Amish community.<sup>9</sup> These syndromes are inherited in an autosomal recessive pattern, except for Greig cephalopolysyndactyly which is inherited in an autosomal dominant pattern.<sup>9</sup>

Although polydactyly is not uncommon, it is rare to have bilateral polydactyly of both the feet and hands. There have been cases reported of incidental findings of bilateral polydactyly of the feet and hands in the literature both with and without any other congenital abnormalities. One case was entirely incidental following a chief complaint of acne, while another followed a cadaveric observation of polydactyly with renal vascular abnormalities.<sup>10,11</sup>

Multiple classification systems of polydactyly exist, but no single system has gained universal recognition. Perhaps the most complete morphological organization has been put forth by Hiroyuki Watanabe, M.D. who analyzed 330 feet in Japan.<sup>12</sup> Watanabe describes

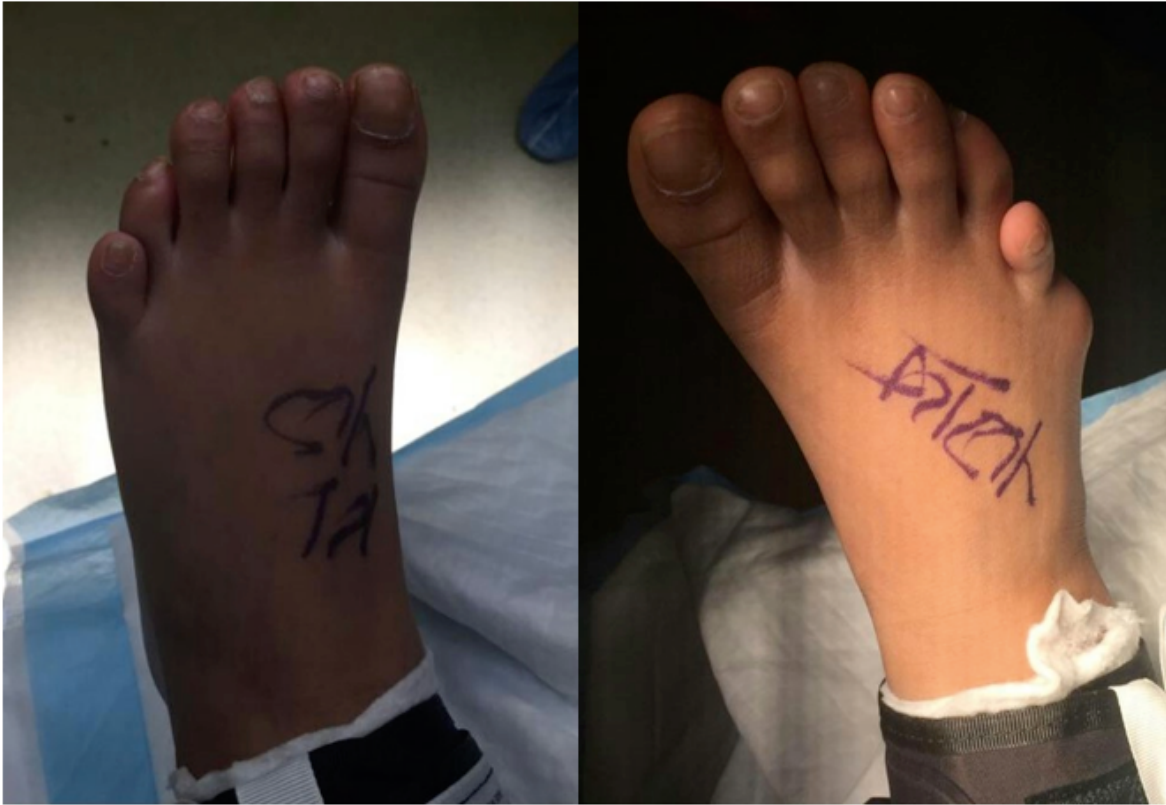ray or pre-axial, central, and lateral ray or postaxial.<sup>12</sup> Anatomic differences in bony structures according to x-ray and operative findings, external appearances, associated anomalies, and familial incidence were studied.<sup>12</sup> The goal was to classify the different morphological patterns of polydactyly based on ray involvement and the level of duplication.<sup>12</sup> Watanabe described five levels of duplication either being at the tarsal, metatarsal, proximal phalangeal, middle phalangeal, or distal phalangeal level.<sup>12</sup> Within those categories, the morphologic pattern is described.<sup>12</sup> Lateral ray polydactyly was by far the most common and was further classified into two major categories; fifth ray duplication (a medially duplicated supernumerary toe) or a sixth ray duplication (a laterally duplicated sixth toe).<sup>12</sup>

A more recent (2013) classification of polydactyly of the foot has been proposed recently by Seok et al, which is based on syndactylism (S), axis deviation (A), metatarsal extension (M) and the numbers 0-2.<sup>13</sup> Syndactylism: S<sub>0</sub> is simple polydactyly with no involvement of the adjacent digit, S<sub>1</sub> involves less than half the adjacent digit with incomplete syndactyly and S<sub>3</sub> involves greater than half the digit length or complete syndactylism.<sup>13</sup> Angulation: A<sub>0</sub> - less than 15 degrees of axis

deviation from the toe is to be preserved.<sup>13</sup> A<sub>1</sub> - 15-30 degrees of axis deviation from the toe that is to be preserved.<sup>13</sup> A<sub>2</sub> - Angulation greater than 30 degrees.<sup>13</sup> Metatarsal involvement: M<sub>0</sub> - no metatarsal involvement.<sup>13</sup> M<sub>1</sub> - Broad-headed metatarsal bone with no shaft duplication.<sup>13</sup> M<sub>2</sub>- Y-shaped metatarsal bone or complete duplication of the metatarsal bone.<sup>13</sup> After reviewing 532 cases of polydactyly in 431 patients, Seok et al found that the most common anatomical pattern was S<sub>1</sub>A<sub>0</sub>-A<sub>1</sub>M<sub>0</sub>-M<sub>1</sub> type.<sup>13</sup> Syndactylism reflects the requirement and extent of a skin graft.<sup>13</sup> Axis deviation predicts the need for a wedge osteotomy and metatarsal extension describes the morphology of the bone, guiding the choice and approach of the surgical procedure.<sup>13</sup>

## Case Presentation

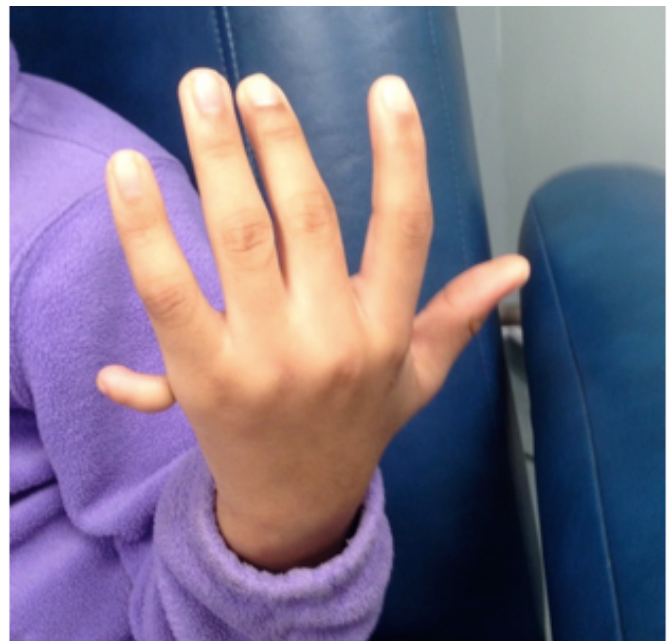The patient in this case report is a six-year-old female that presented with a history of lateral forefoot pain bilaterally. The patient presented with six digits bilaterally of the feet, and had a history of six digits in the hands bilaterally. The patient was born full term with normal developmental milestones. The neurovascular and biomechanical examinations were unremarkable and within normal limits. The patient's siblings were not born with any extra digits, but the



**Figure 1** – Image showing pre-operative bilateral postaxial polydactyly in six-year-old patient.

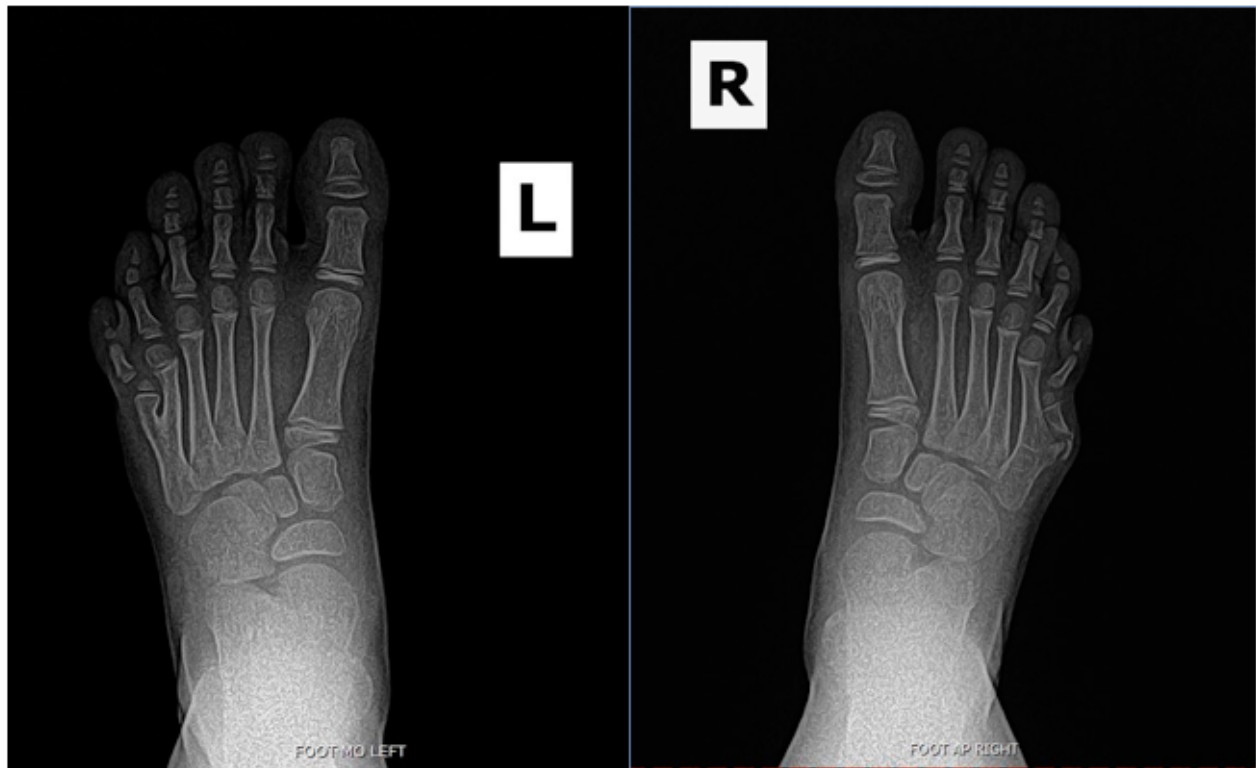father had a history of bilateral polydactyly. The right hand's sixth digit was surgically removed when the patient was seven months old, and the left hand's sixth digit is still present. There were no other treatments performed for the supernumerary digits at the time of the initial visit.

Radiographs were ordered for the patient and revealed postaxial polydactyly bilaterally. The sixth metatarsal split from the fifth metatarsal bilaterally. On the right foot, the sixth metatarsal appeared fragmented, and on the left foot the sixth metatarsal appeared intact and was shorter than the fifth metatarsal.



**Figure 2** – Image showing the remaining sixth postaxial digit of the left hand.

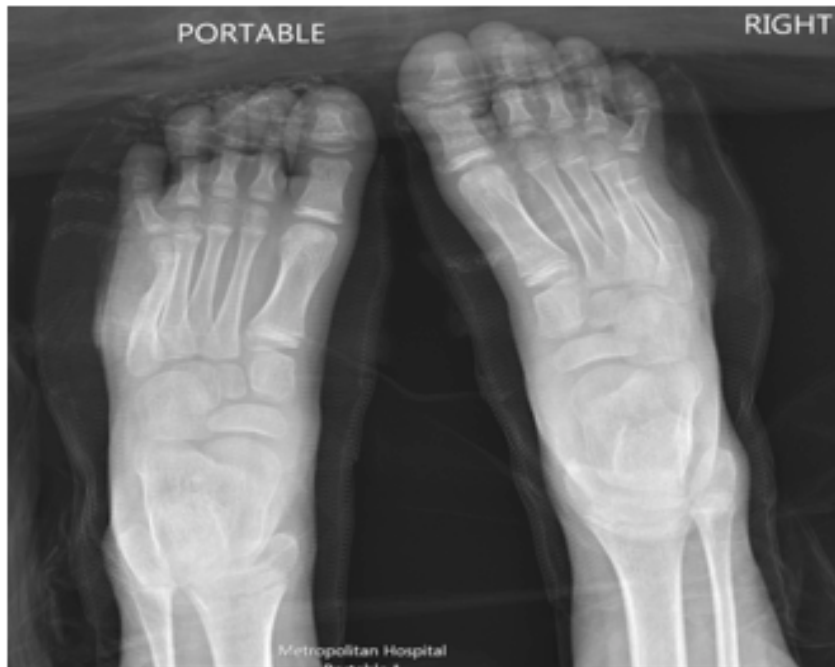



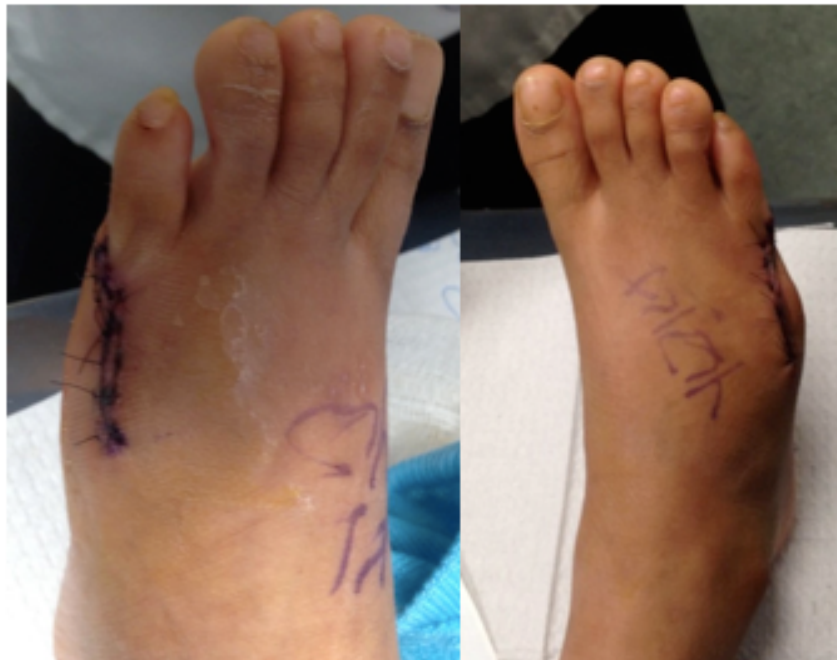**Figure 3** – Pre-operative radiographs of bilateral postaxial polydactyly of the six-year-old female patient. The right accessory metatarsal has a fragmented appearance as opposed to the intact appearance of the left.

The patient was scheduled for surgery with the goal of resecting the supernumerary digits and metatarsals bilaterally. General anesthesia was utilized for the procedure and an ankle tourniquet was used for hemostasis. Beginning with the right foot, a racket shaped incision was made around the supernumerary digit lateral to the fifth digit and this incision was extended proximally along the accessory metatarsal bone. The sixth digit was disarticulated at the level of the metatarsophalangeal joint. Using fluoroscopy and a sagittal saw, the accessory metatarsal was then resected. Fluoroscopy confirmed a rectus alignment of the fifth ray and ensured complete resection of the

sixth digit and metatarsal. Irrigation was performed with sterile saline. The deep layer was re-approximated with 4-0 Vicryl and the skin edge was re-approximated with 4-0 Nylon using the horizontal mattress technique. The same procedure was repeated on the left foot. Standard post-operative dressing was used for the patient, including betadine soaked Adaptic, 4 x 4 gauze, Kerlix, Webril and ACE bandage. The patient received a post-operative injection of 10 cc of 0.5% Naropin plain.



**Figure 4 – Post-operative radiographs following surgical resection of sixth digits and accessory metatarsals.**



**Figure 5 – Post-operative images following surgical resection of sixth digits and accessory metatarsals.**

One week post-operatively the surgical sutures were intact, and the incision sites were well coated, with no clinical signs of infection or drainage. The patient was compliant in decreasing the amount of weight-bearing, ambulating only in a surgical shoe. The only complaint was post-operative edema which was present during the first and second post-operative visits. The sutures were removed at two weeks, and the patient was instructed to remain in the surgical shoe for a third week, after which she could wear regular shoe gear. The patient will continue to be seen for follow-up.

## DISCUSSION

Polydactyly of the hands and feet bilaterally is a rare congenital deformity. In this case, classifying the type of polydactyly was important in surgical planning. According to Watanabe's classification scheme this patient had bilateral postaxial polydactyly.<sup>12</sup>

The decision to surgically remove the lateral digits resulted from radiographic analysis, as well as morphologic and clinical examination of the supernumerary digits. The sixth digits were found to be less functional, and the cause of the chief complaint. Thus, they were resected. Intraoperatively it was important to consider the presence of neurovascular structures and the

presence of any accessory tendons, which were not present.

Although the surgical procedure to correct polydactyly is not extremely complicated, a physician must consider the presence of coexisting congenital deformities that may imply the presence of a syndrome. Based on the physical exam and the absence of gross physical or mental abnormalities of this child, a syndrome was not considered to be the primary etiology. The patient's father had a history of bilateral polydactyly and although it was not disclosed if this was of both the hands and feet like the daughter, it strengthens the case for an isolated polydactyly. This would indicate that the isolated polydactyly was most likely the result of an autosomal dominant inheritance pattern.

The patient continues to be followed with the hopes of a functional and comfortable recovery.

## CONCLUSION

A six-year-old female presented with a history of bilateral postaxial polydactyly of the hands and feet. Due to the family history and the absence of any other physical abnormalities, this presentation was most likely due to the inheritance of a mutated gene with an autosomal dominant inheritance pattern. The patient was experiencing lateral foot pain and problems with shoe gear due to the

supernumerary digits. The surgical treatment plan included disarticulation of the sixth digits at the level of the metatarsophalangeal joints and removal of the accessory metatarsals under the guidance of fluoroscopy. Successful surgical correction was achieved with minimal post-operative complications.

## REFERENCES

1. Chakraborty PB, Marjit B, Dutta S, De A. Polydactyly: A Case Study. *J. Anat. Soc. India* 56.1 (2007): 35-38. Web.
2. Park, GH, Jung ST. Toe Component Excision in Postaxial Polydactyly of the Foot. *Foot & Ankle International* 34.4 (April 2013): 563-67. Web.
3. Polydactyly and Syndactyly. Polydactyly and Syndactyly. Penn State Milton S. Hershey Medical Center, 2006. Web.
4. Madireddi J, Vasuveda A, Jandhyala S, Handattu M H, Shetty R. Bardet-Biedl Syndrome: Multiple Fingers with Multiple Defects!. *BMJ Case Reports* (2015): n. pag. Web.
5. Jayaraj D, Maheswaran T, Suresh R, Ganapathy N. Ellisvan Creveld. *Journal of Pharmacy and Bioallied Sciences J Pharm Bioall Sci* 4.2 (2012): 153-56. Web.
6. Aslan K, K ulahçı Aslan E, Orhan A, Atalay MA. Meckel Gruber Syndrome, A Case Report. *Organogenesis* 11.2 (2015): 87-92. Web.
7. Tsai HF, Wu MH, Cheng YC, Chang CH, Chang FM. Prenatal Ultrasonography and Postnatal Follow-up of a Case of McKusick-Kaufman Syndrome. *Taiwanese Journal of Obstetrics and Gynecology* 53.2 (2014): 241-44. Web.
8. Tanteles GA, Michaelidou S, Loukianou E, Christophidou-Anastasiadou V, Kleopa KA. Novel GLI3 Mutation in a Greek-Cypriot Patient with Greig Cephalopolysyndactyly Syndrome. *Clinical Dysmorphology* 24.3 (2015): 102-05. Web.
9. Genetics Home Reference. Your Guide to Understanding Genetic Conditions. U.S. National Library of Medicine, 28 Mar. 2016. Web. 30 Mar. 2016.
10. Kapoor R, Johnson R. Polydactyly — NEJM. *New England Journal of Medicine*. New England Journal of Medicine, 2011. Web.
11. Gesase AP. Bilateral Hands and Feet Postaxial Polydactyly Presenting with Renal Vascular Anomalies. Department of Anatomy/Histology Muhimbili University College of Health Sciences. *Ital J AnatEmbryol*, 2006. Web.
12. Watanabe H, Fujita S, Oka I. Polydactyly of the Foot. *Plastic and Reconstructive Surgery* 89.5 (1992): 856-77. Web.
13. Seok H H, Park JU, Kwon ST. New Classification of Polydactyly of the Foot on the Basis of Syndactylism, Axis Deviation, and Metatarsal Extent of Extra Digit. *Arch PlastSurg Archives of Plastic Surgery* 40.3 (2013): 232. Web.

# Current Surgical Interventions in the Treatment of Symptomatic Type II Accessory Navicular: A Literature Review

*Brittany Hervey, BS, Kevin Yee, BA, & Grace Tsai, BSN*

## Abstract

### Introduction

The purpose of this study is to compare surgical techniques that are used to treat a symptomatic type II accessory navicular. Current literature indicates there are many different procedures available, however, not one is considered the gold standard. In this literature review, we discuss and compare alternatives to the traditional Kidner procedure for the treatment of symptomatic type II accessory navicular such as simple excision, percutaneous drilling, arthrodesis, and reconstructive surgery using interface screws.

**Study design:** Qualitative Systemic Review of the Literature

### Methods

An English language literature search was performed using PubMed. The inclusion criteria were human subjects with painful accessory navicular type II that needed surgical interventions. Exclusion criteria were accessory navicular type I and accessory navicular type III, conservative management, cadaveric studies, non-English articles, and articles published prior to 2005.

### Results

In this literature review we discuss alternative surgical techniques to the Kidner procedure for the treatment of symptomatic type II accessory navicular. We evaluate percutaneous drilling, simple excision of the accessory ossicle, reconstructive surgery with interface screw fixation and arthrodesis with respect to healing times, surgical outcomes, pain improvement and time to return to activity. The results of this study demonstrate that each technique has specific anatomic and radiographic indications.

### Discussion and Conclusion

While the modified Kidner is the most widely accepted surgical procedure for the correction of painful type II accessory navicular, it has several limitations. Transposition of the posterior tibial tendon is implicated in the gradual decline in the dynamic support of the medial longitudinal arch post-operatively. In this paper, we discuss procedures described in the literature that place emphasis on maintaining the tendon insertion to preserve the normal biomechanical relationship of the tendon to the medial arch. We discuss percutaneous drilling, accessory navicular arthrodesis, and modified simple excision as alternative procedures that relieve symptoms related to painful type II accessory navicular without disrupting normal arch biomechanics.

**Key Words:** Type III accessory navicular, symptomatic, surgical interventions

*Levels of Evidence: 4*

## INTRODUCTION

An accessory navicular is a congenital anomaly that occurs when a secondary ossification center develops off of the true navicular and the two bones do not fuse to become one. The incidence of an accessory navicular has been reported approximately 14%.<sup>1,2,3</sup> It has been suggested that accessory navicular has an autosomal dominant inheritance.<sup>2</sup> One study suggests that females are more predisposed to being diagnosed with an accessory navicular.<sup>3</sup> When the secondary ossification center that develops off the tuberosity of the navicular does not fuse with the navicular, the two ossicles are left with a fibrocartilaginous interface.<sup>1</sup> The tension due to activity at the fibrocartilaginous interface can cause pain. The most common symptom associated with accessory navicular is medial foot pain that is exacerbated by walking, exercise, sports or trauma such as an eversion injury.<sup>1-5</sup>

Normally, the posterior tibialis tendon (PTT) would insert on the plantar surface of the navicular; however, with an accessory navicular, the fibers of the tendon surround the smaller osseous structure or inserts into it.<sup>6</sup> There are three types of accessory naviculars as described by Micheli et al. Type I is a pea-shaped sesamoid bone within the tendon and completely separate from the true

navicular. Type II is where the accessory and true navicular are connected by a fibrous or fibrocartilaginous connection and a portion of the PTT inserts into it. Type III is described as gorilloid or cornuate because the two bones are connected and become a very prominent structure on the medial side of the midfoot. The type II accessory navicular is the most likely to be symptomatic due to constant shear stress at the synchondrosis brought on by tension from the PTT.<sup>1,7,8</sup>

The initial treatment of choice for symptomatic type II accessory navicular is usually non-operative. Commonly used conservative treatments include rest, nonsteroidal anti-inflammatory medications, periods of immobilization with casting, bracing, CAM boot, orthotics, or activity modification.<sup>1-7</sup> Over the years, there have been several surgical procedures used for the relief of a symptomatic type II accessory navicular. However, no gold standard has emerged.<sup>5</sup> Surgeons have attempted several different types of procedures to relieve the symptomatic type II accessory naviculars including simple excision, percutaneous drilling, modified Kidner, and arthrodesis. A simple excision of the accessory navicular is one way to alleviate the pain caused by the two ossicles with a fibrous or cartilaginous gap. One method described was to split the PTT

longitudinally down the middle, which preserved the insertion of the tendon, and then remove the accessory bone via sharp dissection.<sup>7</sup> A minimally invasive procedure has also been proposed that utilizes percutaneous drilling of the synchondrosis between the two bones through the skin. Microbleeding caused by the drilling of the fibrocartilaginous gap is thought to promote a bony union between the true and accessory navicular bones.<sup>4</sup> It is considered less invasive and more effective for skeletally immature individuals.<sup>5</sup> Arthrodesis is a procedure in which the tissue between the true navicular and the accessory navicular is identified and two sections are removed via sharp resection. Fusion is achieved by creating a divot on the plantar aspect of the true navicular and advancement of the accessory navicular into the divot then fixate with one or more screws.<sup>2</sup> Miyamoto et al introduced a new technique where the PTT is reattached through a bone tunnel with use of an interference screw. The stripped PTT is pulled through the tunnel by thread and guidewire and then fixated with an interference screw.

The most commonly performed procedure for symptomatic type II accessory navicular is the modified Kidner Procedure. This technique involves excision of the accessory

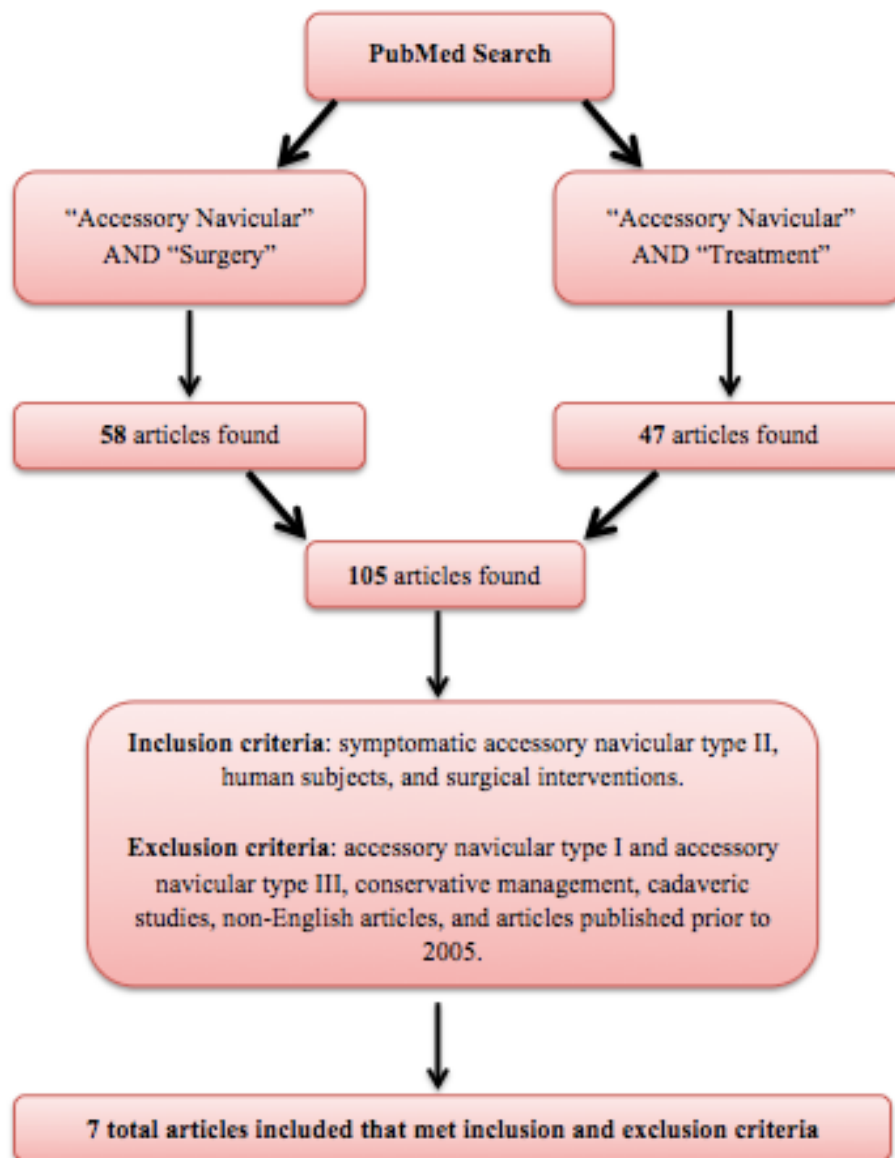
navicular and repositioning the attachment of the PTT to the plantar surface of the navicular.<sup>6</sup> Many surgeons believe that the PTT is a dynamic stabilizer of the medial arch and a strong inverter, thus much emphasis has been placed on how to preserve the PTT when reattaching.<sup>5</sup> Therefore, many modifications to the original procedure have been proposed with the intent to preserve the posterior tibial tendon. In this systematic review of the literature, we discuss current surgical interventions and compare clinical outcomes in the treatment of symptomatic type II accessory navicular.

## METHOD

Two English language literature searches were performed using the PubMed database. The search was performed using the “and” Boolean operator. The first search included the terms “accessory navicular” AND “surgery”, which yielded 58 articles. The second search included the terms “accessory navicular” AND “treatment”, which yielded 47 articles. Overall, the two searches resulted in 105 total articles. The inclusion criteria consisted of human subjects with painful accessory navicular type II that needed surgical interventions. Exclusion criteria were accessory navicular type I and accessory navicular type III, conservative

management, cadaveric studies, non-English articles, and articles published prior to 2005. After evaluating and screening the papers using the inclusion and exclusion criteria mentioned above, seven papers matched the criteria and were analyzed for purposes of this paper.

The search methods have been summarized in Figure 1.



**Figure 1:** Acquisition of articles from PubMed based on inclusion and exclusion criteria.



## RESULTS

### *Percutaneous Drilling*

Nakayama et al. treated 31 feet of 29 patients (15 males and 14 females) that had symptomatic type II accessory naviculars with the main complaint of pain at the medial aspect of the foot during or after exercise.<sup>4</sup> Of the 29 symptomatic patients, 11 patients had a sprain of the foot; seven suffered contusion to the foot; and the remaining 11 denied a history of trauma preceding the onset of pain. All patients underwent conservative treatment for at least two months with no improvement before undergoing percutaneous treatment.<sup>4</sup>

The percutaneous treatment involved the drilling of the fibrocartilaginous layer with subsequent microbleeding to promote bony union between the primary and accessory navicular bones.<sup>4</sup> The procedure involved percutaneous insertion of a 1.0mm Kirschner wire through the navicular synchondrosis at five to seven different points under the guidance of radiographic fluoroscopy. The orientation of the Kirschner wire was advanced from the posterior aspect of the prominence on the accessory navicular through the true navicular. Following the procedure, the foot was immobilized for three weeks with a below-the-knee cast in an equinovarus position. Patients returned to full activity two months post-operation.<sup>4</sup>

Patients were rated based on the time it took for them to return to full sports activities. Excellent meant return to full sports activities and no complaints of symptoms less than three months post-operation. If the return to activities was three to six months after the operation, then they were rated as good. If it was more than six months than it was rated as fair, and those with worsened symptoms were rated as poor. Twenty-four feet (77.4%) were rated as excellent, six (19.4%) as good, and one (3.2%) as fair.<sup>4</sup> There were no poor ratings in this study.

Bone union after percutaneous drilling procedure was confirmed with plain radiographs in 18 of the 31 feet (58%), with 13 feet showing non-unions (42%).<sup>4</sup> Bone union was achieved in 80% (16 out of 20 patients) of patients with open epiphyseal plates compared to 22% (two out of nine patients) of those patients who displayed radiographic evidence of skeletal maturity. Statistical significance was noted in bone union rate between patients with and without mature bone ( $P=0.001354$ ).<sup>4</sup>

### *Modified Simple Excision*

Micheli et al. introduced the modified simple excision of the accessory navicular with naviculoplasty.<sup>6</sup> The procedure was described as blunt dissection to expose the entire navicular, insertion of posterior tibial

tendon, and the symptomatic accessory ossicle. Parallel incisions were made at the superior and inferior margins of the posterior tibial tendons, taking care not to completely sever the tendon. The remaining proximal and distal longitudinal fibers were left attached to create a periosteal flap. The accessory ossicle, commonly located at the central third of the posterior tibial tendon, was excised with the use of a Rongeur and osteotome. A naviculoplasty was usually performed to ensure a smooth contour of the medial margin of the navicular and any remaining bony prominences. The two edges of the periosteal flap created by the posterior tibial tendon were then reapproximated with suture, ensuring that the tendon is sutured inferior to the body of the navicular.<sup>6</sup>

Following the procedure, the patient is immobilized for four weeks in a short leg walking boot or short leg cast. After four weeks of immobilization, physical therapy is initiated for strength and proprioception training. Patients continued in a walking boot while doing physical therapy. At 12 weeks postoperatively, patients are able to resume sports and other activities. The average postoperative follow-up was 7.2 years (ranged from 18 months to 12 years).<sup>6</sup> Patients were interviewed over the phone postoperatively and graded their results following removal of accessory

navicular as excellent, good, fair, or poor. The grading was based on returning to desired activities, shoe wear modifications, and pain relief. Excellent was defined as a painless foot and no shoe wear modifications. A good rating signified painless foot, mild fatigue, and shoe wear modifications. Fair was mild foot pain with activity, mild restriction of activity, mild to moderate fatigue, and shoe wear modifications.<sup>6</sup> Lastly, poor was moderate foot pain, restriction of activity, and shoe wear modification. All patients reported improvement of their symptoms, 11 feet reports as excellent and two reported as good. The use of the modified simple excision for symptomatic accessory navicular was to keep the posterior tibial tendon insertion intact and to redirect the mechanical forces asserted by the posterior tibial tendon.<sup>6</sup>

### ***Reconstructive surgery using interface screw fixation***

An innovative procedure to reattach the posterior tibial tendon through a bone tunnel using interface screw fixation was introduced by Miyamoto et al.<sup>5</sup> The study suggested that this procedure achieved anatomical reconstruction of bone-tendon interface of the posterior tibial tendon into the navicular.<sup>5</sup> Ten adult athletes, aged 23 to 45 years old (mean age was 30 years old), with symptomatic

accessory naviculars underwent this procedure after three months of failed conservative treatment.

### ***Modified Simple Excision***

Micheli et al. introduced the modified simple excision of the accessory navicular with naviculoplasty.<sup>6</sup> The procedure was described as blunt dissection to expose the entire navicular, insertion of posterior tibial

A 4-cm incision was made over the accessory navicular to expose the posterior tibial tendon and accessory navicular. The accessory navicular was gently excised from the posterior tibial tendon. If prominence was noted on the medial aspect of the primary navicular, then trimming could be achieved with Rongeur and chisel. Next, a guidewire was placed from plantar-medial at navicular through the skin on the dorsal-lateral aspect of the navicular. The guidewire would be perpendicular to the lever arm of the posterior tibial tendon in order prevent fixation failure due to the traction force of the posterior tibial tendon.<sup>5</sup> The position of the guidewire was visualized with fluoroscopy. Once confirmed, a bone tunnel was created by over-drilling the medial aspect of the navicular along the guidewire to approximately 20mm deep with a cancellous bone harvesting drill with a diameter of 5.5mm.<sup>5</sup> The posterior tibial tendon was pulled through the bone tunnel with a pierced guidewire

to the dorsolateral aspect of the navicular. A 5.0mm interface screw was used to fixate the tendon, with pieces of cancellous bone obtained from the harvesting drill in between the screw and tendon. When fixating, the ankle would be 20° plantarflexed with the hindfoot in neutral position. For one week, the patient was in a splint that would allow active and passive range of motion. At two weeks postoperative, partial weight bearing was allowed. After four weeks, patients could weight bear without crutches. All patients returned to full sports activity at an average of 14 weeks post-operation (range 12-18 weeks).

The average AOFAS score improved from 62.8 +/- 2.9 points (range 61-82) to 92.1 +/- 7.0 points (range 83-100), preoperative and postoperative respectively. On the VAS, the score improved from a preoperative 92.5 +/- 5.4 points (range 85-100,  $p < 0.01$ ) to a postoperative 4.5 +/- 3.8 points (range 0-10,  $p < 0.01$ ).

### ***Arthrodesis of Symptomatic Accessory Navicular Ossicle to Primary Navicular***

Scott et al. conducted a study on arthrodesis of the symptomatic accessory navicular ossicle to the primary navicular. The study included 20 patients with an average age of 25 years (the full range was 10-52 years old) that would either undergo the

modified Kidner procedure (ten feet) or arthrodesis (ten feet) based on intraoperative impression of accessory navicular size.

A 4-cm incision was placed over the accessory navicular and insertion of the posterior tibial tendon. The size of each accessory ossicle was evaluated to determine if the bone was large enough to accommodate a 3.5mm cannulated lag screw. If the ossicle was deemed large enough to be properly placed without fragmenting, an arthrodesis was performed. If it was too small for the screw, then a modified Kidner procedure was done. Ten patients underwent the arthrodesis. The soft tissue between the accessory bone and primary navicular was resected to expose the lateral aspect of the accessory navicular and navicular tuberosity.<sup>2</sup> The two adjacent surfaces were resected with a sagittal bone saw. A divot was created with a curette on the distal plantar aspect of the primary navicular for the accessory bone. At least one 3.5mm cannulated lag screw was utilized for internal fixation. All patients were in a non-weightbearing short leg cast for 6 weeks postoperatively. Radiographs were taken and reviewed after 6 weeks to evaluate healing progress. If deemed adequate then the patient was placed in a CAM walker.<sup>2</sup>

The average postoperative follow up was shorter for the arthrodesis group (average: 35 months, full range: 21-71 months) compared to the modified Kidner group (average: 48 months, full range: 24-68 months). The average AOFAS Midfoot score of the arthrodesis group improved from 50 points (range 18-67) to 93 points (range 81 to 100), preoperative and postoperative respectively. The average AOFAS Midfoot score of the modified Kidner group was 52 points (range 41 to 67) preoperatively and 80 points (range 52 to 100) postoperatively. However, there was no significant difference between the AOFAS Midfoot scores of the two groups ( $p > 0.05$ ).<sup>2</sup>

	<b>Percutaneous Drilling</b>	<b>Modified Simple Excision</b>	<b>Reconstructive Surgery Using Interface Screw Fixation</b>	<b>Arthrodesis</b>
<b>Authors</b>	Nakayma et al.	Micheli et al.	Miyamoto et al.	Scott et al.
<b>Sample size</b>	31 feet (29 patients)	13 feet (10 patients)	10 feet (10 patients)	20 feet (20 patients) (Arthrodesis group: 10 feet, Modified Kidner group: 10 feet)
<b>Sex</b>	15 males and 14 females	3 males and 7 females	7 males and 3 females	11 males and 9 females
<b>Mean Age</b>	13 years (range, 10-18 years)	13.5 years	30 years (range 23-45 years)	25 years (range, 10-52 years)
<b>Average healing time</b>	11 weeks for bone union (range, 6-24 weeks)	N/A	N/A	N/A
<b>Average return to full activity time</b>	2 months	12 weeks	14 weeks	12 weeks
<b>Postoperative grading</b>	23 patients as excellent, 5 patients as good, 1 patient as fair	11 patient with excellent results, 2 with good results	<b>Mean AOFAS score:</b> preoperative was 62.8+/- 2.9 points, postoperative 92.1+/-7.0 points <b>Mean VAS score:</b> preoperative 92.5+/- 5.4 points, postoperative 4.5 +/- 3.8 points	<b>Arthrodesis group:</b> AOFAS (pre-op was 50, post-op was 93) <b>Modified Kidner group:</b> AOFAS (pre-op was 52, post-op was 80)
<b>Postoperative follow-up</b>	2 years and 8 months (24-37 months)	7.2 years (18 months to 12 years)	30 months (24-39 months)	<b>Arthrodesis group:</b> 35 months (range, 21 to 71 months) <b>Modified Kidner group:</b> 48 months (range, 24 to 68 months)

**Table 1:** Summary of Studies and Results.

## DISCUSSION

### *Percutaneous Drilling*

Recurrent stress at the synchondrosis between the type II accessory navicular and the medial navicular tuberosity is implicated in the development of symptoms. Trauma, arthritic changes, as well as tension and shearing forces from the pull of the tibialis posterior muscle are all sources of stress and subsequent pain at the synchondrosis.<sup>8</sup> It is reported that when bone union is achieved between the accessory and primary navicular bones that symptoms may resolve spontaneously in the course of osseous development in young patients. However, natural union between the two bones occurs infrequently at a rate of 10 to 14% as reported by Miyamoto et al., especially in the young athletic population.<sup>5</sup> In their study, the authors hypothesized that percutaneous drilling of the fibrocartilaginous barrier between the primary navicular and the accessory ossicle would induce microbleeding at the synchondrosis.<sup>5</sup> Microbleeding in turn stimulates bone marrow cells to release cytokines, which are thought to accelerate osseous union between the two bones.<sup>4</sup>

The authors sought to compare the rate of bone union between their study populations to that of the general population. Bone union was achieved

within six months post-operatively in 80% (16 out of 20) of patients with open epiphyseal plates compared to 22% (two out of nine) of patients who displayed radiographic evidence of skeletal maturity. Thus, the proposed surgical technique is potentially more effective than spontaneous osseous union and cast immobilization alone. Furthermore, the authors also compared the results of the percutaneous drilling technique between patients with mature and immature tarsal bones. They found a significantly higher rate of osseous union between the primary and accessory navicular in patients with an open epiphyseal plate at the proximal phalanx of the hallux ( $P = .001354$ ).<sup>4</sup> The results of this study indicate that percutaneous drilling for the purpose of stimulating bone proliferation may not have successful outcomes in patients who display radiographic evidence skeletal maturity. Rather, this surgical technique should be recommended only in young patients with immature tarsal bones as a minimally invasive and relatively simple predecessor to open excision.

### *Original and Modified Kidner Procedures*

Whether the presence of an accessory navicular bone alters foot biomechanics and contributes to the development of pes planus remains controversial. This theory is supported by the fact that flatfoot deformity is

reportedly present in nearly 50 percent of patients who develop symptoms, according to Kim et al.<sup>8</sup> Theoretically, stretching of the posterior tibial tendon around the accessory navicular causes weakness within the tendon and alters the line of pull, ultimately resulting in pes planus deformity.<sup>3</sup> Kidner originally theorized that the accessory ossicle interferes with the normal insertion of the posterior tibial tendon onto the navicular tuberosity, thus interfering with the normal leverage that the tendon imparts on the longitudinal arch. Thus, in 1929, Kidner was the first surgeon to describe a procedure to aid in reconstruction of the medial longitudinal arch by increasing tension within the posterior tibial tendon.<sup>3,8</sup> The original procedure involved excising the entire accessory navicular and rerouting the posterior tibialis tendon to the plantar aspect of the primary navicular bone.<sup>8</sup>

The Kidner is the most commonly performed surgical procedure in the treatment of symptomatic type II accessory navicular recalcitrant to conservative treatment. In very young patients it is debatable whether this procedure can effectively correct a flattened medial longitudinal arch or whether the correction is attributable to physiologic growth alone.<sup>3</sup> However, this procedure is not capable of correcting a collapsed arch in adult patients. Therefore, many

surgeons have either modified the original procedure or have described adjunct procedures to achieve reconstitution of the longitudinal arch. Modifications to the original procedure include the use of a bone tunnel and interference screw to reattach the posterior tibial tendon and modified Kidner procedure with subtalar arthroereisis.

### ***Reconstructive Surgery Using Interface Screw Fixation***

Miyamoto et al. introduced a modification to the original Kidner procedure with the intent to preserve the strength of the posterior tibial tendon post-operatively in adult athletes.<sup>5</sup> This procedure describes exposure and excision of the accessory navicular as performed in the original Kidner procedure. Where this method differs is with respect to the reattachment of the posterior tibial tendon to the primary navicular. Rather than using sutures or suture anchor to repair the tendon, the authors reattached the posterior tibial tendon through a bone tunnel in the navicular using an interference screw for fixation.<sup>5</sup> Cancellous bone chips were used to fill the void between the tendon and the walls of the bone tunnel. This technique provides several benefits over traditional suture anchor fixation including improved healing at the bone-tendon interface.<sup>5</sup> Notably, the bone tunnel increases the

area of contact between bone and the healing tendon when compared to the traditional suture technique. The use of grafted cancellous bone chips contributed to improved healing by protecting fibers of the tendon from the sharp edges of the screw and by providing compression at the bone-tendon interface.<sup>5</sup> By increasing the bone-tendon interface at the primary navicular and using appropriate internal fixation, the authors achieved earlier return to partial weight bearing and range of motion exercises than other techniques. The results of this study by Miyamoto et al. suggest that the use of bone tunneling and interference screws may be an efficacious alternative to the original Kidner procedure in the treatment of painful type II accessory navicular. However, due to the limited sample size of ten adult patients, a randomized control trial must be performed before these results can be extrapolated to the population at large.

### ***Simple Excision***

While the Kidner procedure has gained popularity among the surgical community, critics of the technique claim that it requires prolonged immobilization due the disruption and reattachment the posterior tibial tendon. For this reason, some surgeons recommend simple excision only.<sup>6</sup> Micheli et al. performed simple accessory navicular excision with

naviculoplasty in thirteen feet of ten patients and performed follow up by phone questionnaire over 7.2 years. All patients in the study had self-reported pain relief and had been able to return to all desired athletic activities at the latest follow up.<sup>6</sup> The authors had a favorable outcome in regard to patient reported improvement in pain such that eleven feet were rated as having excellent results and two were reported as having good results. The authors defined “excellent” results as a painless foot that required no shoe wear modifications while “good” was defined as a painless foot with mild fatigue that required shoe wear modifications.<sup>6</sup> Although the rating scale is subjective and lacks objective clinical and radiographic data to support that simple excision is superior to the Kidner procedure in regard to long-term outcomes, the study did point out one important benefit of simple excision with respect to post-operative immobilization. Patients in the study were immobilized in a short leg cast or walking boot for only four weeks, at which time physical therapy was initiated.<sup>6</sup> This immobilization period was two weeks shorter than that reported in the literature for the Kidner procedure, which requires a minimum of six weeks immobilization post-operatively.



### *Arthrodesis*

Arthrodesis of the type II accessory navicular to the navicular body is not a frequently utilized or widely published surgical technique. In theory, arthrodesis is similar to the percutaneous drilling technique in that both are intended to provide stability to and inhibit shearing forces at the fibrocartilaginous bridge between the navicular and its accessory ossicle. Both procedures avoid detachment of the posterior tibial tendon from its insertion on the navicular tuberosity in order to prevent progressive flattening of the medial longitudinal arch post-operatively.<sup>2</sup> Arthrodesis differs from percutaneous drilling in that it is more invasive and requires the use of screw fixation of the accessory ossicle to the primary navicular. Scott et al. performed a retrospective case control study of twenty patients treated for symptomatic type II accessory navicular.<sup>2</sup> The authors intent was to perform arthrodesis on all twenty patients, however the decision was made intraoperatively to perform a modified Kidner on all patients whose accessory navicular was not large enough to support internal fixation with 3.5mm lag screws. Interestingly, this anatomical variation between subjects allowed the authors to make a direct comparison of pre and post-operative improvement in the AOFAS midfoot scores between two similar patient populations having either

arthrodesis or a modified Kidner. At an average follow up of 35 months post-operatively, they found that patients in the arthrodesis cohort had an average improvement of 43 points on the AOFAS midfoot pain scale. Post-operative complications in the arthrodesis group included two radiographic non-unions and one case of symptomatic hardware, which required removal.<sup>2</sup> Patients who received the modified Kidner procedure were followed up for an average of 48 months and on average only experienced an improvement of 28 points on the AOFAS midfoot pain scale. Furthermore, as the authors predicted, three out of ten patients treated with the modified Kidner displayed radiographic evidence of gradual loss of medial longitudinal arch height. Neither the arthrodesis nor the Kidner group experienced nerve injuries or wound infections.<sup>2</sup> While those patients who underwent arthrodesis experienced a significantly greater increase in AOFAS midfoot scores compared to those who received modified Kidner operations ( $p=0.008$ ), the final scores of 93 in the arthrodesis group and 80 in the Kidner group were not statistically different.<sup>2</sup> The results of this study may have been influenced by adjunctive corrective osteotomies and soft tissue procedures that were performed in patients who presented with an accessory navicular and concomitant

pes planus deformity. Due to the small sample size of this study and the use of adjunctive procedures that were not included in the statistical outcome analysis, this study does not definitively define the benefits of arthrodesis over the modified Kidner technique. Perhaps arthrodesis is a viable surgical option for patients without pes planus deformity whose accessory ossicle is large enough to support internal fixation. While the results do show promising results with accessory navicular arthrodesis in regards to improved AOFAS pain scores and maintenance of the longitudinal arch height in patients, a large multi-centered clinical trial would need to be conducted to determine the efficacy of this procedure.

## CONCLUSION

The symptomatic type II accessory navicular is a pathology frequently encountered by podiatrists. Initial treatment typically consists of non-operative conservative treatment with rest, nonsteroidal anti-inflammatory medications and immobilization for several months.<sup>5</sup> However, conservative treatments tend to fail, especially in patients who have active lifestyles. Therefore, surgical intervention is often required to provide long-term pain relief. Several surgical techniques exist to address

the accessory ossicle. The Kidner procedure is the classic surgical intervention for painful type II accessory navicular and has proven to be effective in relieving pain associated with the accessory ossicle. A potential disadvantage to the classic Kidner is the disruption of the insertion of the posterior tibial tendon at its insertion on the navicular.

Simple excision of the ossicle has been presented as a tendon-sparing alternative to the classic procedure and provides similar clinical and radiographic results. The simple excision technique may be efficacious in patients with a weakened posterior tibial tendon where preserving strength is a priority. Percutaneous drilling of the accessory navicular is a viable inexpensive and minimally invasive option in young skeletally immature patients suffering from painful accessory navicular. Arthrodesis of the accessory ossicle to the primary navicular is comparable to percutaneous drilling in theory and surgical outcomes. However, it is reserved for older patients who have reached osseous maturity and have a large enough navicular bone to withstand internal hardware. Reconstructive surgery using a bone tunnel with interference screw is less frequently performed and provides clinical outcomes comparable to other more universally performed techniques. This procedure may be

indicated for patients who have good bone stock to support the bone tunnel and when early return to range of motion is preferred.

## AUTHORS' CONTRIBUTIONS

All authors participated equally in the conception of the research topic, literature review, and extraction of data. All authors contributed equally to the literature review and agreed upon the final manuscript.

## STATEMENT OF COMPETING INTERESTS

The authors declare that they have no competing interest.

## REFERENCES

1. Jegal H, Park YU, Kim JS, Choo HS, Seo YU, Lee KT. Accessory navicular syndrome in athlete vs general population. *Foot Ankle Int.* 2016; 37(8):862-7.
2. Scott AT, Sabesan VJ, Saluta JR, Wilson MA, Easley ME. Fusion versus excision of the symptomatic type II accessory navicular: a prospective study. *Foot Ankle Int.* 2009; 30(1):10-5.
3. Garras DN, Hansen PL, Miller AG, Raikin SM. Outcome of modified Kidner procedure with subtalar arthroereisis for painful accessory navicular associated with planovalgus deformity. *Foot Ankle Int.* 2012; 33(11):934-9.
4. Nakayama S, Sugimoto K, Takakura Y, Tanaka Y, Kasanami R. Percutaneous drilling of symptomatic accessory navicular in young athletes. *American Journal of Sports Medicine.* 2005; 33(4):531-5.
5. Miyamoto W, Takao M, Yamada K, Yasui Y, Matsushita T. Reconstructive surgery using interference screw fixation for painful accessory navicular in adult athletes. *Arch Orthop Trauma Surg.* 2012;132(10): 1423-7.
6. Micheli LJ, Nielson JH, Ascani C, Matanky BK, Gerbino PG. Treatment of painful accessory navicular: a modification to simple excision. *Foot Ankle Spec.* 2008; 1(4):214-7.
7. Rietveld AB, Diemer WM. Surgical treatment of the accessory navicular (os tibiale externum) in dancers: A retrospective case series. *Journal of Dance Medicine & Science.* 2016; 20(3):103-8.
8. Kim JR, Park CI, Moon YJ, Wang SI, Kwon KS. Concomitant calcaneo-cuboid-cuneiform osteotomies and the modified Kidner procedure for severe flatfoot associated with symptomatic accessory navicular in children and adolescents. *Journal of Orthopaedic Surgery and Research.* 2014; 9:131.

# Comparison of Modified Chrisman Snook and Modified Brostrom Technique for Chronic Lateral Ankle Instability: A Literature Review

Mustafa Ahmed, BS, Shadi Aouad, BS, Mazin Sadik, MBCHB, & Rahman Majid, BA

## Abstract

### Introduction

Ankle injuries commonly entail ligament injuries. These ligament injuries most likely occur during times of increased stress such as physical activity. The most frequently affected ligaments are the lateral collateral ankle ligaments. Medial collateral ligament injuries tend to occur with more severe fracture injuries. Conservative treatment is the standard first step of care in acute ankle injuries. The majority of people with acute ankle injuries respond well to conservative treatments. A small percentage of patients who fail conservative treatment develop subsequent chronic ankle insufficiency and require a more aggressive treatment option such as surgery. Ankle injuries are one of the main causes of lateral ankle insufficiency. Other causes include ligamentous laxity, subtalar instability, neurologic and other biomechanical disorders. The most commonly used surgical option for chronic lateral ankle instability is the modified Brostrom procedure, due to the excellent outcomes reported. However, this procedure will not always be the best surgical technique, overall for patients with chronic lateral instability.<sup>6</sup> The purpose of this paper is to compare the Modified-Broström and Modified Chrisman Snook technique for indications, complications and ability to stabilize the lateral collateral ankle ligaments.

**Study design:** Systematic review of the literature

### Methods

A literature search was conducted using the PubMed database. Search terms using Boolean operators included “Modified Broström”, “Modified Chrisman Snook”, “Chronic lateral ankle instability”, “Chronic ankle insufficiency,” and “Ligament reconstruction”. In addition the following MesH terms were used: “Humans,” “English.” The search yielded 2197 articles in total in which 4 articles were chosen relating to Ligament reconstruction and Chronic ankle Insufficiency. The search yielded 25 articles related to Chrisman Snook procedure from the PubMed database in which 3 articles were chosen. The search yielded 32 articles related to Modified Broström procedure in which 6 articles were chosen based on relevance to podiatry and exclusion criteria. Inclusion criteria included articles published from 2000-2016, full text availability, and chronic ankle instability. Exclusion criteria included non English articles, deltoid ligaments, non-human subject articles prior to 2000.

### Results

The studies for the Modified Broström and Modified Chrisman Snook procedures evaluated preoperative and postoperative talar tilt, average time to return to activity, wound complications, overall satisfaction, functional analysis scores, ankle and subtalar joint ranges of motion and common postoperative complications. The results showed the talar tilt angle decreased in both procedures. The recovery period for Modified Broström was significantly shorter than the Modified Chrisman Snook, but in terms of post op infections, they were more likely to occur with the Modified Broström procedure. For both procedures the majority of the patients were satisfied with the procedure outcomes.

### Conclusion

The Modified Chrisman Snook and Modified Broström procedure to correct chronic lateral ankle instability resulted in good functional AOFAS/FOAS scores, improved talar tilt angle, improved satisfaction scores, and lateral ankle stability. The Modified Broström procedure was able to obtain results similar to a more extensive procedure but with quicker return to activity, better patient satisfaction, less ankle and subtalar joint range of motion loss, and less surgical and wound complications. The limitations to this study were the number articles for comparison of these two procedures, the number of patient subjects, and lack of using the same functional outcome analysis of either the AOFAS, or FAOS to compare.

**Key Words:** Modified Broström, Modified Chrisman Snook, chronic ankle insufficiency

*Levels of Evidence:* 4

## INTRODUCTION

Chronic ankle instability is a common complication after an acute lateral ankle sprain. Conservative treatment with bracing or neuromuscular training is the first treatment option. However, if symptoms persist and the ligaments on the lateral side of the ankle are attenuated or torn, surgery is indicated.<sup>7</sup> Roughly 80% of the patients respond well to conservative treatment and do not necessitate further treatment.<sup>11</sup> The 20% of patients that are recalcitrant to conservative treatment require surgery for chronic ankle insufficiency.<sup>11</sup> Injury involving the ankle is not the only cause of lateral ankle insufficiency. Ligamentous laxity, subtalar instability, obesity, neurologic disorder, increased fibular mobility, rear foot varus, and cavovarus are other causes.<sup>4</sup> The purpose of this paper is to compare the modified-Broström and modified Chrisman Snook technique for indications, complications, ability to stabilize the lateral collateral ankle ligaments, time to return to activity, and overall patient satisfaction.

### *Anatomy:*

Ankle joint stability is provided by three groups of ligaments: the lateral collateral ligaments, the tibiofibular syndesmosis and the medial collateral ligaments (deltoid ligament complex). The most commonly injured ligaments

are the lateral collateral ligaments comprised of the anterior talofibular ligament (ATFL), the calcaneofibular ligament (CFL) and the posterior talofibular ligament (PTFL).<sup>13</sup> The ATFL is the primary stabilizer of ankle joint against inversion and plantarflexion stress. As a result, placing the ATFL under inversion, plantarflexion, and internal rotation stress will cause rupture of the ligament. The CFL is the primary stabilizer of both the ankle joint and the subtalar joint against inversion and dorsiflexion stress. The CFL tears primarily under ankle inversion and dorsiflexion stress. Therefore, surgical repairs to correct lateral ankle instability should include repair and augmentation of the ATFL and CFL if ankle and subtalar instability are suspected. The posterior talofibular ligament is the strongest of the lateral ligaments and is usually not injured. It is well documented that the consequences of missed or undertreated ankle instability leads to chronic instability resulting in as many as 60% of patients.<sup>10</sup>

Diagnosis of ATFL and CFL tears are typically based on clinical findings, these include increased joint space laxity on anterior drawer and talar tilt testing when compared to the contralateral ankle. It is important to rule out high syndesmotic ankle sprains injuries by eliciting pain on external rotational, inability to perform a single leg hop on the involved side, positive squeeze test and fibular instability. If the clinical exams are positive for ATFL, CFL and syndesmosis rupture then a stress

radiograph should be in the workup of ankle laxity.<sup>14</sup>

***Indications:***

Modified Chrisman Snook and Modified Broström procedure are both surgical options when conservative treatment has failed for chronic Anterior talofibular ligament and Calcaneofibular ligament insufficiency.<sup>4</sup> These procedures are reserved for active athletes, gymnasts and dancers. The Chrisman Snook technique is typically used for heavier athletes and obese patients. The Modified Broström procedure is used in chronic lateral ankle insufficiency where fibular tendon and muscle preservation is required.<sup>4</sup> Conservative treatment should be performed prior to surgical intervention due to the importance of improving muscle strength and proprioception, which is required in postoperative management.<sup>4</sup>

***Surgical techniques:***

***Modified Broström***

The 2 common methods of the modified Broström procedure, are the bone tunnel and the suture anchor technique.<sup>15</sup> The procedure that will be discussed is the one utilizing suture anchors. The procedure begins with patients receiving spinal or general anesthesia. The patient is placed in the supine position with a pneumatic tourniquet along the proximal calf. A dose of intravenous antibiotics is administered preoperatively. The tourniquet is inflated and a 3-4 cm skin incision is made from the anterior

distal fibula in a curved pattern, following along the lateral malleolus and terminating at the fibular tendons.<sup>15</sup> Full thickness skin incision is created down to the capsule. The lateral portion of the inferior extensor retinaculum is moved superiorly from the distal fibula. The fibular tendons are retracted distally.<sup>15</sup> The capsule, anterior talofibular ligament (ATFL), and calcaneofibular ligaments (CFL) are divided 1-2mm from the distal fibula. At the distal fibula an elevated subperiosteal sleeve is created. A trough in the distal fibula is created using a bone rasp and curette. 3.5 mm threaded suture anchors are inserted into the anatomic position for the ATFL and CFL. The advantage of ankle ligament reconstruction using suture anchors include an ability to reattach ligaments to the anatomically accurate position, a smaller incision, less surgical dissection, technical ease, a decreased operative time, and an ability to avoid the risks of fracture caused by multiple holes drilled in the fibula for the preparation of the bone tunnel. (12). The tension is created within the ATFL and CFL ligaments by positioning the ankle in neutral and slight eversion of the subtalar joint. Next the sutures are passed through the ATFL and CFL, anchoring the ligaments and capsule to the distal fibula.<sup>15</sup> The periosteal sleeve is sutured over the ligaments and capsule. The inferior extensor retinaculum is sutured to the periosteum and lateral capsule of the ankle joint. The tourniquet is deflated and the wound is cleaned with antibiotic solution. The wound is then reapproximated with 3-0 sutures for

subcutaneous tissue and 5-0 sutures for the skin.<sup>15</sup>

### ***Modified Chrisman Snook***

The modified Chrisman Snook procedure begins with the patient in the supine position with a thigh high tourniquet applied. An 8 cm curvilinear incision is made posterior to the lateral malleolus following the direction of the fibular tendons terminating just proximal to the fifth metatarsal base.<sup>7</sup> The sinus tarsi is exposed using an elevator. Fibularis brevis is then split in half. The half containing the least amount of muscle fibers attached is harvested with an open tendon stripper. The split is then carried proximal where the tendon stripper is tunneled under the skin where an ethibond whip stitch is used to tubularize the end of the fibularis brevis graft.<sup>7</sup> The superior fibular retinaculum is left intact. The longitudinal split incision of fibularis brevis is continued distally only to the distal aspect of the skin incision. The fibula is exposed just proximal to ATFL where a 4.5mm drill bit is used to create a tunnel. The tunnel is angled posterior and distal to emerge at the posterior aspect of the fibula. Another 4.5 mm drill hole is created through the lateral calcaneal cortex anterior to the insertion of the calcaneofibular ligament.<sup>7</sup> A second drill hole is created 15-20 mm posterior to the first drill hole on the lateral aspect of the calcaneus and connected using curved curettes. Sutures are placed but not tied between the lateral periosteum of the fibula and the tendinous portion of extensor digitorum brevis, replicating the path of the ATFL.<sup>7</sup> The split

fibularis brevis is placed anterior to posterior through the tunnel that was generated in the fibula, then from posterior to anterior in the canal generated in the lateral aspect of the calcaneus. The graft should pass superficial to the underlying fibular tendons to avoid subluxation of fibular tendons. The ankle is held in a valgus posture where the sutures that were placed previously but were not tied are now tied.<sup>7</sup> The knee is flexed 90 degrees and the ankle maximally dorsiflexed with subtalar joint held in neutral position. The free end of the split fibularis brevis tendon is positioned proximally to generate tension, where the graft is then secured in this position.<sup>7</sup> The split fibularis brevis is sutured to the fibular periosteum along with the ethibond stitches at the free end of the graft. The ankle is maintained in dorsiflexion throughout graft fixation. If fibular subluxation is a concern, repair of the superior fibular retinaculum is performed.

## **METHODS**

Two authors conducted independent literature searches using the PubMed database. Search terms using Boolean operators included “Modified Broström”, “Modified Chrisman Snook”, “Chronic lateral ankle instability”, “Chronic ankle insufficiency”, “Ligament reconstruction”. In addition the following MeSH terms were used: “Humans”, “English” were used. The search yielded 2197 articles in total in which 4 articles were chosen relating to Ligament reconstruction and

Chronic ankle Insufficiency. The search yielded 25 articles related to Chrisman Snook procedure from the PubMed database in which 3 articles were chosen. The search yielded 32 articles related to Modified Broström procedure in which 6 articles were chosen based on relevance to podiatry and exclusion criteria. Inclusion criteria included articles published from 2000-2016, full text availability, and chronic ankle instability. Exclusion criteria included non English articles, deltoid ligaments, non-human subject articles prior to 2000.

## RESULTS

The studies involving the Modified Broström were conducted by Xu et. al, a total of 155 ankles in 155 patients were evaluated at a mean follow-up duration of 42.8 months (range, 24-101 months) postoperatively.<sup>16</sup> The study divided the 155 ankles into 2 groups: a men's group (94 ankles) and a women's group (61 ankles). Chronic lateral ankle instability was the primary indication for surgery. The study conducted by Messer also performed the Modified Broström procedure on 22 patients with a mean age of 27.2 who had chronic lateral ankle instability.<sup>15</sup> In particular, athletes have high risk of recurrence for ankle injuries; thus, careful attention must be given to the selection of the treatment method, rehab plan, and timing of the return to sports.<sup>11</sup> Lee et al found no significant difference in the clinical results between professional athletes and ordinary people after the modified

Broström procedure.<sup>8,9</sup> Indicating the Modified Broström procedure may work just as well for more serious ankle injuries.

The studies for the Modified Broström and Chrisman Snook procedures evaluated preoperative and postoperative talar tilt, average time to return to activity, wound complications, overall satisfaction, functional analysis scores ankle and subtalar joint ranges of motion and common postoperative complications.

The talar tilt angle decreased from 14 degrees preoperatively to 4 degrees postoperatively for the Modified Chrisman-Snook procedure.<sup>2</sup> The talar tilt decreased from 11.9 degrees for men and 11.4 degrees for women preoperatively to 6 degrees postoperatively for both men and women when the Modified Broström was performed.<sup>16</sup> The average return to recovery was 8 weeks for the modified Broström procedure and 6 months for the Modified Chrisman Snook procedure.<sup>7,16</sup>

When the modified Broström procedure was performed 5 patients developed superficial wound infections, but while using the Modified Chrisman Snook procedure developed zero wound complications when smaller incisions were performed.<sup>7,16</sup> The American Orthopedic Foot & Ankle Society (AOFAS) score for the Modified Broström procedure preoperatively was 62.4 points in men and 63.6 points in women and postoperatively 93.7 and 92.3 respectively. The



AOFAS was conducted by 2 independent observers who were not involved in the operative treatment of the patients to avoid bias.<sup>16</sup> The Foot and Ankle Outcome Score (FAOS) for the Modified Chrisman Snook procedure resulted in a mean score of 74.<sup>7</sup> Patients had a mean overall satisfaction score for the surgery of 8.6 out of 10 which correlates to 86% for the Modified Broström procedure conducted by Messer and 84.6% satisfaction for the Modified Chrisman Snook procedure.<sup>7,11</sup> Messer states the Modified Broström procedure has a typical satisfaction score range of 85-90% which is slightly higher than the results obtained in the Messer study.<sup>5</sup> The ankle and subtalar joint ranges of motion for dorsiflexion, plantarflexion, inversion and eversion are summarized in table 1 and 2 for both procedures.

The common complications of the Modified Broström procedure involved re-rupture, loss of ankle joint range of motion, superficial infections, and nerve injuries. Overall complication rates ranged from 9.8% to 17%. 28 patients in the study conducted by Xu resulted in the following complication rates. Rate of 4.6% for rerupture, superficial infections, and loss of ankle range of motion, and 5.95% for nerve injuries.<sup>16</sup> The modified Chrisman Snook resulted in 9.1 % developing excessive fibular scarring, 6.8% with excessive sural nerve scarring, 4.5% had anterior ankle impingement, 4.5% developed complex regional pain syndrome, 54.5% had peri-incisional

numbness and 13.6% felt their ankle was “too tight”.<sup>7</sup>

Modified Chrisman Snook	Nonoperative Ankle	Operative Ankle	P Value
Dorsiflexion	13.0 ± 7.0	11.0 ± 8.0	<0.01
Plantarflexion	62.0 ± 17.0	58.0 ± 17.0	<0.01
Inversion	26.0 ± 10.0	20.0 ± 11.0	<0.01
Eversion	16.0 ± 12.0	14.0 ± 11.0	<0.05

Table 1

Modified Broström	Nonoperative Ankle	Operative Ankle	P Value
Dorsiflexion	15.5 ± 4.1	14.7 ± 4.7	0.196
Plantarflexion	43.8 ± 9.6	44.7 ± 8.2	0.476
Inversion	20.0 ± 7.0	16.5 ± 5.2	0.010
Eversion	10.1 ± 3.4	9.7 ± 3.9	0.648

Table 2

## DISCUSSION

The major comparisons between the two procedures were talar tilt, average time to return to activity, wound complication, functional analysis scores, ankle and STJ range of motion, satisfaction score, and common complication.

The Modified Chrisman-Snook procedure decreased the talar tilt angle to 4 degrees.<sup>3</sup> The Modified Broström procedure decreased the talar tilt to 6 degrees.<sup>16</sup> The greater reduction in talar tilt angle from the Modified

Chrisman Snook procedure indicates it is more successful in generating lateral ankle stability, at the expense of limiting ankle and subtalar joint ranges of motion. The Modified Chrisman Snook procedure was able to reduce talar tilt angle more than the Modified Broström procedure however, patients who underwent the modified Chrisman snook required three times longer to return to activity than the Modified Broström procedure.

The Modified Chrisman Snook procedure is a more extensive and invasive surgery when compared to the Modified Broström procedure. The more extensive the surgery the greater likelihood for complications. This holds true in the analysis between the two procedures. Although the Modified Broström procedure was found to have wound complications and the modified Chrisman Snook was not, the Modified Chrisman Snook still had greater and more severe complications. The procedures both had nerve complications, but the Modified Chrisman Snook also had fibularis brevis scarring, anterior ankle impingement, complex regional pain syndrome, and overtightening of the lateral ankle. The limitation of the study was the difference in analysis of outcomes of the procedures using the AOFAS score and FAOS score. Although the functional analysis of both procedures were conducted using different subjective analysis, the FAOS score for the Modified Chrisman Snook procedure and the AOFAS score for the Modified Broström procedure still provide

insight as to how well each procedure performed. The procedures both had significant increases in their respective scores from preoperatively to postoperatively, with the Modified Broström procedure having a greater increase in score. The improvement in scores for both procedures suggests that they were successful in treating chronic lateral ankle instability.

The ankle and subtalar joint ranges of motions were compared between both procedures with the aim of each to reduce inversion instability, by restricting subtalar joint inversion. It was important to note that the Chrisman Snook procedure was used in patients with greater inversion instability at a mean inversion range of motion of 26.0 preoperatively, while the Broström procedure was used in patients with a mean inversion of 20.0 preoperatively. In both surgical procedures the inversion instability was corrected, however the range of motion of dorsiflexion, plantarflexion, and eversion were all reduced, with a greater loss of range of motions from the Modified Chrisman Snook procedure.<sup>7,16</sup>

The procedures both generated similar patient satisfaction scores, 86% for Modified Broström and 84.6% for the modified Chrisman Snook procedure. The Modified Broström procedure was able to produce better satisfaction scores and fell within the typical average patient satisfaction score as reported by Kramer et al. of 85-90%.<sup>7,16</sup> The procedures were both successful in achieving high patient satisfaction scores, although the Modified

Broström procedure was able to achieve higher patient satisfaction scores with a less extensive procedure.

## CONCLUSION

The Modified Broström and Modified Chrisman Snook procedures both remain viable options in treating chronic lateral ankle instability after conservative methods have failed. The Modified Broström procedure was able to obtain results similar to a more extensive procedure but with quicker return to activity, better patient satisfaction, less ankle and subtalar joint range of motion loss, and less surgical complications. The Modified Chrisman Snook is a more extensive surgery but is able to reduce the talar tilt angle, and inversion of the subtalar joint more than the Modified Broström procedure, but at the risk of decreasing mobility of the ankle and subtalar joint which are required in athletes. The procedures are both useful in the treatment of chronic lateral ankle instability, but care should be taken when deciding which procedure to perform. Patient selection and severity of the the lateral ankle instability must be thoroughly addressed since these procedures are mainly utilized on active athletes and return to activity varies great between these two procedures along with a decrease in range of motion. The Modified Chrisman Snook and Modified Broström procedure to correct chronic lateral ankle instability resulted in good functional AOFAS/FOAS scores, improved talar tilt angle, improved satisfaction scores, and decreased the lateral ankle

stability. This paper shows that the Modified Broström, a less invasive procedure, may still be the gold standard in treating patients for lateral ankle instability, especially in active athletes that require adequate ankle and subtalar joint range of motion. The limitations to this study were the limited articles for comparison of these two procedures, the limited number of patient subjects, and lack of commonality of using the same functional outcome analysis of either the AOFAS, or FAOS to compare, and should be taken into consideration when conducting future research.

## AUTHORS' CONTRIBUTION

Four authors contributed equally to the production of this manuscript. All authors worked on the topic title, the introduction, methods, results, discussion, and conclusion. All authors peer edited, drafted, read, reviewed, and agreed upon the final manuscript.

## STATEMENTS OF COMPETING INTERESTS

The authors declare that they have no conflict of interests.

## REFERENCES

- 1.) Baumhauer JF, O'Brien T. Surgical Considerations in the Treatment of Ankle Instability. *Journal of Athletic Training*. 2002;37(4):458-462.
- 2.) Byung-Ki Cho, et al. "A ligament reattachment technique for High-Demand Athletes With Chronic Ankle Instability". "the journal of foot & ankle Surgery" (2014).
- 3.) de Vries, Jasper S., et al. "Interventions for treating chronic ankle instability." *The Cochrane Library* (2011).
- 4.) Donald J. McBride, and Chandru Ramamurthy. "Chronic ankle instability: management of chronic lateral ligamentous dysfunction and the varus tibiotalar joint." *Foot and ankle clinics* 11.3 (2006): 607-623.
- 5.) Hu, C.Y., Lee, K.B., Song, E.K. et al, Comparison of bone tunnel and suture anchor techniques in the modified Broström procedure for chronic lateral ankle instability. *Am J Sports Med*. 2013;41:1877-1884.
- 6.) Karlsson J, Bergsten T, et al " Reconstruction of the lateral ligaments of the ankle for chronic lateral instability" *J Bone joint surg Am* 70;581-588,1988.
- 7.) Kramer, Dennis, et al. "Clinical results and functional evaluation of the Chrisman-Snook procedure for lateral ankle instability in athletes." *Foot & ankle specialist* (2010).
- 8.) Lee KT, et al. "Analysis of affecting factors of modified Brostrom procedure in chronic ankle lateral instability" *J Korean Foot Ankle Soc* 6:66-72,2002.
- 9.) Li X, et al. "Long-term results of the Chrisman-Snook operation for reconstruction of the lateral ligaments of the ankle" *J Orthop surg Res* 4:41, 2009.
- 10.) McCriskin BJ, Cameron KL, Orr JD, Waterman BR. Management and prevention of acute and chronic lateral ankle instability in athletic patient populations. *World Journal of Orthopedics*. 2015;6(2):161-171. doi: 10.5312/wjo.v6.i2.161.
- 11.) Messer, Terry M., et al. "Outcome of the modified Broström procedure for chronic lateral ankle instability using suture anchors." *Foot & Ankle International* 21.12 (2000): 996-1003.
- 12.) Paden MH, stone PA, et al. " Modified Brostrom lateral ankle stabilization utilizing an implantable anchoring system. *J Foot Ankle Surg* 33:617-622, 1994.
- 13.) Russo A, Giacche P, Marcantoni E, Arrighi A, MOLFETTA L. Treatment of chronic lateral ankle instability using the Broström-Gould procedure in athletes: long-term results. *Joints*. 2016;4(2):94-97. doi: 10.11138/jts/2016.4.2.094.
- 14.) Slater GL, Pino AE, O'Malley M. Delayed reconstruction of lateral complex structures of the ankle. *World Journal of Orthopedics*. 2011;2(4):31-36. doi:10.5312/wjo.v2.i4.
- 15.) Takao M, Miyamoto W, et al. " Functional Treatment After Surgical Repair for Acute Lateral Ligament Disruption of the Ankle in Athletes" *Am J Sports Med* 40;447-451, 2012.
- 16.) Xu, He-Xing, et al. "Gender Differences in Outcome After Modified Broström Procedure for Chronic Lateral Ankle Instability." *Foot & ankle international* 37.1 (2016): 64-69.

# An In-Depth Comparison of Various Surgical Treatments for Haglund's Deformity: A Systematic Review

Wade Chimerofsky, BS, Ashima Choudhary, BS, Angelica Emeakoroha, BS, Thi Pham, BS,MS & Ying Shao, BS

## Abstract

### Introduction

Haglund's deformity is characterized by a bony enlargement at the back of the heel. Soft tissues in the surrounding area become inflamed and lead to Achilles tendonitis and retrocalcaneal bursitis. Traditionally, Haglund's deformity is treated by either open bone resection or endoscopic bone resection of the posterior heel. The purpose of this paper is to compare these two surgical treatments in terms of contraindications, surgical complications, and patient outcomes.

**Study design:** Systematic Qualitative Review of the Literature

### Methods

An English language literature search was performed utilizing PubMed. The search was divided into three searches and included keywords such as "Haglund's deformity AND surgical," "Haglund's AND endoscopic," and "Haglund AND endoscopic AND decompression." Inclusion criteria were limited to articles written in the English language, the articles must be no older than 10 years, and articles that used humans as test subjects. Exclusion criteria ruled out articles that did not explicitly discuss Haglund's deformity.

### Results

Eight articles were chosen for the systematic review. The average age of the patient was 42 years and the average length of follow-up time was 33.5 months. Both the left and right foot were evaluated in all of the different studies, with some patients even having both feet included in the same study.

### Conclusion

Surgical intervention is commonly employed to treat Haglund's deformity when conservative treatment is unsuccessful in providing symptomatic relief. While the open resection technique has merit, current literature suggests that an endoscopic closed technique might allow for a faster recovery and less postoperative complications.

**Key Words:** Haglund's deformity, endoscopic calcaneoplasty, surgical intervention

*Levels of Evidence:* 4

## INTRODUCTION

Haglund's deformity, also known as retrocalcaneal exostosis, is an abnormality of the posterosuperior part of the calcaneus in which a bony enlargement is observed at the attachment of the Achilles tendon. The adjoining soft tissues can get irritated when this bony lump rubs against rigid shoes. This irritation often leads to Achilles tendonitis leading to, thickening and inflammation along with retrocalcaneal bursitis. When seen together, this triad is known as Haglund's syndrome.<sup>1</sup>

Clinical evaluation and lateral radiographs of the ankle are usually enough to make a diagnosis of Haglund's deformity. Clinically, Haglund's deformity presents with signs of inflammation such as swelling, warmth, redness, and tenderness over the posterior heel. On lateral radiograph, a bony prominence (Haglund's lesion) is seen at the posterosuperior part of the calcaneal tuberosity. One would also find calcaneal bursal swelling and increased density in pre-Achilles bursa on MRI. Once diagnosed correctly, it is often treated conservatively by altering the heel height in shoe wear, orthosis, physiotherapy, anti-inflammatory drugs, and local steroid injections.<sup>1</sup>

If pain persists for over six months despite conservative therapy, and a bony exostosis is confirmed by imaging, surgical treatment is considered. The conventional surgical treatment is an open bone resection of the calcaneal prominence.<sup>2</sup> It has been a widely accepted approach for treating Haglund's deformity and has been shown to have substantial postoperative improvement with different outcome measures conducted by several studies. However, compared to the other approach, open surgical treatment is associated with the increased risk of several complications including skin breakdown, Achilles tendon avulsion, altered sensation, and stiffness.<sup>3</sup>

Endoscopic bone resection, or endoscopic calcaneoplasty is an up-and-coming procedure that avoids many of the complications encountered with the traditional open surgical technique.<sup>3</sup> It is a minimally invasive technique for resection of inflamed retrocalcaneal bursa as well as the posterosuperior part of the calcaneus. The procedure allows for better tendon healing, shorter recovery time, and fewer wound complications.<sup>2</sup> However, since endoscopic calcaneoplasty is a relatively new procedure with limited practical knowledge by clinicians, continuous modification for the procedure is required in order to prevent

complications and improve patient outcome.<sup>3</sup>

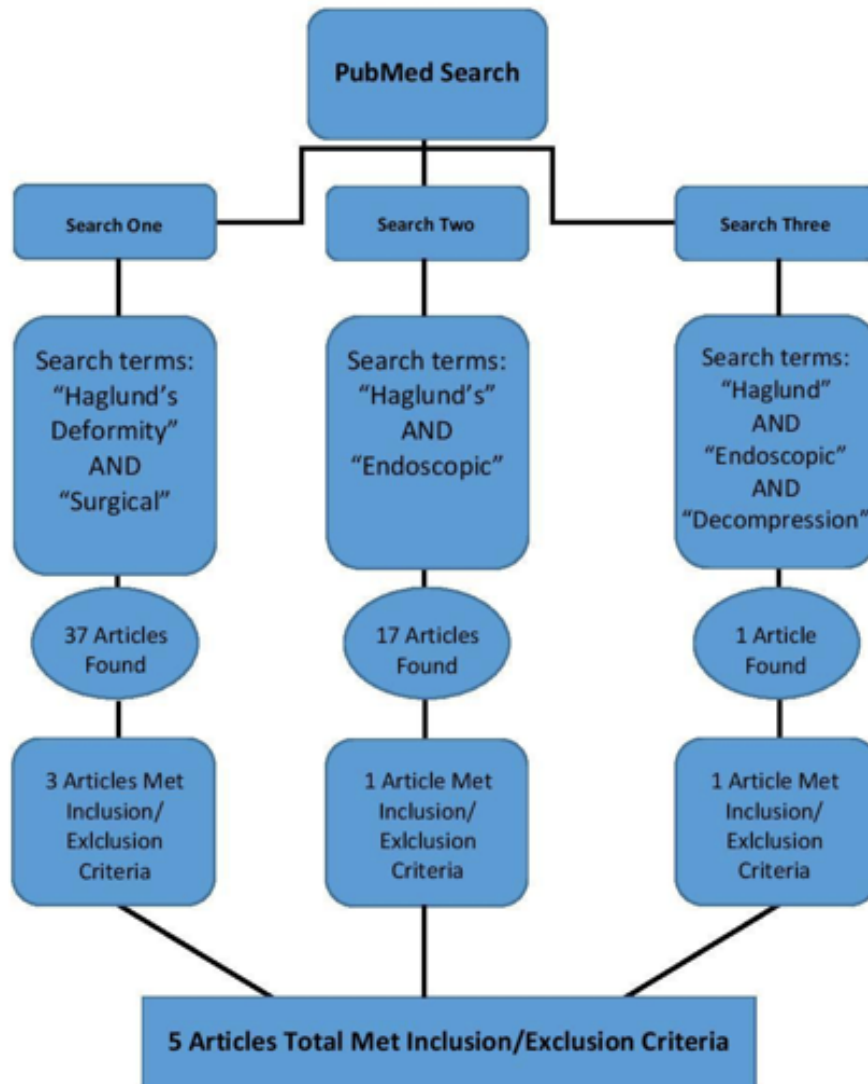
According to current literature, there are three open resection techniques and two endoscopic resection techniques proposed for surgical correction of Haglund's deformity. Open surgical resection techniques include the single incision exposure using the Kerrison Rongeur,<sup>4</sup> the Keck and Kelly wedge osteotomy to decompress the calcaneus,<sup>5</sup> and surgical detachment and reattachment of the Achilles Tendon.<sup>6</sup> The newer endoscopic resection techniques include the traditional approach using medial and lateral portals, or the three portal technique which allows better visualization of the retrocalcaneal space. The purpose of this paper is to compare complications, contraindications, and patient outcomes of both open and endoscopic resections

## METHODS

A thorough search was conducted through PubMed and was divided into three search categories. The first search utilized the terms "Haglund's Deformity", "Surgical", and the Boolean operator "AND", which resulted in 37 articles. Those 37 articles were narrowed down further after several exclusion factors were implemented. Articles that were non-English, older than 10 years, and did not explicitly discuss Haglund's deformity in the article were ruled out,

which narrowed the search to 16 articles. Of those 16 articles, 7 articles were deemed relevant to the topic of surgical intervention of Haglund's deformity. However, 2 of the 7 articles were neither case reports, case series, or systematic reviews so they could not be considered for this systematic review. After the initial reading of those 7 articles, several keywords frequented all the articles, which included "endoscopic", "endoscopic calcaneoplasty", and "Haglund's syndrome." Due to the variation of the term "Haglund's deformity" used among the researchers and the extensive research being done on minimally invasive techniques as a promising alternative to conservative treatment options due to their efficacy and safety, a second search was conducted using the terms "Haglund's", "Endoscopic", and the Boolean operator "AND". The second search resulted in 17 articles. The exclusion factors ruled out articles not in English, articles older than 10 years, articles involving cadavers as subjects of the study, and articles that did not explicitly discuss Haglund's deformity[A1]. Consequently, those 17 articles were narrowed down to 14 for further evaluation. After going through those 14 articles, only one was selected for the systematic review. The keywords "decompression" and "endoscopic decompression" appeared, which

deemed relevant enough for further searches based on these keywords. Therefore, a third search was conducted using the terms “Haglund”, “Endoscopic”, “Decompression”, and the Boolean operator “AND”. Again, the same exclusion factors from the second search were used, which resulted in one relevant article. The search methods have been summarized in Figure 1.



**Figure 1:** Acquisition of articles from PubMed based on inclusion and exclusion criteria (5 articles were selected)



<b>Surgical Procedure</b>	<b>Study author(s)</b>	<b>Objective</b>	<b># of subject / heels</b>	<b>Mean age (yr)</b>	<b>Mean follow-up time (months)</b>	<b>Outcome</b>
<b>Closed Resection</b>	Michels et al.	Evaluation of two portal endoscopic calcaneoplasty combined with Achilles tendon repair	1/2	38	18	Patient presented with normal function and no complaints.
	Wu et al.	Evaluation of three portal endoscopic technique	23/25	27.7	41	No permanent neurovascular injuries and no wound infections were reported in all of the patients
	Ortmann et al.	Evaluation of two portal endoscopic technique	28/30	51	35	The average AOFAS score increased from 62 preoperatively to 97 postoperatively.
	Boffeli et al.	Description of a reproducible Keck and Kelly wedge calcaneal osteotomy technique for Haglund's deformity	--	--	--	The technique allowed for effective decompression of the Haglund's deformity while avoiding dissection around the Achilles tendon
<b>Open Resection</b>	DeVries et al.	Evaluation of open debridement in combination with complete detachment and reattachment of the Achilles tendon	17/22	51.6	40	There was a significant improvement between the mean preoperative visual analog pain scores of 7.9 to postoperative score of 1.6.

**Table 1: Summary of Studies and Results**

## RESULTS

Michels et al. presented a case report investigating the use of endoscopic calcaneoplasty in combination with Achilles tendon repair treatment in a 38 year old male patient with chronic heel pain. The patient had a pre-existing Achilles tendon tear, for which typical treatment includes open surgical techniques, such as calcaneal resection. However, to the knowledge of the authors, this is the first case report to propose endoscopic calcaneoplasty, a closed procedure. They performed a two portal endoscopic calcaneoplasty followed by repair of the Achilles tendon with the use of a Twinfix® suture anchor placed on calcaneus anterior to the tendon tear. Then a needle was inserted through the tendon to retrieve the sutures from the anchor and knotted through this needle's insertion point.<sup>2</sup> After 18 months of follow-up, the patient maintained normal function and no complications.

Wu et al. presented a retrospective evaluation of 23 patients (25 heels) that underwent a three portal endoscopic treatment for Haglund's syndrome. In addition to the two portals utilized in the traditional endoscopic resection, a third portal was made lateral to the Achilles tendon and about 5-cm proximal to its insertion. The authors referred to this

as the proximal posterolateral portal (PPLP). Post-operative radiographs revealed adequate bone removal in 22 heels, while under resection occurred in the remaining 3 heels. However, despite under-resection, the patients were satisfied with the procedure. Using the American Orthopedic Foot and Ankle Society (AOFAS) scoring, they found the score increased from  $63.3 \pm 11.9$  preoperatively to  $86.8 \pm 10.1$  points post-operatively. In the Ogilvie Harris score, they found 15 excellent, 7 good, one fair, and 2 poor results. The poor results were from bilaterally affected heels from a patient that suffered from a knee injury postoperatively. In all of the patients, they found no signs of permanent neurovascular damage and no wound infections.

Ortmann and McBryde conducted a prospective evaluation on the surgical outcome of the two portal endoscopic procedure on 28 patients (30 heels). Based on the AOFAS Ankle-Hindfoot scale, they found an improvement in the score as it increased from 62 points preoperatively to 97 points postoperatively. They used a pain scale of 1-10 and found that 26 feet had excellent results (pain score 1-2), 3 feet had good results (pain score 3-4) and one foot had a poor result (pain score 5-6). The patient with the poor result experienced persist heel pain postoperatively and required an

open surgical resection of the calcaneus and Achilles tendon lengthening. They found no intraoperative complications and all the patients reported satisfaction with the aesthetic appearance of the portal site postoperatively.

Boffeli et al. described an improved Keck and Kelly closing wedge osteotomy technique that reduced the risk of Achilles tendon damage. The technique involved an anterior osteotomy incised at a 90° angle down toward the plantar apex, located slightly posterior to the plantar calcaneal tubercle. Then, a posterior osteotomy starting in the middle of the posterior superior prominence was obliquely incised toward the apex. They found that a vertical anterior osteotomy allowed for the posterior calcaneal prominence to tilt anteriorly, which subsequently elevated the Achilles tendon insertion, creating an effect similar to Achilles tendon lengthening. Anatomical changes to the calcaneus were confirmed using preoperative and postoperative radiographs.

DeVries et al. conducted a retrospective analysis of the surgical outcomes for 17 patients (22 heels) that had undergone open debridement with complete detachment and reattachment of the Achilles tendon. A

medial J-shaped incision was made for the complete detachment and reattachment of the Achilles tendon, resection of calcaneal prominence and excision of retrocalcaneal bursitis. Based on the review of the postoperative survey forms, they found that there was a significant improvement between the preoperative visual analog scale (VAS) pain score of  $7.9 \pm 2.3$  and the postoperative VAS pain score of  $1.6 \pm 1.3$ . Using a nonparametric Maryland Foot Score, they found 10 excellent, 6 good, and one fair result.

## DISCUSSION

Currently, there are two main surgical treatments for Haglund's Deformity, either by open bone or endoscopic bone resection, with the former being the older of the two. Based on the statistical analysis of the results compiled throughout the various articles in this systematic review, the endoscopic bone resection, which is a minimally invasive procedure, seems to be the better option based on various patient outcome metrics. A newly published review showed that the endoscopic calcaneoplasty technique yields better results on the parameters of patient satisfaction and procedure specific complications in comparison to an open technique, both intraoperatively and postoperatively.<sup>8</sup> The removal of the dorsolateral

portion of the calcaneus up to the Achilles tendon insertion and retrocalcaneal bursa is performed in both surgical treatments. One issue with calcaneoplasty is that the amount of bone resection required for successful treatment remains controversial. It has been claimed in the literature that too much bone resection increased the risk of postoperative complications, such as a weakened Achilles tendon insertion, calcaneal fracture, stiffness, and ankle pain. One study found that the open bone resection technique resulted in the resection of more bone than the endoscopic technique. In the endoscopic approach, there is a small but significant risk of rupture of the Achilles tendon if the Achilles insertion is compromised.<sup>9</sup> This rupture can be avoided by a certain open surgical method like the Keck and Kelly wedge osteotomy.

### ***Traditional Endoscopic Calcaneoplasty***

In the traditional endoscopic approach, the medial and lateral portals are placed carefully above the superior portion of the calcaneus, medial and lateral to the Achilles tendon. These portals must be placed in locations that avoid injury of the sural nerve and the calcaneal branches of the lateral plantar nerve. The endoscopic approach was developed to reduce

morbidity and has been shown to have fewer complications and produce a better cosmetic appearance than the open surgical approach.<sup>3</sup> This surgical approach allows for much smaller incisions, medial and lateral visualization of the bony prominence as well as the undersurface of the Achilles tendon and its insertion.<sup>9</sup> Since this technique offers better visualization, there is minimal soft tissue disruption and a more accurate decompression, thus avoiding under-resection or over-resection of the bone. Although Ortman et.al showed that the endoscopic calcaneoplasty procedure provided fewer complications, several limitations were still encountered. Having a small cohort and a bias involved in retrospectively acquired AOFAS scores were the major limitations of the study. Furthermore, this technique is contraindicated in patients with calcific tendonitis or advanced tendinosis because the procedure requires debridement and reinsertion of the tendon. Therefore, open surgical resection would be more appropriate in these patients. The endoscopic approach can be performed as an outpatient procedure, which removes the need for an extensile approach and is an excellent alternative to the open bone resection.<sup>6</sup>

### ***Three Portal Endoscopic Calcaneoplasty***

Endoscopic calcaneoplasty is relatively new compared to the open surgical approach, thus there have been some modifications to the technique to avoid complications and improve outcomes. The three portal technique provides access to the retrocalcaneal space, allowing better observation of the posterosuperior portion of the calcaneus and sufficient endoscopic bony resection.<sup>3</sup> In order to achieve this posterosuperior view, a proximal posterolateral portal is first made lateral to the Achilles tendon and 5 centimeters proximal to the Achilles tendon insertion. The proximal posterolateral portal seems to have a larger distance to the calcaneal prominence. Acquiring a full view of the prominence through a single portal is conducive to predicting the amount of bony resection needed.<sup>7</sup> The distal posteromedial and distal posterolateral portals are utilized in both the traditional two portal and newly proposed three portal endoscopic techniques. While the study by Wu et al supports the use of the three portal technique, several limitations were still encountered, which included not having a control group, having a small subject set, and having a short time frame for follow-up. Therefore, more studies are needed to determine

whether it yields superior clinical results when compared to the traditional endoscopic calcaneoplasty.<sup>3</sup> Further investigation of the procedure is also warranted to explore potential complications associated with the extra portal.

### ***Open Surgical Resection: Detachment and Reattachment of Achilles Tendon***

This open bone surgical approach involves the use of a medial J shaped incision, complete detachment of the Achilles tendon, debridement of the diseased tendon, excision of the retrocalcaneal bursa, resection of the retrocalcaneal exostosis, and reattachment of the Achilles tendon. DeVries et al. reviewed the outcomes of this surgical technique and indicates that the detachment and reattachment of the Achilles tendon is an effective procedure that improves function and causes pain relief. In this study, 17 patients responded to the questionnaire after the surgery, 70.6% were very satisfied, 23.5% were somewhat satisfied, and 5.9% were somewhat unsatisfied.<sup>6</sup> None of the patients needed reoperation or a revision surgery. The only major complication was a pulmonary embolism secondary to a deep vein thrombophlebitis. Minor complications included a painful scar and transient sural neuritis. This study

shows that this technique is fairly successful but it does not come without its risks.

***Open Surgical Resection: Single Incision Exposure with the use of the Kerrison Rongeur***

Open debridement of the bone can be performed through a medial or lateral incision, however, insufficient visualization when using a single incision technique has led to asymmetric bone resections. This limitation of visualization can be overcome by using a more traditional two incision approach, however the surgeon runs the risk of causing necrosis of the skin bridge between the medial and lateral exposures. Therefore, many surgeons opt for the single incision technique. This particular study focuses on the use of a single incision in combination with the use of the Kerrison rongeur. The Kerrison rongeur allows the surgeon to perform a more symmetric and adequate resection of the Haglund's deformity that avoids the risks and limitations of combined (medial and lateral incision), endoscopic, and trans-tendinous techniques[A1] . This technique also allows the surgeon to evaluate the Achilles tendon for areas of degeneration thus reducing the risk of tendon ruptures.<sup>4</sup>

***Open Surgical Resection: Keck and Kelly Wedge Calcaneal Osteotomy***

The Keck and Kelly closing wedge osteotomy is a technique that successfully decompresses the posterior-superior portion of the calcaneus without the need for dissecting around the Achilles insertion[A2] .<sup>5</sup> The healing time for this method can be faster and more predictable than the healing of the Achilles tendon at its insertion. This method is done through a lateral incision as opposed to the more traditional open surgical approaches where either a lateral, medial, or combined incision is done. Boffeli et al. stated that the Keck and Kelly should be used for patients that show a large Fowler-Philip angle (the angle that reflects the relationship between the inferior and posterior calcaneus), calcaneal inclination angle (the angle between the calcaneal inclination and the supporting surface on a weight-bearing foot), and total angle (combination of Fowler-Philip angle and calcaneal inclination angle) which occur more often in patients with a cavus foot structure[A3] . The wedge osteotomy effectively tilts the heel prominence anteriorly to decrease the heel's posterior prominence, thus producing a comparable effect to that of an Achilles tendon lengthening.<sup>5</sup> Also, the Achilles insertion is spared from scar tissue. This method is an

effective alternative for athletes or persons that do not want to deal with the complications associated with Achilles tendon detachment and reattachment.

## CONCLUSION

Haglund's deformity is a common pathology of the posterosuperior portion of the calcaneus that warrants surgical intervention if six months of conservative treatment fails to bring relief of symptoms. Although the open technique in the surgical treatment of Haglund's deformity is a well-accepted treatment, our literature review suggests that the endoscopic closed technique might lead to a faster recovery and less postoperative complications. The utilization of a three portal endoscopic technique allows for full view of the retrocalcaneal space and adequate endoscopic bony resection of the pathological posterosuperior region of the calcaneus. In addition, patients receiving the three portal endoscopic treatment did not experience any damage to the skin, nerve, and Achilles tendon that is associated with the open surgical treatment. Therefore, the endoscopic technique for treatment of Haglund's deformity yields clinical results similar to, if not superior to those of open technique.

The endoscopic technique appears to be a favorable therapy for treating

Haglund's deformity, however there are some limitations to our research. The studies supporting this conclusion are retrospective in nature, include small sample sizes, several lacked a control group and others only included a short follow-up. Further studies with a longer follow-up, control group, and larger sample sizes are necessary to determine if endoscopic treatment for Haglund's deformity has long-term symptomatic relief and provides adequate bony resection to correct the deformity.

## AUTHORS' CONTRIBUTION

The authors equally contributed to the production of this article.

## STATEMENTS OF COMPETING INTERESTS

The authors declare that they have no competing interests.

## REFERENCES

1. Vaishya R, Agarwal AK, Azizi AT, Vijay V. Haglund's Syndrome: A Commonly Seen Mysterious Condition. Muacevic A, Adler JR, eds. *Cureus*. 2016;8(10):e820. doi: 10.7759/cureus.820.

2. Michels, F., Guillo, S., King, A., et al. Endoscopic calcaneoplasty combined with Achilles tendon repair. *Knee Surgery, Sports Traumatology, Arthroscopy*. 2008; 16 (11): 1043-1046.
3. Wu, Z., Hua, Y., Li, Y., Chen, S. Endoscopic treatment of Haglund's syndrome with a three portal technique. *International Orthopaedics*. 2012;36(8):1623-1627.
4. Min, W., Ding, B.C., Sheskier, S. Technical tip: Use of the Kerrison rongeur through a single-incision exposure for resection of Haglund's deformity. *Foot & Ankle International*. 2010; 31 (11): 1028-1031.
5. Boffeli, T.J., Peterson, M.C. The Keck and Kelly Wedge Calcaneal Osteotomy for Haglund's Deformity: A Technique for Reproducible Results. *The Journal of Foot & Ankle Surgery*. 2012; 51 (3): 398-401
6. DeVries, J.G., Summerhays, B., Guehlstorf, D.W. Surgical correction of Haglund's triad using complete detachment and reattachment of the Achilles tendon. *The Journal of Foot and Ankle Surgery*. 2009; 48 (4): 447-451.
7. Ortmann, F.W., McBryde, A.M. Endoscopic bony and soft-tissue decompression of the retrocalcaneal space for the treatment of Haglund deformity and retrocalcaneal bursitis. *Foot & Ankle International*. 2007; 28 (2): 149-153.
8. Roth, K.E., Mueller, R., Schwand, E., et al. Open versus endoscopic bone resection of the dorsolateral calcaneal edge: A cadaveric analysis comparing three dimensional CT scans. *Journal of Foot and Ankle Research*. 2014; 7 (56); doi: 10.1186/s13047-014-0056-3.
9. Labib, S.A., Pendleton, A.M. Endoscopic Calcaneoplasty: An Improved Technique. *Journal of Surgical Orthopaedic Advances*. 2012; 21 (3): 176-180.



# The Classification, Diagnosis, Treatment & Prevention of Turf Toe Injuries: A Systematic Qualitative Review

Jennifer Kuinov, BS & Estelle Raad, MS, BS

## Abstract

### Introduction

The intention of this study is to perform an analysis of the current literature on the complex injury of acute turf toe. Turf toe is defined as a sprain of the big toe joint resulting from an injury during sports activities. It results from a trauma to the plantar structures of the hallux metatarsophalangeal joint, usually, due to an abnormal hyperextension, which can be caused from either jamming the toe or repetitive injury when pushing off while running or jumping. The study aims to assess the structure of diagnosis, explore the most advantageous treatment modalities, and discuss the many preventive measures to avoid this condition.

**Study design:** Systematic Qualitative Review of the Literature

### Methods

A literature search was conducted using the online PubMed database. The MeSH term “Metatarsophalangeal joint” was used and the search was narrowed down by the use of the keywords “turf toe” to give a total of 26 articles. After reviewing the articles collected, the search was further narrowed to include publications that pertain to only human subjects from the year 2000 onwards. Based on this criterion, a total of 16 articles were selected for the final literature review with regard to their relevance to the classification, diagnosis, or treatment of turf toe.

### Results

Most turf toe injuries are due to an abnormal hyperextension but other causes include hyperflexion, valgus/varus loading or dislocation injuries. Within these categories, there is a qualitative grading system of the injury that is used clinically to guide a proper treatment plan. Diagnosis of a turf toe injury is accomplished by completing a comprehensive physical exam, medical history as well as diagnostic imaging which includes fluoroscopy and MRI. These diagnostic modalities, along with the grading systems created first by Clanton and then improved upon by Coughlin (later becoming the most popular classification system) bring forth an appropriate diagnosis and a therapeutic plan because both quantitative and qualitative assessments are appraised. Treatment can be successful with RICE (rest, ice, compression, and elevation), anti-inflammatory medication for a mild injury, and a walking boot or a leg cast with a toe-spica extension, crutches, range of motions exercises, immobilization, and surgery for more advanced/serious conditions. Post-treatment care involves accommodative athletic shoes (stiff toed) with protection of an insole plate that limits dorsiflexion is also recommended with various exercises, stretches, and physical therapy.

### Conclusion

When the qualitative grading system is used in conjunction with the quantifiable classification system presented by Waldrop et al., the clinician can develop a more definitive and personalized treatment plan for that patient due to the fact that the severity of the injury to the plantar complex can be accurately assessed. In the physical examination of turf toe injury, range of motion tests are helpful in determining which ligaments of the metatarsophalangeal joint (MPJ) complex were damaged; however, radiographic methods are ultimately the most powerful in providing an accurate diagnosis. Fluoroscopy is commonly used for high-grade (Grade III or IV) injuries. However, an MRI can yield tremendous information regarding the extent of pathology. Treatment for the turf toe injury is usually conservative. When necessary, it is important to consider the possibility of surgical intervention in order to prevent subsequent damage to the joint by repositioning the joint structures and reattaching the torn ligaments. It is important to regain a full range of motion of the hallux that may have been limited following immobilization while in a brace or boot.

**Key Words:** Turf toe \*Metatarsophalangeal Joint injury\* Hallux disorders\*

*Levels of Evidence:* 4

## INTRODUCTION

Sprains or tears to the first metatarsophalangeal plantar plate are commonly referred to as a turf toe.<sup>1</sup> A turf toe injury disrupts the structures of the hallux metatarsophalangeal (MTP) joint as a result of hyperdorsiflexion (or hyperextension).<sup>1</sup> This injury was first described in football players by Bowers and Martin at the University of West Virginia in 1976 and is frequently considered as a debilitating athletic injury. There is a significant association between turf toe injuries and the advent of artificial “astro turf”, as football players (and other athletes) use shoes with increased flexibility, which increases flexibility of the MTP joint and subsequently creates more stress on the forefoot.<sup>2</sup>

### *Anatomy and Physiology*

The first MTP joint is the most important structure of the forefoot. It is essential for weight bearing, walking, athletics, and balance.<sup>1</sup> The convex head of the first metatarsal articulates with the concaved shape of the proximal phalanx. Stability is supplied mostly by the capsular-ligamentous sesamoid complex, which includes the medial and lateral collateral ligaments, each composed of an MTP ligament and metatarsos-sesamoid ligament that aid in cutting motion activities. The capsular-ligamentous complex is also comprised of the flexor hallucis brevis

muscle, the adductor hallucis muscle, the abductor hallucis tendon, and the plantar plate.<sup>3</sup> The strong fibrous structure of the plantar plate forms an attachment from the proximal phalanx through the joint capsule to the neck of the metatarsal. An undamaged capsular-ligamentous sesamoid complex provides the push-off force of the hallux, which is generally required by a variety of run-oriented sports.

### *Biomechanics and Pathogenesis of Turf Toe*

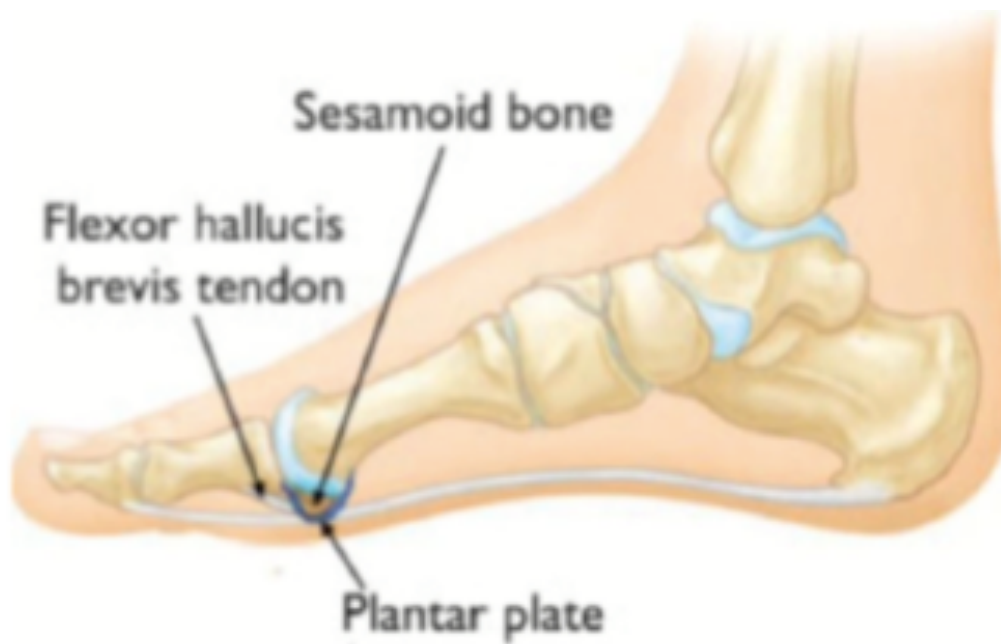The hallux has the capacity to perform an extended range of motion (ROM) at the 1<sup>st</sup> MTP joint that enables the joint to immediately transmit weight-bearing loads and provide positional changes from maximum plantarflexion to moderate dorsiflexion.<sup>1</sup> The capsuloligamentous soft tissue structures about the 1<sup>st</sup> MTP joint provide stability to the joint in relation to varus and valgus stabilizing forces.<sup>4</sup> The two sesamoid bones embedded within the flexor hallucis brevis tendons provide a fulcrum point to assist the kinetic energy of muscles that traverse the joint.<sup>1</sup>

Based on review of literature, external manipulation of the big toe generates a total passive ROM of roughly 110 degrees, which is the sum of approximately 75 degrees dorsiflexion and 35 degrees of plantarflexion.<sup>5</sup> Active ROM is recognizably less, however, it important to highlight that ROM ordinarily decreases with age.<sup>2</sup>

Three main types of injury mechanisms have been observed: (1) hyperdorsiflexion, (2) hyperflexion, and (3) valgus/varus loading. A study by Rodeo et al. observed 80 active professional football players. Their trainers found that among the 45% of players with turf toe, 85% of injury was due to hyperextension. Thus, the most common mechanism of injury of the big toe is dorsiflexion beyond its biomechanical limits; hyperflexion is the second most common mechanism of injury and valgus/varus being the least noted.<sup>6</sup> Injury can range from a minor sprain to a major dorsal dislocation of the toe. Variants include, position of hallux, direction of force, valgus (most common), injury of medial and plantar-medial ligamentous structures, and tibial

sesamoid complex. Correlation of injury to physiology and situational factors include playing on artificial surfaces, evolution of shoe wear, player-specific characteristics and anatomic factors.<sup>2</sup>

Acute turf toe is distinguished from its chronic counterparts (hallux limitus and hallux rigidus) based on the mechanism of injury. The cause of turf toe injury is basically hyperextension of the first MTPJ, which results in a sprain of the plantar joint capsule or sometimes a potential tear or rupture of the plantar capsule and ligaments. Meanwhile, functional hallux limitus refers to biomechanical features of the joint, which effectively limit dorsiflexion. Excessive pronation, a long first metatarsal, and several other



**Figure 1:** Several structures work together to protect and stabilize the MTP joint.  
© 1996 Cyndi Slagel

factors may play a role in the development of a functional hallux limitus. No degenerative changes show up in this condition. It is thought to be one of many possible etiological factors of hallux rigidus, or the complete absence of dorsiflexion at the first metatarsophalangeal joint.<sup>7</sup> The possible biomechanical etiologies for hallux rigidus include, as previously stated, functional hallux limitus, functional hypermobility of first ray, gastrocnemius-soleus equinus, compensated forefoot valgus, and excessive rear foot pronation; all of which alter an individual's ambulation.<sup>7</sup>

### ***Clinical Presentation and Physical Examination***

Turf toe is typically an unrecognized injury. The patient experiences pain at the hallux MTP joint and it may be isolated to the plantar aspect of the big toe. It is common for the examiner to suspect an osteochondral joint injury because osteochondrosis is yet another reason for sesamoid pain.<sup>8</sup> Upon physical examination, the athlete may present with a limp or antalgic gait when they jog or walk. External rotation of the big toe may reduce discomfort while plantar flexion strength is decreased. Distal to the sesamoids, there may be an incomplete or complete disruption of the plantar plate. When the drawer test is performed, it will likely show instability of the joint.<sup>2</sup>

## **METHODS**

A literature search was conducted using the online PubMed database. The search was done using the Boolean "AND" and "OR" operators. There were no MeSH term found for the condition "turf toe" and therefore the MeSH term "Metatarsophalangeal joint" was used yielding 2048 total articles. The search was narrowed down by adding the keywords "turf toe" to yield a new total of 26 articles. Articles in other languages beyond English were omitted. Articles including non-human subjects and those published before the year 2000 were also excluded. After sifting through search results, 20 articles met the inclusion and exclusion criteria. After reviewing the abstracts to obtain relevant studies regarding the various classification schemes in order to suitably diagnose, treat, and prevent turf toe, 16 of the 20 articles were selected for the final literature review.

## **RESULTS**

### ***Classification***

In 2007, Clanton et al. were the first to propose a classification system for the turf toe injury. In this classification system, the injury is first categorized by hyperextension, hyperflexion, or dislocation injuries. The hyperextension injury is then further classified into three grades. Grade I injuries include stretching of the soft tissues of the first MTP joint without any tears. In a Grade I injury, the patient would present with medial or

plantar tenderness or swelling. These patients would still be going about their day, able to perform routine function with mild amounts of pain or discomfort. Grade II injuries include partial tear of the soft tissues of the first MTP joint. In a Grade II injury, the patient would present with more intense tenderness and intense swelling in addition to mild to moderate ecchymosis. Grade III injuries include more marked tear of the soft tissues of the MTP joint in addition to possible bone injuries such as a fractured sesamoid or a medial or plantar bone bruise. In a Grade III injury, the patient would present with moderate to severe tenderness, swelling, and ecchymosis as well as a limited range of motion.

In 2013, Waldrop et al. proposed a quantifiable classification system for the turf toe injury. In this system, the injury was classified based on how many of the 4 main ligaments of the MTP joint were injured. The 4 ligaments include the medial collateral ligament, the tibial phalangeal sesamoid ligament, the fibular phalangeal sesamoid ligament, and the lateral collateral ligament. The injury classification was accomplished by taking X-rays of the MTP joint during dorsiflexion and measuring the distance between the sesamoids and the proximal phalanx. If this distance was  $>3$  mm, the injury consisted of a rupture of 3 out of the 4 main ligaments. If during dorsiflexion, the sesamoids did not move with the proximal phalanx, the injury consisted of a rupture of all 4 main ligaments.

In 2015, Coughlin et al. proposed a classification system for the turf toe injury with 4 grades. This system is a modification of the system proposed by Clanton et al., 2007; however, this system introduced a Grade IV. Grade IV injuries included a complete tear of the MTP joint soft tissues with injury to the articular cartilage and bone. In a Grade IV injury, the patient would present with severe tenderness, swelling and a very limited range of motion.<sup>6</sup>

### ***Diagnosis***

Diagnosis of the turf toe injury is made by performing a complete and thorough history taking, palpation exams, ROM exercises, and radiographic evaluation. The radiographic evaluations can be carried out by X-ray to visualize the bony structures of the joint and by MRI or fluoroscopy to visualize the soft tissue structures of the joint. After completing a comprehensive assessment, a grade can be assigned to the patient's injury in accordance to one or more of the above-mentioned classification systems.

### ***Treatment***

The first approach to turf toe injury is conservative such as RICE (rest, ice, compression, and elevation), anti-inflammatory medication, immobilization by means of a boot, toe-spica, or crutches and range of motion exercises. Gentle ROM exercises are appropriate for grade 1 and 2 injuries beginning at 3-5 days after the injury. A grade 3 injury will only be exercised depending on the

patient's symptoms. If conservative treatment is deemed unsuccessful, a therapeutic steroid injection comprised of Celestone (betamethasone) or Solumedrol (methylprednisolone) may be given.<sup>9</sup> Moreover, surgical intervention could be an option and would most commonly be realized with a 'J' cut approach in which the medial incision is extended horizontally across the hallux MTP flexion crease. This approach would be considered a mode of treatment for a patient if they had grade III or IV injury.<sup>2</sup> This is the more common approach since injury is most commonly to the medial ligamentous structures, however, if there is injury to structures on both sides of the joint, a dual incision approach is used for appropriate access. If medial structures are injured due to a hallux valgus deformity, a percutaneous adductor tenotomy is done in addition to the medial ligamentous repair. Ultimately, rehabilitation would be required after the surgery consisting of gentle passive ROM 5-7 days after the surgery and continuing to active ROM of the joint at 4 weeks when a patient starts protective weightbearing.<sup>8</sup>

## DISCUSSION

### *Classification*

The classification system presented by Clanton et al., consists of three grades that range from mild to more severe forms of injury. This system was later upgraded by Coughlin et al., in order to include a fourth gradation for the most severe form of injury. This

classification system is currently being used by physicians. The disadvantage of this system is that it is a qualitative system. There is a lot of variation in turf toe injuries, which make it difficult to provide an accurate assessment. Proper diagnosis and assessment of the injury is crucial in determining the patient's treatment plan.<sup>10</sup> When a patient is not treated correctly, their minor injury can result in a complete plantar plate rupture and retraction of the flexor hallucis brevis tendon in as short as only one month's time.<sup>4</sup>

The quantifiable classification system presented by Waldrop et al., can help in providing more accurate diagnoses.<sup>10</sup> However, the limitation of this classification system is that it is only helpful in more severe injuries and it requires the use of radiographic evaluation which may not be viable in a short time frame.

The most accurate assessment can be accomplished by using both classification systems in conjunction with each other. By using this method, the best treatment plan can be determined for each individual patient.

### *Diagnosis*

The extent of injury must be assessed on many levels. First, a proper history must be taken. This will help to identify what type of turf toe injury has occurred. Next, the physician must observe the hallux for ecchymosis and swelling. The MTP joint must also be palpated for the presence of the joint capsule, collateral ligaments, and plantar structures. Next, a series of

Grade of Injury	Objective Findings	Level of Sports Activity	Patterns of Injury	Treatment
1	<ul style="list-style-type: none"> <li>Localized medial or plantar tenderness</li> <li>Minimal to no swelling</li> <li>No ecchymoses</li> </ul>	Continue sports participation	Sesamophalangeal ligamentous complex sprain	Stiff insert (graphic insole) Symptomatic treatment
2	<ul style="list-style-type: none"> <li>Mild to moderate tenderness</li> <li>Moderate swelling and ecchymosis</li> <li>Painful and limited range of motion</li> </ul>	Diminished playing time (0-3 weeks)	Partial tear of the metatarsosesamoid complex	Taping of toe, stiff insole Non-weight-bearing in a Cam walking boot optional Plain radiographs warranted (MRI possible)
3	<ul style="list-style-type: none"> <li>Diffuse, severe tenderness</li> <li>Marked swelling</li> <li>Moderate to severe ecchymosis</li> <li>Painful range of motion</li> <li>Plantar pain more typical</li> </ul>	Loss of playing time (3-12 weeks)	More substantial or complete tear of the ligamentous complex  Possible sesamoid fracture or separation of bipartite sesamoid  Possible dislocation/redislocation of the MTP joint	Longer-term immobilization (6-12 weeks) with Cam walking boot or cast  Plain radiographs, MRI imaging  Portable surgical repair
4	<ul style="list-style-type: none"> <li>Severe swelling</li> <li>Severe tenderness</li> <li>Range of motion limited (dorsal) and plantar pain</li> </ul>	Possible career-ending injury	Complete tear of the capsule ligamentous complex  Articular cartilage and subchondral bone injury	Plain radiographs  MRI imaging  Surgical repair of plantar complex but guarded prognosis due to articular injury

ROM exercises must be done on the MTP joint of both the patient's right and left foot to evaluate any abnormalities in the injured toe compared with the non-injured side. Lastly, radiographic evaluation must be done. Diagnostic imaging may be done with X-ray, MRI, or most commonly, fluoroscopy.<sup>3</sup> The X-ray is useful in observing the bony structures while the MRI and fluoroscopy are useful in evaluating the soft tissues. A T1 MRI is recommended by Crain et al., in order to get the clear visualization of the ligaments and tendons, thus the grade of the injury can be most accurately determined to find the best treatment procedure for the patient. Fluoroscopy has become

the most common imaging modality due to the lower price compared with an MRI and its ability to image more than an X-ray. Using MR imaging will still give the most information about the stage of the injury and is therefore used when the staging is important such as knowing when an athlete can return to their sport or knowing what surgical procedure would benefit a patient.<sup>10</sup> MRIs are also important in order to rule out other possible injuries, such as Freiberg's infarctions, arthritis, or other soft tissue processes.

12

Both soft tissue and bony structures need to be visualized when grading a turf toe injury. Visualizing the soft tissues is important in assessing whether the damage has impacted the soft tissue structures.<sup>11</sup> It is also important to visualize the bony structures of the 1<sup>st</sup> MTP joint to observe the possibility of a fracture or diastasis of the sesamoids. It is suggested that the X-ray be performed weight-bearing on an AP view. If necessary, a lateral view can be rendered afterwards as well.<sup>13</sup> A bipartite sesamoid may be normal in the patient or it may be associated with the injury. Research on the bipartite sesamoid interval indicates that if the interval separating the bones is more than 2mm and the patient has a history of turf toe injuries, then the diastasis of the sesamoids was likely to have been caused by the injury.<sup>14</sup>

Visualizing the bony structures may also give the physician information on the integrity of the plantar plate as well as inform the physician how many of the ligaments of the MTP joint were disrupted. It has been suggested that if the tibial and fibular sesamoids are greater than 10.4mm or 13.3mm from the proximal phalanx, then there is a 99.7% chance of plantar plate rupture.<sup>3</sup> Using the system presented by Waldrop et al., the distance between the sesamoids and the proximal phalanx during dorsiflexion can give the physician information about the integrity of the MTPJ ligaments. If the distance reported is >3mm, there was a rupture of 3 out of the 4 ligaments and if the

sesamoids don't move with the proximal phalanx, there was a rupture of all 4 ligaments.<sup>10</sup>

### ***Treatment***

Conservative treatment includes RICE for initial treatment as suggested by Clanton and Ford.<sup>13</sup> Nonsteroidal anti-inflammatory drugs are advisable. Grade I injured athletes can normally continue playing sports post injury. To restrict motion, taping may be used to stabilize the joint or rather a shoe insole is recommended. Grade II injuries do result in time lost from playing time; care plan involves a minimum of 3 days (up to 3 weeks) of rest with the same treatment protocol used for a Grade I injury. Grade III injury is a more severe injury to the hallux MTP joint. Long-term immobilization is prescribed (cast, cam walker boot, toe-spica or crutches).

Coughlin incorporated a Grade IV injury, the most severe form of turf toe. This addition improves diagnosis because it extends beyond the complete tearing of the tendon to comprise serious damage to both the bone and cartilage, which is important. Osteocartilaginous injuries may lead to joint chondrolysis, therefore drastically changing the treatment plan.<sup>2</sup> Coughlin's grading scheme, consequently, is perceived to be more thorough than its predecessor. It is suggested that if conservative treatment has failed, therapeutic corticosteroid injection can be prescribed in the treatment of turf toe.<sup>9</sup>

Surgical treatment is seldom



necessary. However, when there is a complete rupture of the plantar plate, surgical intervention is necessary.<sup>15</sup> Other indications for surgical treatment include: cartilage flap or loose body within the hallux MTP joint, sesamoid fracture, separation of a bipartite sesamoid, proximal migration of sesamoids, instability, and hallux rigidus. In surgical repair of the joint, a J-incision technique is most commonly used. For sesamoid fracture, the presence of a diastasis of a bipartite sesamoid suggests the preservation of 1 pole of the sesamoid. The goal is to restore normal anatomy and regain the stability and function of the plantar capsular ligamentous complex of the hallux MTP joint.<sup>8</sup>

### ***Postoperative Management***

Postoperative management is challenging. Assistance from a physical therapist or athletic trainer is often necessary and it is also recommended to use postoperative external immobilization modalities such as a bunion splint (when toe is at rest), a removable posterior splint or cast boot. The patient should be guided in non-weight bearing ambulation (about 4 weeks), and then given an accommodative athletic shoe with protection of an insole plate (stiff sole) that limits dorsiflexion.<sup>8</sup> Although uncommon, it is worth noting that caution should be taken with prolonged use of stiffened toe shoes or stiffened insole to protect the forefoot. A study by Hall and Nester shows that a decrease in first MPJ dorsiflexion motion leads to sagittal plane compensations at the ankle

joints, knee joint and hip joints; thereupon creating instability of the knee, increased tension on the ankle joint structures, most importantly the Achilles tendon, and the possible development of positional symptoms at the hips during long term use of these products.<sup>16</sup> Active ROM exercises should be used as an assessment 3-4 months post-operatively to observe the healing progress. Eventually, the patient should be allowed to return to contact activity, with most patients returning to pre-injury level.<sup>13</sup> Regrettably, if the patient is noncompliant with treatment, then the condition may decline into hallux limits or hallux rigidus. This decreased ROM due to arthritis around the joint can cause eventual problems to the entire foot or lower limb due to changes in the gait cycle.

### ***Prevention of Turf Toe***

It has been suggested that athletic shoes should be made with steel shanks to limit the amount of dorsiflexion that can happen while running. The problem with this is that it will also prevent a motion that is needed for the athlete. Frimenko et al. did a study to find the angle of dorsiflexion that the turf toe injury usually occurs at. The study found that 50% of injuries occur at 78 degrees of hallux dorsiflexion.<sup>5</sup> Although one may not be able to completely avoid this injury, the occurrence can be minimized by wearing properly fitting, supportive footwear with soles rigid enough for protection. If at all possible, avoid playing on unkempt

sports fields. Furthermore, a good warm-up regime can improve an individual's chances to stave off turf toe. This includes toe walks and inverted hamstring stretches, muscle strengthening (resistance and balance exercises), range of motion exercises, and manual therapy for the foot and ankle.

## CONCLUSION

Turf toe injuries are onerous because of the multitude of sources that exist as the cause of the pain. By utilizing a systematic approach to evaluation, injuries to the hallux MTP joint can be diagnosed properly, leading to exact and effective treatment. When conservative treatment is unsuccessful, operative interventions are procurable to relieve pain and restore function. Coker et al. reported that the most common long-term complaints from surgical intervention were joint stiffness and pain with physical activity.<sup>8</sup> Thus, with vigilant surgical technique and proper postoperative management, such as appropriate preventative athletic shoes, patients can return to play at or near their pre-injury state.

## Authors' Contributions

All authors contributed equally to the composition of this literature review. Both authors drafted, read, reviewed and agreed upon the final manuscript

## Statement of Competing Interests

The authors declare that they have no competing interest associated with this manuscript.

## REFERENCES

1. Childs SG. The pathogenesis and biomechanics of turf toe. *Orthop Nurs*. 2006 Jul-Aug;25(4):276-80.
2. Coughlin MJ, Kemp TJ, Hirose CB. Turf toe: soft tissue and osteocartilaginous injury to the first metatarsophalangeal joint. *Phys Sportsmed*. 2010 Apr;38(1):91-100.
3. McCormick JJ, Anderson RB. The great toe: failed turf toe, chronic turf toe, and complicated sesamoid injuries. *Foot Ankle Clin*. 2009 Jun;14(2):135-50.
4. Allen LR, Flemming D, Sanders TG. Turf toe: ligamentous injury of the first metatarsophalangeal joint. *Mil Med*. 2004 Nov;169(11):xix-xxiv.
5. Frimenko RE, Lievers WB, Riley PO, Park JS, Hogan MV, Crandall JR, Kent RW. Development of an injury risk function for first metatarsophalangeal joint sprains. *Med Sci Sports Exerc*. 2013 Nov;45(11):2144-50.
6. Frimenko RE, Lievers W, Coughlin MJ, Anderson RB, Crandall JR, Kent RW. Etiology and biomechanics of first metatarsophalangeal joint sprains (turf toe) in athletes. *Crit Rev Biomed Eng*. 2012;40(1): 43-61.
7. Roukis, T. S., P. M. Jacobs, et al. (2002). "A prospective comparison of clinical, radiographic, and intraoperative features of hallux rigidus." *J Foot Ankle Surg* 41(2): 76-95.
8. McCormick JJ, Anderson RB. Rehabilitation following turf toe injury and plantar plate repair. *Clin Sports Med*. 2010

Apr;29(2):313-23.

9. Tallia AF, Cardone DA. Diagnostic and therapeutic injection of the ankle and foot. *Am Fam Physician*. 2003 Oct 1;68(7):1356-62.

10. Waldrop NE 3rd, Zirker CA, Wijdicks CA, Laprade RF, Clanton TO. Radiographic evaluation of plantar plate injury: an in vitro biomechanical study. *Foot Ankle Int*. 2013 Mar;34(3):403-8.

11. Crain JM, Phancoo JP, Stidham K. MR imaging of turf toe. *Magn Reson Imaging Clin N Am*. 2008 Feb;16(1):93-103.

12. Wilson L, Dimeff R, Miniaci A, Sundaram M. Radiologic case study. First metatarsophalangeal plantar plate injury (turf toe). *Orthopedics*. 2005 Apr;28(4):344, 417-9.

13. Watson TS, Anderson RB, Davis WH. Periarticular injuries to the hallux metatarsophalangeal joint in athletes. *Foot Ankle Clin*. 2000 Sep;5(3):687-713.

14. Favinger JL, Porrino JA, Richardson ML, Mulcahy H, Chew FS, Brage ME. Epidemiology and imaging appearance of the normal Bi-/multipartite hallux sesamoid bone. *Foot Ankle Int*. 2015 Feb;36(2):197-202.

15. Anandan N, Williams PR, Dalavaye SK. Turf toe injury. *Emerg Med J*. 2013 Sep;30(9):776-7.

16. Hall C, Nester CJ. Sagittal plane compensations for artificially induced limitation of the first metatarsophalangeal joint, a preliminary study. *JAPMA* 94(3):269-274, May/June 2004.

# Comparison of Surgical Techniques for Charcot-Marie-Tooth

Mohammed Gheith, BA & Rowan Mahmoud, BS

## Abstract

### Introduction

Charcot-Marie-Tooth disease (CMT) is the most common inherited neuropathy in the United States. The disease has a progression of symptoms that become more severe with time. One of its main symptoms is a cavus foot, with the cavovarus foot type being the most common. This presents with a plantarflexed foot and a varus heel. There are different surgeries available to treat a cavovarus foot depending on the severity of the deformity, age of the patient, and the flexibility of the foot. Typically, soft-tissue surgeries are used early in the disease when the foot is relatively flexible and the deformity is mild. If soft-tissue surgery is ineffective, the disease continues to progress and the foot becomes more rigid, an osteotomy can then be used in conjunction with soft-tissue procedures. Osteotomies are performed on the calcaneus, midfoot and metatarsals dependent on the level or levels of deformity. An arthrodesis is used when a cavovarus foot persists after previous procedures, symptoms are severe, and there are significant signs of degenerative changes. The purpose of this study is to evaluate the surgical techniques performed to correct malformations in the foot caused by cavovarus foot associated with CMT.

**Study design:** Systematic Qualitative Review of the Literature

### Methods

The authors conducted an English only literature search using PubMed with the term “Charcot-Marie-Tooth Disease AND surgery AND cavovarus” and another search with the term “Charcot-Marie-Tooth Disease AND surgery AND cavus.” The inclusion criteria comprised of adult human CMT patients, pes cavus, foot and ankle fusions, triple arthrodesis, and minimally invasive treatment. Exclusion criteria were non-surgical interventions, follow up procedures, hindfoot equinus, pes planovalgus foot type, non-CMT cavus or idiopathic cavus, foot drop correction, nerve biopsies, minimally invasive, neuropathy or polyneuropathy management, short term procedures, studies done on adolescents, and an English filter was applied.

### Results

Six papers that include a case study and case series were used in this systematic literature review.

### Conclusion

Choosing an effective surgical treatment for a CMT cavovarus foot needs to be determined by several parameters which includes the severity of the deformity and symptoms. An ideal procedure will be one that preserves joint mobility. A flexible cavovarus foot can be successfully treated with soft-tissue surgeries like plantar fasciotomy and tendon transfers early on in the disease. The rigid cavovarus foot will most likely require treatment with a combination of osteotomies and soft tissue procedures. The more severe forms of a rigid cavovarus may require arthrodesis. Unfortunately arthrodesis will sacrifice function. Generally a combination of techniques will be required to treat CMT cavovarus foot with successful results.

**Key Words:** Charcot-Marie-Tooth disease, surgery, cavovarus, and cavus.

*Levels of Evidence:* 4

## INTRODUCTION

In the United States the most common inheritable neuropathy in the general public is Charcot-Marie-Tooth disease (CMT).<sup>1</sup> It has an incidence of 1 in 2,000 people in the United States.<sup>2</sup> There are multiple classifications for CMT, with the most common classification based on chromosomal abnormalities. This classification divides CMT into CMT1 and CMT2, which are both inherited as autosomal dominant.<sup>3</sup> CMT1 affects more than half of the CMT patient base and is associated with pathologies including decreased nerve conduction velocities due to demyelination and a cavovarus foot.<sup>3,4</sup> An earlier classification of CMT was created by Dyck and Lambert. This classification uses electrophysiologic characteristics to divide the condition into Hereditary Motor Sensory Neuropathies (HMSN) I-VII. The Dyck and Lambert classification is based on the degradation of neural tissue present in CMT.<sup>4</sup> The defective myelin sheath causes muscle atrophy and imbalance in patients who suffer from CMT1.<sup>5</sup> Axon degeneration is the prime cause of disease in CMT2 patients, who comprise approximately 20% of the CMT patient base.<sup>4,6</sup> Like CMT1, the symptoms for CMT2 involve progressive muscle atrophy of the lower extremities.<sup>6</sup> Since the majority of patients who suffer from CMT have the type 1 disease, this paper will focus on CMT1 in order to provide a more streamlined evaluation of surgical treatments and outcomes.

Cavovarus foot is the main foot type associated with CMT. It is a condition that exhibits plantarflexion of the forefoot which results in a high arch and varus of the heel. Symptoms can include instability of lower extremities, difficulty walking, shoe fit and wear issues, ulcers, fractures, and calluses.<sup>7</sup> The deformities associated with cavovarus foot will worsen over time if the patient does not receive the proper medical care throughout the lifetime of his or her illness.<sup>8</sup> There is a symptomatic spectrum for cavovarus foot that correlates with the severity of symptoms.<sup>8</sup> The clinically manageable type is defined by its flexibility and a less longitudinally high arch form of the cavovarus foot. This type does not usually result in ulcers and movement impairments.<sup>8</sup> The more extreme form is the rigid type of cavovarus foot that can cause more serious problems for patients, and usually requires surgical correction to restore normal function of the lower extremities.<sup>8</sup> The more flexible forms of cavovarus foot can be treated with soft-tissue surgeries, like plantar fasciotomy and tendon transfers which tend to be less invasive.<sup>9</sup> Late-stage cavovarus tend to be rigid in nature with more severe symptoms. The rigid form generally are treated with more traditional and invasive surgeries including osteotomies and arthrodesis.<sup>9</sup>

Pes cavus describes a structurally high arch foot. Its ability to lower on weight bearing will determine what symptomatology the patient will present with. Its usual pathology occurs due to a strong peroneus

longus (PL) muscle and a weak anterior tibial muscle that results in a plantarflexed first metatarsal.<sup>4</sup> The peroneal brevis (PB) is weakened by the disease and is overpowered by the tibialis tendon. The foot over extends longitudinally and elevates the arch. This will result in the subtalar joint tilting into a varus position.<sup>4,8</sup> In addition to this sequence set off by muscle imbalance, the windlass mechanism that tightens the plantar fascia will also have an effect on raising the height of the foot arch.<sup>4</sup> An abnormally high calcaneal pitch angle can also cause a high arch, but it is more associated with the hindfoot driven cavus foot whereas classically the traditional type of cavus foot is usually forefoot driven. Clinical manifestations of pes cavus can include ulcerations, calluses, difficulty walking, inability to fit into shoes and instability.<sup>4</sup>

The hindfoot varus is partly due to muscle imbalance, as one muscle weakens, its antagonist will overpower it and cause the deformity.<sup>9</sup> Hindfoot varus occurs indirectly as the PL muscle overcompensates for a weak anterior tibial muscle and causes a deforming forefoot position.<sup>4</sup> Hindfoot varus is due to the tripod effect, the forefoot position will lead to a compensatory hindfoot varus. Due to the forefoot pronation the foot must be plantargrade and this occurs by supination of the rearfoot. The posterior tibial muscle works to invert at the subtalar joint, offsetting the overactive PL and weak PB, which results in a varus of the heel.<sup>4</sup> Hindfoot varus makes the patient

vulnerable to inversion injuries of the ankle, especially when the stabilizing force in the peroneus brevis muscle is diminished as the CMT disease progresses.<sup>4</sup> A distinction between hindfoot being flexible or rigid needs to be preformed to dictate the need of calcaneal osteotomies. In addition to pes cavus and hindfoot varus, foot drop can also result from the weakening of the anterior tibial muscle, so it is also likely to be found in patients suffering from CMT disease.<sup>4,5</sup>

Non-surgical approaches like orthotics are limited as cavovarus foot progressively worsens with time. Orthotics intended to correct the early symptoms are not able to fix the later symptoms, which are more rigid and related to other serious complications like ulcers and walking impairments.<sup>8,9</sup> The orthotics are also not able to impede the progression of the disease in CMT patients. So non-invasive treatment often do not improve the quality of life for the patient in the long term. Nonsurgical intervention, however, can be effective in enhancing quality of life. Proceeding with surgery is dependent on many factors including the effectiveness of bracing, depending on the needs of the patient.<sup>4</sup> Surgical techniques are reserved for a CMT patient with severe symptoms or when non-invasive techniques have been exhausted.

Soft-tissue procedures are available to treat flexible deformities of the foot, and can be combined with more reconstructive surgeries like

osteotomies to achieve a reduction of foot deformities for the CMT patient.<sup>4</sup> Plantar fasciotomy is a soft tissue procedure used to accomplish maximum elevation of the first ray. The procedure decreases the height of the arch seen in cavovarus foot.<sup>4,9</sup> Plantar fasciotomy involves making a transverse plantar incision distal to weight bearing surface of heel, next to the plantar fascia origin, releasing the plantar fascia. The incision should be cut to the depth of the underlying muscle but does not include releasing 1<sup>st</sup> layer of the muscles.<sup>4,9</sup> Plantar fasciotomy is often used with PL tendon transfer.<sup>9</sup> Tendon transfer, another soft-tissue procedure, is a technique that changes the insertion point of a tendon, but retains its origin. It is used to treat CMT, with an example being the use of a braided composite suture surgical technique with the PB and PL tendons. The PL is transected under the cuboid and joined with PB. The muscles are anastomosed to correct the high arch of cavovarus foot. This tendon transfer procedure will release the plantarflexion force on the first ray, helping increase the eversion of PB.<sup>9</sup> Another minimally early invasive technique includes the Hibbs and Jones technique. The Hibbs EDL tendon transfer creates a 3-cm incision over the lateral cuneiform and a Keith needle is used to do a 3-0 braided composite suture to bundle 4 EDL tendons together.<sup>9</sup> The Krackow suture technique is used to fix the size of the tendons to make them more prime for transfer.<sup>9</sup> The tendons are then transferred into the lateral cuneiform by using a bioabsorbable interference

screw to drill a hole for exposure.<sup>9</sup> For Jones EHL tendon transfer a dorsal incision is made over the first metatarsal, and a bioabsorbable interference screw is used to anchor the tendon so it can be placed dorsally to plantarly through the first metatarsal.<sup>9</sup> Subsequently, the EHL tendon is transplanted into the first metatarsal head.<sup>9</sup> The Hibbs tendon transfer proves successful in removing the retrograde buckling forces of the extensor substitution on the toes while preserving ankle dorsiflexion.<sup>9</sup> There are more soft-tissue surgeries that can be employed, but the two most common and effective for CMT are plantar fasciotomy and tendon transfer.

Osteotomy is a procedure that can shorten, lengthen, or change the alignment of a bone to correct anatomical deformities. The approach to which osteotomy procedure is performed is dependent on various factors including apex flexibility and age. Realignment of the foot deformity is the goal, but there can be significant shortening with osteotomies that can create issues.<sup>10</sup> For CMT patients it is usually reserved for use after soft-tissue surgeries that have proved ineffective on their own. Subsequently, the osteotomy is usually used in conjunction with the soft-tissue procedures to attain better results in reducing foot malformations.<sup>3,4</sup> There are a multitude of osteotomy procedures that are employed, with the most common being the Dwyer calcaneal, dorsiflexion, Cole midfoot, and closing wedge osteotomies.<sup>3,4,8,11</sup>

Importantly, they all accomplish the same treatment, which is either a shortening, lengthening, or changing of bone alignment that corrects the foot.

Triple arthrodesis is a procedure that fuses the three main joints of the hindfoot. The subtalar, calcaneocuboid, and talonavicular joints can be fused in an effort to correct the deformities caused by CMT.<sup>12</sup> The efficacy of this surgery is still unresolved, but most surgeons agree that it is a viable option for CMT patients when they present with rigid feet with arthrosis and significant symptoms like ulcerations, instability, pain and abnormal gait. Arthrodesis may be required due to failure of prior interventions such as prior soft-tissue procedures or osseous procedures.<sup>4,13,14</sup>

Deciding which of the aforementioned types of procedures to use for treatment of CMT requires physician assessment of each individual patient by considering symptom severity and disease progression.<sup>4</sup> The more flexible the foot deformity, the higher chance that there is for a successful surgery, and likewise the more severe the deformity, the lower the chance for a correction.<sup>4</sup> There is also an associated risk with performing surgery on a foot that exhibits more progressive disease, like rigid cavovarus and ulceration.<sup>9</sup> There is a spectrum for CMT that can help guide surgical options based on symptoms. A more supple and flexible foot can receive successful treatment from

soft-tissue procedures, whereas a rigid cavovarus foot would instead have reconstructive surgeries for reduction of foot malformations. A basic treatment protocol based on a symptomatic spectrum for CMT is described in Table 1.<sup>4</sup>

## METHODS

Two literature searches were conducted on PubMed. The first search used the term “Charcot-Marie-Tooth Disease AND surgery AND cavovarus” to yield 33 articles. The second search used the term “Charcot-Marie-Tooth Disease AND surgery AND cavus” to yield 40 articles. Overall the two search terms yielded 73 articles. The inclusion criteria included adult human CMT patients with pes cavus that required surgical intervention such as foot and ankle fusions, triple arthrodesis, and minimally invasive treatment. Exclusion criteria were non-surgical interventions, follow up procedures, hindfoot equinus, pes planovalgus foot type, non-CMT cavus correction or idiopathic cavus, foot drop correction, nerve biopsies, minimally invasive, neuropathy or polyneuropathy management, short term procedures, studies done on adolescents, and an English filter was applied. After applying all aforementioned inclusion and exclusion criteria, six papers were included in this review.



Table 1: Treatment Options for CMT Based On Symptoms

Deformity	Imbalance	Surgical solution		
Ankle equinus	Weak anterior tibial, persistent gastrosoleus	Supple foot drop	Fixed deformity	Arthritic ankle
		Bracing; posterior tibial transfer to third cuneiform	Achilles tendon lengthening; fractional gastrocnemius lengthening	Arthrodesis
Hindfoot varus	Weak peroneus brevis, persistent posterior tibialis	Flexible, fully correctable	Fixed	Severe deformity
		First ray correction; fractional lengthening of posterior tibial	Dwyer calcaneal osteotomy	Triple arthrodesis
Plantarflexion of 1 <sup>st</sup> ray (forefoot cavus)	Weak anterior tibialis, persistent peroneus longus	Flexible deformity	Fixed	Arthritic 1 <sup>st</sup> Tarso-meta-tarsal
		Peroneus longus to brevis transfer	Dorsiflexion osteotomy of first metatarsal	1 <sup>st</sup> Tarso-meta-tarsal arthrodesis
Hindfoot cavus (high calcaneal pitch)	Weak foot, short toe flexors, persistent long toe flexors	Flexible	Fixed	Arthritic hindfoot
		None	Plantar fascia release; calcaneal osteotomy	Triple arthrodesis
Dorsiflexed clawtoe of hallux	Weak anterior tibialis, persistent gastrosoleus	All cases		
		Extensor hallucis longus muscle transfer to first metatarsal, IP fusion of hallux (Jones procedure)		

## RESULTS

### *Soft tissue procedure*

In the case report by Boffeli et al., there is a discussion on the benefits of early-intervention soft-tissue procedures for CMT patients instead of late-stage reconstructive surgeries such as osteotomies and arthrodesis. This paper included two patients and compared the early intervention, soft-tissue approach with the late-stage approach.<sup>9</sup> One patient received only early soft-tissue surgeries, including a plantar fasciotomy and Hibbs and Jones tendon transfers. The second patient received only late-stage reconstructive surgeries.<sup>9</sup> The aim of each case was to achieve a plantigrade foot.

The first patient was an 18 year-old male with progressive and flexible pes cavus owing to CMT.<sup>9</sup> The patient experienced pain in the foot, had difficulty walking, and suffered from plantar ulcerations beneath the fifth metatarsal, even with bilateral employment of ankle and foot orthotic bracing (AFO).<sup>9</sup> The patient had ankle equinus, drop foot, weak eversion strength, hammertoe contracture of all digits, flexible cavus foot, and sensory neuropathy that were all observed bilaterally.<sup>9</sup> Weight-bearing radiographs were normal, largely because the cavus foot is flexible.<sup>9</sup> These symptoms, which lean toward the more flexible and lesser deformed part of the aforementioned symptomatic spectrum, allowed this patient to receive early intervention

soft tissue procedures that involved plantar fasciotomy, tendon Achilles lengthening, transfer of PL to the fifth metatarsal, Hibbs and Jones tendon transfers, and hammertoe repair of digits 1 to 5.<sup>9</sup> The plantar fasciotomy and tendon transfers are most relevant to this literature review as they address symptoms of CMT, like cavovarus foot and ulcerations.

Follow-up for a duration of over 4 years post-surgery showed a quick recovery for both feet, but the patient continued to have ulcerations beneath the fifth metatarsal head that was treated with fifth metatarsal head resection.<sup>9</sup> There was ultimately resolution of pain, no new ulcerations, and no reappearance of cavus. Active ankle dorsiflexion was regained and the patient did not require use of AFO braces as the patient was able to wear standard shoes.<sup>9</sup> Potential future need for AFO bracing was expected as the extensor digitorum longus and extensor hallucis longus muscles will weaken, in accordance with progressive neurological CMT.<sup>9</sup>

The late-stage reconstructive patient was a 31 year-old male with rigid equinocavovarus left foot and ankle deformity related to CMT, recurrent ulceration of fifth metatarsal head, and AFO induced skin breakdown over the talus head.<sup>9</sup> Weight-bearing radiographs were not available due to the severity of the rigid deformity.<sup>9</sup> The first stage of surgery, involving the rearfoot and ankle, employed a posterior medial release and triple arthrodesis.<sup>9</sup> Second stage reconstruction was performed 10

months later with midfoot wedge resection fusion, first metatarsophalangeal joint arthrodesis, metatarsophalangeal joint capsulotomy of toes 2 to 5, and hammertoe repair of toes 2 to 5.<sup>9</sup> The patient showed correction of the foot and ankle deformity, and experienced recurrent ulceration of the fifth metatarsal head, which was fixed with surgical fifth metatarsal head resection.<sup>9</sup> Follow-up 9 years after surgery showed no recurrence of anatomical deformities or ulceration, only requiring bilateral AFO bracing for a continued foot drop.<sup>9</sup>

### ***Osteotomy procedure***

Johnson et al. conducted surgical procedures on 3 patients with an average age of 24.6 years. Patients were selected based on their diagnosis of CMT, presence of a pes cavus deformity, and existence of a functioning tibialis posterior muscle.<sup>3</sup> Patient one had reducible calcaneus varus and received a Cole midfoot osteotomy, Steindler stripping, posterior tibial tendon transfer, and application of an external fixator.<sup>3</sup> Patient two had a non-reducible varus with a supple subtalar joint and received a Cole midfoot osteotomy, Steindler stripping, Dwyer calcaneal osteotomy, posterior tibial tendon transfer, and application of an external fixator.<sup>3</sup> Patient three had a non-reducible varus with a rigid subtalar joint and was operated on with a Cole midfoot osteotomy, Steindler stripping, posterior tibial tendon transfer, subtalar joint arthrodesis, and application of an external fixator.<sup>3</sup>

Radiographs showed that each patient had a reducible pes cavus with the apex at the midfoot before surgery.<sup>3</sup> Preoperative assessments for each patient were taken 3 months prior to surgery, and postoperative recordings were done a minimum of one year after surgery.<sup>3</sup> There was no observable reappearance of foot deformity in any of the patients following their postoperative assessments.<sup>3</sup> Pedobarographic results showed better foot pressure distributions following surgery, most significantly, a decreased peak pressure and ascension to a more normal distribution pressure pattern.<sup>3</sup> Additionally, each patient showed a decrease in pain score from presurgery to postsurgery.<sup>3</sup>

All of the information for patients one, two, and three are detailed in Table 2.<sup>3</sup> The Malleolar Valgus Index (MVI), described in Song et al., is a biomechanical examination taken with a flatbed scanner that is utilized to categorize the structure of a foot. MVI is based on the concept of valgus index and lateral malleolar index. The malleolar valgus index is adjusted to the height and width of the malleoli. MVI evaluates the static hindfoot-to-leg relationship by taking the forefoot, rearfoot, and transmalleolar bisections of the plantar foot. Dividing the distance between the center of the heel and the bisection of the foot by the patient's transmalleolar width, and multiplying the quotient by 100 to get a whole number will give you the value for MVI. MVI correlates with resting calcaneal stance position and long leg calcaneal axial radiographs

that are used to describe foot structure.

<sup>15</sup> The MVI was taken twice preoperatively and twice postoperatively, and the respective values were averaged to get those expressed in Table 2.<sup>3</sup> The McGill Pain Questionnaire (MPQ) measures subjective pain values, and is taken preoperatively and postoperatively.<sup>3</sup> The MPQ has 15 descriptions of pain and is rated on a severity scale of 0-3 by the patient, with a maximum of 45 points amassed by each patient.<sup>3</sup> The MPQ provides data in regards to the patients subjective evaluation of pain.<sup>3</sup>

Ward et al. conducted a study on twenty-five patients diagnosed with CMT who received surgery for cavovarus foot deformity. The average age of the study group was 15.5 years at time of surgery, ranging from 8.7 to 25.1 years.<sup>2</sup> The average duration of follow-up was 26.1 years, with a range from 9.9 to 33.5 years.<sup>2</sup> Most of the patients received a plantar fasciotomy, transfer of PL to PB tendon, and first metatarsal osteotomy. If the foot was correctable to a plantigrade position after the initial soft-tissue procedures, the osteotomy was not performed.<sup>2</sup> Eleven of twenty-five patients required the use of orthotics at time of follow-up, and none were observed to have ulcerations of the foot.<sup>2</sup> The Foot Function Index (FFI) consists of pain, disability, and activity limitation scores in a range of 0 to 100, with the higher score representing decreased function.<sup>2</sup> The average scores were respectively 35.0, 40.5, and 22.1.<sup>2</sup> The average gait velocity, taken with GAITRite system, was 103 cm/sec,

mean average cadence was 102 steps/min, and mean average stride length was 122cm.<sup>2</sup> In comparison with the values of normal individuals, the patients in this study had a slower gait velocity and slower cadence.<sup>2</sup> The study concluded that the use of soft-tissue procedures and first metatarsal osteotomy to reduce the cavovarus foot deformity produces lower rates of degenerative changes and reduces the need for future operations in comparison with patients who receive triple arthrodesis surgery.

The case study by Colon et al. involved a 41 year-old male patient with clinical findings of two plantar ulcerations on the right forefoot, a rigid cavus deformity of the right foot, an inverted and fixed rearfoot, and limited dorsiflexion of the right ankle joint. A neurological exam found that the patient lacked patella and deep tendon reflexes bilaterally, along with a deficit in vibratory sensation, and weakness of peroneal muscles.<sup>10</sup> The radiographic findings revealed the right foot had a cavus deformity with high calcaneal inclination angle, forefoot equinus, and a plantarflexed first metatarsal.<sup>10</sup> All of the aforementioned findings led to the diagnosis of CMT, and recommend surgical treatment to correct the deformities.

Table 2: Patient summary for Johnson et al.

	Patient One		Patient Two		Patient Three	
Procedures	Cole midfoot osteotomy, Steindler stripping, posterior tibial tendon transfer, and application of an external fixator		Cole midfoot osteotomy, Steindler stripping, Dwyer calcaneal osteotomy, posterior tibial tendon transfer, and application of an external fixator		Cole midfoot osteotomy, Steindler stripping, posterior tibial tendon transfer, subtalar joint arthrodesis, and application of an external fixator	
Surgical Stage	Presurgery	Postsurgery	Presurgery	Postsurgery	Presurgery	Postsurgery
MVI	41.5	4.5	61	11	31.5	10
MPQ	29	12	13	3	19	16

MVI (Malleolar Valgus Index); MPQ (McGill Pain Questionnaire)

The patient underwent an osteotomy in the hindfoot, slightly inferior to the subtalar joint and anterior lateral to the os calcis. The procedure resulted in a reduction in equinus and varus deformities.<sup>10</sup> Another osteotomy was performed in the midfoot at the midtarsal joint to correct the varus, adductus, and equinus deformities.<sup>10</sup> Finally, a dorsiflexory wedge osteotomy was employed to correct the plantarflexed first metatarsal that was diagnosed as severe by the surgical team before treatment.<sup>10</sup> All of the osteotomy procedures were maintained with internal and external fixation methods.<sup>10</sup> Following surgery the patient was placed on a physical therapy regimen and partial weight-bearing of the right foot was employed to aid recovery.<sup>10</sup> X-rays post-surgery showed satisfactory reduction for all of the involved deformities. Follow-up after surgery was recorded in variable intervals depending on the casting the physician prescribed for healing, with one follow-up being 4 weeks and another of 5 weeks.<sup>10</sup> The patient reported a capability to walk and stand for longer periods of time and had no recurrence

of ulcerations. In addition, the right foot assumed a normal shape and the patient overall was asymptomatic.<sup>10</sup>

#### *Arthrodesis procedure*

In Wetmore et al. the indications for performing triple arthrodesis were a paralytic foot and angular hind foot deformity. The study included 16 patients for a total of 30 feet that underwent triple arthrodesis. All of the sixteen patients suffered from CMT1.<sup>13</sup> The average age of these patients was 15 years old at their time of surgery and an average follow-up of 21 years post-surgery.<sup>13</sup> The results of the 30 triple arthrodesis procedures were two excellent, five good, nine fair, and fourteen poor after follow-up.<sup>13</sup> Table 3 describes the criteria used to clinically assess the surgical results, as well as their follow-up times.<sup>13</sup> The patients with poor results were older and had a longer average follow-up time, so the incidence of poor results increased with the length of time following triple arthrodesis.<sup>13</sup> All fourteen cases with poor results required orthotics for foot stabilization.<sup>13</sup> Cavovarus foot was the

Table 3: Surgical Assessment in Wetmore et al.

Surgical Results	Clinical Assessment Criteria	Length of Follow-Up
Poor	Foot showed marked undercorrection or overcorrection of deformity; gait was poor with impaired balance; foot and ankle were extremely unstable; orthosis required to approximate normal gait; moderate or severe pain on standing and walking; painful calluses; patient was markedly limited in performing vocational tasks and participating in recreational activities; radiographs demonstrated severe arthritic changes and pseudarthrosis of one or more joints.	14 total: 4 cases were between 10-20 years; 10 cases were more than 20 years.
Fair	Incomplete correction of deformity; moderate pain; calluses; vocational and recreational activities were impaired by diminished tolerance for walking; orthosis needed because of foot and ankle instability; radiographs showed moderate degenerative joint disease, and occasional pseudarthrosis of the talonavicular joint.	9 total: 2 cases were less than 10 years; 3 cases were between 10-20 years; 4 cases were more than 20 years
Good	Foot was well-aligned and had no callosities; the gait is heel-to-toe and wearing of shoes was normal; little pain and instability that caused minimal interference with vocational and recreational activities; radiographs showed minor degenerative changes and no evidence of pseudarthrosis.	5 total: 2 cases were less than 10 years; 1 case was 10-20 years; 2 cases were more than 20 years
Excellent	Normal gait; normal foot function; intact fusion; no foot deformity; no callosities; no pain in the foot; no limitation of activity; no ankle instability.	2 total: 1 case was less than 10 years; 1 case was between 10-20 years

residual deformity most observed after surgery, which was seen in nine feet and it also reappeared in seven feet that were initially corrected with surgery.<sup>13</sup> The authors recommend arthrodesis only for the most severe and rigid cases of cavovarus foot.

Santavirta et al. performed arthrodesis surgery on fifteen CMT patients. The most common problem amongst the patients included in this study was an advanced foot deformity that interfered with gait, shoe wearing, and brace fitting.<sup>14</sup> Five of the patients had such severe symptoms that they could not walk more than 400 meters.<sup>14</sup> There were a total of twenty-six fusion surgeries performed that exhibited a range of cavovarus symptoms. The categorization of these cavovarus symptoms were based on

criteria from a Levitt et al. article, with the results as follows: nine mild, twenty three moderate, three severe, and one extremely severe.<sup>14,17</sup> All fifteen patients had cavovarus foot and the main symptom precipitating arthrodesis was foot instability.<sup>14</sup>

Santavirta et al. performed twenty-one subtalar triple arthrodesis surgeries to correct the foot to the neutral position. Six surgeries of triple arthrodesis were accompanied with soft-tissue procedures including plantar fascia release and Achilles elongation.<sup>14</sup> A grice-type arthrodesis, pantalar arthrodesis, talocrural fusion, and interphalangeal fusion were each performed in separate cases.<sup>14</sup> Of the twenty-six arthrodesis surgeries performed there were four excellent grades, fifteen good, four fair, and



**Table 4: Surgical Grades in Santavirta et al.**

Surgical Grade	Physician Assessment
Poor	Patient is non-ambulatory because of marked deformity and/or pain.
Fair	Patient required braces
Good	No need for braces; slight deformity present
Excellent	Excellent function and appearance; patient is ambulatory, free of braces, free of pain.

three poor.<sup>14</sup> A criteria for these grades are provided in Table 4 and are based on classifications established by Levitt et al.<sup>17</sup> These results stayed consistent after a follow up of fifteen years.<sup>14</sup> Overall, Santavirta et al. reports that arthrodesis surgery can help CMT patients who suffer from severe symptoms like a cavovarus foot.

## DISCUSSION

Boffeli et al. compares two cases, one with early intervention and the second with late stage reconstruction. In the first case, the proactive approach for CMT patients was used. The early intervention included soft-tissue surgeries like plantar fasciotomy and tendon transfers. Early intervention tendon transfer is helpful in treating muscle weaknesses. The second case included a patient that received arthrodesis in the rearfoot, midfoot and in the digits along with a TAL, MPJ capsulotomy and plantar fascia release.<sup>9</sup> This study concluded that soft-tissue surgeries should be used early in the course of CMT disease to limit the need for major fusion and osteotomy surgeries.

The results of the Boffeli et al. case study suggest that early intervention

soft-tissue procedures can be used to achieve a plantigrade foot in a patient who suffers from the subtler symptomology of CMT, like flexible cavovarus foot. The study showed that the patient who received the traditional late stage reconstructive surgeries, which are used for more severe symptoms like rigid cavovarus foot and recurrent ulcerations, could achieve plantigrade foot and resolution of symptoms.<sup>9</sup> An early intervention saved the patient in this study from the more anatomically intrusive procedures that would be a consequence of waiting to do surgery later in the disease pathology. This paper states that because CMT is predictable in its progression of symptoms, this creates a suitable scenario for early intervention surgery that would be capable of correcting disease pathology before it has become worse.<sup>9</sup> Early intervention surgery however, become problematic in CMT patients suffering from the later stage disease with more severe symptoms such as neuropathic ulceration due to increased risk associated with performing surgeries on these patients.<sup>9</sup> Thus although a limited study, it shows there is merit in both soft-tissue procedures used early in disease pathology, as well as

reconstructive surgeries like osteotomies and arthrodesis used for more severe cases.

Johnson et al. uses osteotomy procedures to correct mild deformities of the foot like pes cavus in a case series consisting of three patients. Johnson et al. based their surgical choices on a symptomatic spectrum for CMT, in which milder symptoms led to a milder surgical approach, as in using a soft-tissue procedure for flexible pes cavus.<sup>9</sup> This study suggest that osteotomy is acceptable for patients with adequate forefoot and hindfoot range of motion that lack total correction of deformity after having soft-tissue procedure done. The midfoot osteotomy, used for all three cases in the study, is helpful to correct pes cavus in CMT patients.<sup>3</sup> The MVI taken both pre and post-surgery shows further proof for the efficacy of osteotomy. The decrease in MVI postsurgery implies that the hindfoot to leg relationship improved as a result of the reconstructive surgery done on the patients.<sup>3</sup> In addition, radiographical analysis showed better results in the talocalcaneal, talo-1<sup>st</sup> metatarsal, calcaneal inclination, and talar declination angles that lend support to corrections made anatomically in the three patients.<sup>3</sup> Pain reduction was also consistent for all patients in the study post-surgery.<sup>3</sup>

The midfoot osteotomy used in the Johnson et al. study, in combination with other procedures, produced promising results like plantigrade foot, correction of deformities, and

reduction of pain. The procedure uses a lateral curvilinear incision over the cuboid, and medial curvilinear incision over the navicular and first cuneiform. A subperiosteal technique lifts the soft tissue from the midfoot.<sup>3</sup> The apex of the osteotomy is situated laterally in the cuboid and medially in navicular-cuneiform joint.<sup>3</sup> A sagittal saw is used to perform the osteotomy from lateral to medial through the cuboid, cuneiforms, and navicular.<sup>3</sup> The bone wedge is then removed to correct the deformity.<sup>3</sup>

Johnson et al. cites a paradigm to guide treatment that includes correcting all segmental deformities while preserving joint mobility, balancing the remaining muscle forces, and leaving reasonable treatment options available in case of a recurrence of deformity and pain.<sup>3</sup> The authors have stated based on early results the dorsally based midfoot closing wedge provides excellent choice for a stable plantigrade foot for CMT patients.<sup>3</sup> They follow this approach by choosing to do an osteotomy for each of their patients in an effort to fix pes cavus while keeping the option to use arthrodesis should there be a need, although arthrodesis is not desirable according to the authors.<sup>3</sup> Further following the guideline, the authors state that osteotomies are used when soft-tissue surgeries have not reduced foot deformities of the patient.<sup>3</sup> The outcome of their limited study is said to address the deformity present and is shown in their preclinical and radiographic analyses.



In Colon et al., the approach to treating CMT in the lower extremities suggested that a procedure must be chosen to both best correct the deformity and leave the option for future surgery if there is a recurrence of symptoms. The patient had a rigid cavus deformity and ulcerations of the forefoot so they chose to perform an osteotomy rather than an arthrodesis. This approach is consistent with the Mosca guidelines, also used in Johnson et al., that require a surgeon to treat the patient conservatively to leave open the possibility of doing more reconstructive surgery in the future.<sup>10,17</sup> The conservative choice was to perform an osteotomy to correct the cavus foot deformity, and to leave arthrodesis as a future option should the surgical procedure not work, though the osteotomy fixed the deformities in the patient in that study.

10

The patient in the Colon et al. article had severe pes cavus deformity with forefoot equinus, forefoot adductus, forefoot varus, and rearfoot varus, in addition to ankle equinus and plantarflexed first metatarsal. The procedures performed were a calcaneal osteotomy and a Cole osteotomy. The result of this case study stated the deformities present were corrected. Although hard to infer with a case study, this study, along with Johnson et al. suggests that using the osteotomy procedure to treat mild-to-severe cases of the pes cavus is a beneficial approach to such deformities.<sup>10</sup>.

Wetmore et al. is considered a sentinel study on the merits of triple arthrodesis surgery for CMT patients and, subsequently, it is referenced by contemporary articles that focus on CMT disease.<sup>1,2,4</sup> Wetmore and his colleagues established the current principle that triple arthrodesis for the use of correcting foot deformities in CMT patients is not recommended unless there is clear indication that other available surgeries, like a plantar fasciotomy, tendon transfer, or osteotomy, are not capable of providing a surgical solution. So cases that show severe and rigid cavus foot that were not remedied by orthotics or the lower-risk surgeries like soft-tissue release and osteotomy, may benefit from triple arthrodesis surgery. This also infers that symptomology is directly correlated with surgical procedure choice and efficacy.

Wetmore et al. evaluated sixteen patients to show that the triple arthrodesis used to correct cavovarus deformity produced long-term results that were poor. The satisfactory outcome was only 24% for the patients in the study.<sup>13</sup> One of the reasons for the poor results is that triple arthrodesis removes shock-absorber function of the midfoot and hindfoot, which then increases the amount of stress on the ankle.<sup>13</sup> To compensate for this loss, the authors suggest using muscle-balancing procedures alongside triple arthrodesis, as well as prescribing the patient orthotics to lessen the burden created by removing the anatomical cushioning.<sup>13</sup> Hence, Wetmore et al. only recommend triple arthrodesis for

the most severe rigid deformities that will also require long-term use of orthotics.

Ward et al. showed that using soft-tissue procedures and osteotomy together produces decreased rates of degenerative change and a reduced need for reoperations in the future in comparison with patients who are treated with triple arthrodesis.<sup>2</sup> This helps support the finding of Colon et al. and Johnson et al. but with a bigger patient population of twenty-five patients. Ward et al. mentioned that the average age of their patients at time of surgery is the same as those patients in Wetmore et al. Ward et al. also pointed out that 77% of the cases in Wetmore et al. suffered degenerative changes of the ankle and midfoot, compared to only 31% in their study with moderate or severe osteoarthritis post-surgery.<sup>2</sup>

Santavirta et al. conducted their own study to further investigate arthrodesis as an approach to CMT and their results lend support to triple arthrodesis. The study showed 76% good or excellent results after using triple arthrodesis surgery for the fifteen patients they treated.<sup>14</sup> They were able to reduce cavovarus foot deformities that caused problems in gait, brace fitting, and shoe wearing.<sup>14</sup> The results suggest that triple arthrodesis can be used to conserve function in patients who suffer from foot deformities and weaknesses caused by CMT.<sup>14</sup> However, there is caution to be made in the Santavirta et al. results. Three cases showed failed fusion in triple arthrodesis and

subsequent arthrodesis surgery had to be done within 13 months to four years.<sup>14</sup> Two other cases of triple arthrodesis caused malposition fusion that had to be fixed with osteotomy and new fusion procedure.

## CONCLUSION

The general approach to a neurological cavus foot is to perform a procedure that will preserve joint mobility. As the symptoms get more rigid and severe then the treatment follows accordingly, like osteotomy being used for deformities that were not reduced by soft-tissue procedures, and then followed by arthrodesis for the more rigid deformities that were not corrected by osteotomies or soft-tissue procedures.<sup>3</sup>

Overall, the results of the reviewed papers suggest that osteotomy is the first procedure to be used following soft-tissue surgeries that do not produce long-term correction of cavovarus foot. Osteotomy is a valuable procedure to use for the more severe symptoms of cavovarus foot, like rigid and inflexible foot, because it can correct the associated deformities. Incorporating osteotomy surgery earlier on in the process can help prevent symptoms like calluses, ulcers, and gait that usually are consequences of having the more severe type of cavovarus foot.

Arthrodesis is reserved for use when soft tissue and osteotomy surgeries do not produce adequate results for the patient. Arthrodesis is reserved for

patients with severe atrophy or for recalcitrant cases. It removes the stress-absorber function of the midfoot and hindfoot and there is an increase in stress on the foot of the patient.<sup>13</sup> This can cause problems for CMT patients because their progressive loss of proprioception and balance combined with decreased shock-absorbing function of the foot renders the patient more susceptible to osteoarthritic changes of the foot.<sup>13</sup> Arthrodesis has varying levels of success and support amongst surgeons. Santavirta et al. reported that of the twenty-six triple arthrodesis surgeries performed there were twenty-three grades of either excellent, good, or fair. In Wetmore et al. the authors reported that of thirty triple arthrodesis surgeries performed there were fourteen with poor results, and recommended that triple arthrodesis surgery only be used as the last plan for treating a CMT patient with severe fixed foot deformities like cavovarus foot. This lack of consistency in results for the benefits of arthrodesis in CMT patients is emblematic of its use with CMT patients, it is reserved as the last surgical option for patients with severe symptoms of CMT.

People afflicted with CMT disease present with a range of symptoms that progress in severity from the supple, flexible foot type to the more rigid foot type. Symptoms are used as an indicator for determining a surgical treatment approach. There are surgical procedures that correlate with these symptoms in a consistent manner and have proven successful in reducing

foot deformities. Based on the successful outcomes reported in the six articles analyzed in this review, various surgical approaches to treatment of a cavovarus foot related to CMT are available.

## AUTHORS' CONTRIBUTIONS

The authors contributed equally in all aspects of this paper.

## STATEMENT OF COMPETING INTERESTS

The authors declare that they have no competing interests.

## REFERENCES

1. Johnson NE, Heatwole CR, Dilek N, Sowden J, Kirk CA, Shereff D, Shy ME, Herrmann DN, Inherited Neuropathies Consortium. Quality-of-life in Charcot-Marie-Tooth disease: the patient's perspective. *Neuromuscular Disorders: NMD*. 2014; 24(11):1018-23. doi: 10.1016/j.nmd.2014.06.433.
2. Ward C, Dolan L, Bennett L, Morcuende J, Cooper R. Long-term results of reconstruction for treatment of a flexible cavovarus foot in Charcot-Marie-Tooth disease. *The Journal of Bone and Joint Surgery*. 2008; 90(12): 2631-42. doi: 10.2106/JBJS.G.01356.

3. Johnson B, Child B, Hix J, Mendicino R, Catanzariti A. Cavus foot reconstruction in 3 patients with Charcot-Marie-Tooth disease. *The Journal of Foot and Ankle Surgery*. 2009. 48(2): 116-124. doi: 10.1053/j.jfas.2008.11.013.
4. Guyton G. Current concepts review: orthopaedic aspects of Charcot-Marie-Tooth disease. *Foot & Ankle International*. 2006; 27(11):1003-10.
5. Dreher T, Wolf SI, Heitzmann D, Fremd C, Klotz MC, Wenz W. Tibialis posterior tendon transfer corrects the foot drop component of cavovarus foot deformity in Charcot-Marie-Tooth disease. *The Journal of Bone and Joint Surgery*. 2014. 96(6): 456-462. doi: 10.2106/JBJS.L.01749.
6. Chandhok G, Soh MS. Presynaptic deficits at neuromuscular junctions: a specific cause and potential target of axonal neuropathy in type 2 Charcot-Marie-Tooth disease. *The Journal of Neuroscience: The Official Journal of the Society for Neuroscience*. 2016; 36(31): 8067-9. doi: 10.1523/JNEUROSCI.1515-16.2016.
7. Kolodziej L, Dobiecki K, Sadlik B. Surgical treatment of advanced, stiff neurologic cavovarus foot in adults. *Ortopedia Traumatologia Rehabilitacja*. 2013; 4(6); Vol. 15: 325-333.
8. Barton T, Winson I. Joint sparing correction of cavovarus feet in Charcot-Marie-Tooth disease. What are the limits? *Foot Ankle Clinic*. 2013 Dec;18(4):673-88. doi: 10.1016/j.fcl.2013.08.008.
9. Boffeli T, Tabatt J. Minimally invasive early operative treatment of progressive foot and ankle deformity associated with Charcot-Marie-Tooth disease. *The Journal of Foot & Ankle Surgery*. 2015. 54: 701-708. doi: 10.1053/j.jfas.2014.03.019.
10. Colon M, Whitton K, Schwartz N. Treatment of pes cavus in a patient with Charcot-Marie-Tooth disease. *The Journal of Foot Surgery*. 1980. Volume 19, Number 1: 41-44.
11. Tennant JN, Carmont M, Phisitkul P. Calcaneus osteotomy. *Current Reviews In Musculoskeletal Medicine*. 2014; 7(4):271-6. doi: 10.1007/s12178-014-9237-8.
12. Kiewiet NJ, Benirschke SK, Brage ME. Triple arthrodesis: tips and tricks to navigate trouble. *Foot and Ankle Clinics*. 2014; 19(3):483-97. doi: 10.1016/j.fcl.2014.06.008.
13. Wetmore R, Drennan J. Long-term results of triple arthrodesis in Charcot-Marie-Tooth disease. *The Journal of Bone and Joint Surgery*. 1989. Vol. 71-A, No. 3.
14. Santavirta S, Turunen V, Ylinen P, Konttinen YT, Tallroth K. Foot and ankle fusions in Charcot-Marie-Tooth disease. *Archives of*

- Orthopaedic and Trauma Surgery.*  
1993; 112: 175-179.
15. Song J, Hillstrom HJ, Secord D, and Levitt J. Foot type biomechanics. comparison of planus and rectus foot types. *Journal of the American Podiatric Medical Association.* January 1996, Vol. 86, No. 1, pp. 16-23.
  16. Mosca VS. The cavus foot. *Journal of Pediatric Orthopedics.* 2001; 21(4): 423-4.
  17. Levitt RL, Canale ST, Cooke AJ Jr, Gartland JJ. The role of foot surgery in progressive neuromuscular disorders in children. *The Journal of Bone and Joint Surgery.* 1973 Oct; 55(7):1396-410.

# A Comparison of Traditional and Novel Conservative Treatments for Plantar Fasciitis: A Literature Review

Grace Tsai, BSN, Gavin Tsuchida, BS, Darren Doi, BS & Lucian Feraru, BS

## Abstract

### Introduction

The purpose of this study is to evaluate the efficacy of low-level laser therapy (LLLT) with respect to current conservative treatments recommended for plantar fasciitis. LLLT is a relatively novel treatment for plantar fasciitis, and its clinical outcome has not been compared with other conservative treatments. This review offers a preliminary analysis based on available research.

**Study design:** Systematic Qualitative Review of the Literature

### Methods

English language literature searches were performed using PubMed. The search was done using the terms “plantar fasciitis” AND “laser therapy,” “plantar fasciitis” AND “treatment,” “plantar fasciitis” AND “conservative treatment.” Patients clinically diagnosed with plantar fasciitis and subjected to only conservative treatment were included. Exclusion criteria included articles published prior to 2006 and articles involving invasive treatments such as surgery or injection. The search ultimately yielded twelve articles whose FFI and VAS scores were used for percent change calculations and comparison.

### Results

LLLT shows promise as having more treatment efficacy than stretching, taping and manual therapy with regards to long-term management for plantar fasciitis. NSAIDs and foot orthoses, both custom and prefabricated, were shown to be more effective for plantar fasciitis than LLLT. ESWT and LLLT were shown to be equally efficacious in their treatment results for chronic plantar fasciitis.

### Conclusion

LLLT could be an effective treatment modality in treating acute and chronic plantar fasciitis. Other modalities also led to a significant decrease in heel pain compared to their placebo groups. However, when comparing the percent changes of the VAS or FFI scales of each modality to LLLT, there is evidence suggesting that LLLT would only be more effective than stretching and ESWT. LLLT may not have certain advantages over other modalities such as low-dye taping, which may yield immediate improvement. Therefore, LLLT could be an effective alternative when currently accepted conservative treatment modalities are contraindicated.

**Key Words:** Plantar fasciitis, Low Level Laser Therapy, Conservative Treatment

*Levels of Evidence:* 4

## INTRODUCTION

Plantar fasciitis is the most common cause of heel pain,<sup>1,2</sup> and is thought to be an inflammatory condition of the plantar fascia<sup>3</sup> with a mechanical origin.<sup>4</sup> The plantar fascia is a band of fibrous tissue originating on the medial calcaneal tubercle and inserting into the medial & lateral intermuscular septa, transverse metatarsal ligament sheath, plantar plate, and proximal phalanges.<sup>4,5</sup> Upon weightbearing, the plantar fascia endures high levels of repetitive stress while supporting the medial arch of the foot. As a result, overuse of the plantar fascia results in microtears at its origin, causing an inflammatory response. Histologically, this can be defined as fibrofatty degeneration of the plantar fascia origin with microtears and collagen necrosis.<sup>6,7</sup> However, some studies suggest that this might be a non-inflammatory degenerative process rather than an inflammatory one and thus “fasciosis” might be a more accurate description of the condition.<sup>7,8</sup> A study by Lemont et al. found that rather than inflammatory changes, patients exhibited degenerative changes to the fascia, which supports the theory that inflammation might not be a component.<sup>9</sup> Clinically, commonly reported signs and symptoms include: pain with first step in the morning, pain along medial arch, pain upon palpation of medial tubercle of calcaneus, pain after prolonged resting, and pain that may be exacerbated or relieved with

continued activity. Pain is often reported as “sharp” or “stabbing.”<sup>5</sup>

A multitude of conservative and non-conservative treatments exists for plantar fasciitis. One author states that ninety percent of plantar fasciitis cases are resolved with conservative treatment<sup>5</sup> while the remaining ten percent of cases are classified as recalcitrant plantar fasciitis that have continued symptoms after ten months of treatment.<sup>7</sup> Common conservative treatments include non-steroidal anti-inflammatory drugs (NSAIDs), stretching exercises, custom foot orthoses (CFOs), manual therapy, and taping. Those that fail conservative treatments are considered for more aggressive therapy such as corticosteroid injection, extracorporeal shockwave therapy (ESWT), or surgery such as plantar fasciotomy.<sup>5</sup> Low level laser therapy (LLLT) is a novel, painless, non-invasive treatment modality, which could serve as another conservative modality for treating acute and recalcitrant plantar fasciitis.<sup>5,7</sup> Due to its novelty, there is no proven mechanism of action for the observed clinical effects but different theories have been proposed. It has been theorized that LLLT would decrease inflammation, enhance pain reduction, and increase tissue healing by inducing signal cascades. Macias et al. suggested that LLLT uses a precise wavelength of light to stimulate a photoreceptor protein, which initiates different signal transduction cascades dependent on the specific wavelength and laser intensity. The physiological effects of such cascades include:

inhibition of cyclooxygenase-2, histamine release, conduction along unmyelinated C fibers as well as enhancement of peripheral endogenous opioid, and collagen synthesis in tendons and ligaments, reduction in fibrosis, and enhanced angiogenesis<sup>5</sup>. Jastifer et al. proposed that LLLT enhances leukocyte infiltration, macrophage activity, collagen deposition, cellular proliferation, and neovascularization thus promoting tissue healing and remodeling.<sup>7</sup>

The purpose of this study is to review current literature on conservative treatment modalities for the treatment of plantar fasciitis and to demonstrate the efficacy of low level laser therapy as a treatment modality in comparison to the aforementioned conservative treatment options; whether to be used solely or in conjunction with other conservative treatment modalities.

## METHODS

Three English language literature searches were performed using the PubMed database. The Boolean operator “or” was used in two of the three searches. Articles were included or excluded based on the criteria outlined in Table 1 on review of the returned article’s abstracts. The first search used the terms “Plantar Fasciitis” “Laser” and yielded eleven articles. Once inclusion and exclusion criteria were applied, three articles were chosen for further review. The second search for the term "Plantar Fasciitis" "Splinting" OR "Taping" OR "NSAID" OR "Extracorporeal

Shock Wave Therapy" OR "Stretching" "Plantar Fasciitis" yielded 226 articles. Of these 226 articles, ten articles met the inclusion and exclusion criteria. Of the 226 articles, an additional two articles were systematic reviews and yielded two articles from their listed references. The third search was performed using the term “Foot” “Orthosis” OR “Orthotic” “Plantar Fasciitis” yielding 97 articles. Once inclusion and exclusion criteria were applied, two articles were chosen for further review. Ultimately, seventeen articles in total were chosen for extensive review. The search methods are summarized in Figure 1.

<p><b>Inclusion Criteria</b></p> <ul style="list-style-type: none"> <li>-Patients diagnosed with plantar fasciitis</li> <li>-Noninvasive treatments</li> <li>-Use of the Functional Foot Index (FFI) and/or Visual Analog Scale (VAS)</li> </ul> <p><b>Exclusion Criteria</b></p> <ul style="list-style-type: none"> <li>-Articles published before 2006</li> <li>-Articles written in a non English language</li> <li>-Invasive treatments (injections or surgery)</li> </ul>
--

Table 1: Inclusion and Exclusion Criteria

After thorough review of the chosen articles, the Visual Analog Scale (VAS) and Foot Function Index Scale (FFI) data were compiled from each of the studies and calculations were performed to show percent change from baseline measurements to measurements taken at follow-ups (Table 2 and Table 3). In the studies, the VAS composite score included self-rated measures of heel pain while taking the first steps in the morning, heel pain while doing daily activities, and heel pain while applying local



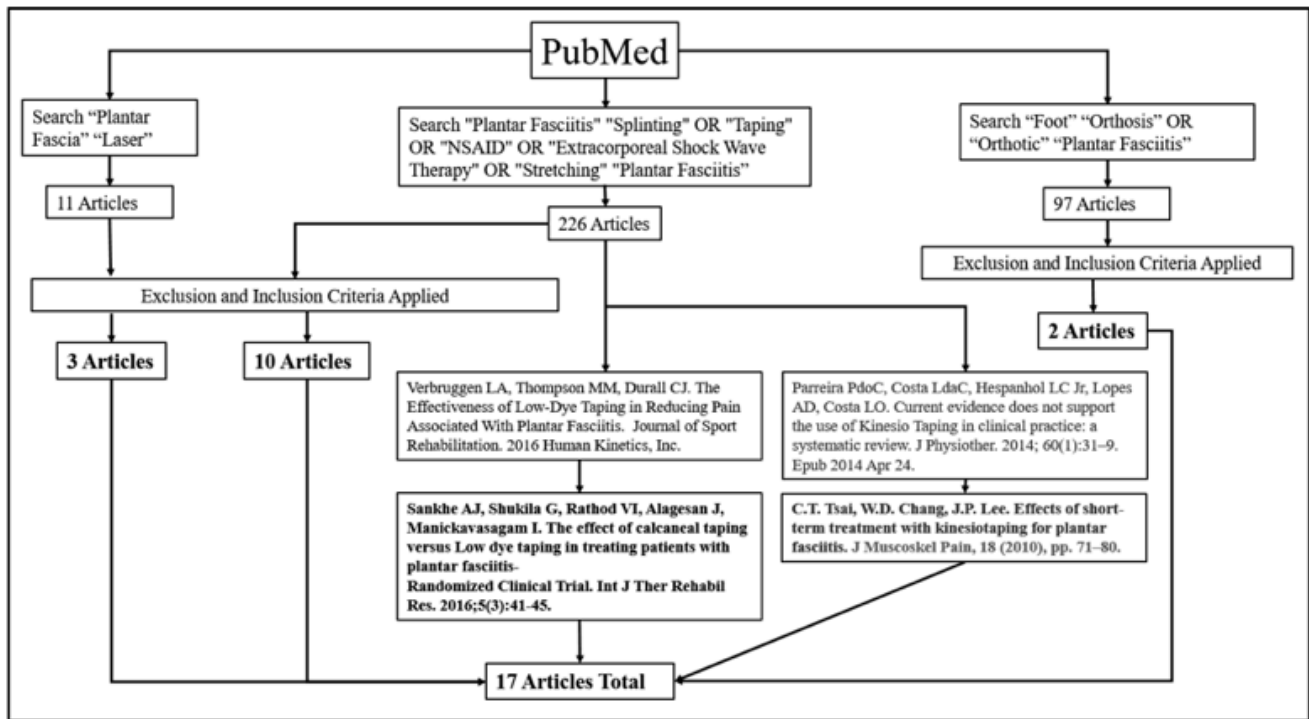


Figure 1: Summary of PubMed Searches

pressure. A maximum score of ten in each category corresponded to severe pain. The FFI is a self-administered questionnaire that measures the amount of pain the foot has on the quality of life.<sup>5</sup> The FFI is subjective in the evaluation of the ailment in question as it impacts the person's level of pain, disability, and activity. These calculations were performed if the study itself did not provide the percent change data.

## RESULTS

### *NSAIDS (Nonsteroidal Anti-Inflammatory Drugs)*

The prospective, randomized, placebo controlled double blind study done by Donley et al. involved 29 patients that were treated with heel-cord stretching, viscoelastic heel cups, and night splinting, and then split into two groups. One group received Celecoxib and the other a placebo. They were

followed for six months and measures were taken at baseline, one month, two months, and six months. The NSAID group showed a 34.09%, 49.87%, and 80.88% decrease on the FFI – Pain Scale and a 30.23%, 44.28%, and 81.05% decrease on the FFI – Disability Scale at four weeks, eight weeks, and six months, respectively. The placebo group showed a -574.22%, -5473.77%, and 72.28% decrease on the FFI – Pain Scale and 16.60%, 45.66%, and 71.89% decrease on the FFI – Disability Scale at four weeks, eight weeks, and six months respectively. In the placebo group, two patients' symptoms worsened, two patients' symptoms were unchanged, and one patient was asymptomatic at the four-week follow-up. At the eight-week follow-up, two patients had worsening symptoms and one patient was asymptomatic. In comparing the placebo and NSAID groups, Donley et al. found that the sample size of the

study was not large enough to show statistical significance. However, the NSAID group did show a decrease in pain and disability in patients with plantar fasciitis that was greater than the placebo group providing some positive evidence for use of NSAIDs as a treatment option for plantar fasciitis.<sup>10</sup>

### ***Stretching***

Patients with plantar fasciitis participated in a randomized control trial by Hyland et al., who studied the use of calcaneal taping, sham taping and plantar fascia stretching for the short-term management of plantar heel pain. 41 subjects satisfied their inclusion criteria and were assigned to one of four groups – stretching of the plantar fascia, calcaneal taping, control (no treatment), and sham taping. Patients in the stretching group showed a significant improvement on the visual analogue scale post-intervention (26.98% improvement) compared to the control group (1.59% improvement).<sup>6</sup>

Radford et al. appraised the effectiveness of calf muscle stretching for the short-term treatment of plantar heel pain. Ninety-two participants were split into two groups, one group was prescribed calf muscles stretching with sham ultrasound, and the other only received sham ultrasound. After two weeks, a 27.93% improvement in first-step pain for the stretching group and a 17.55% improvement in the sham ultrasound group was recorded.

<sup>11</sup>

DiGiovanni et al. studied the improvement of plantar fascia-specific exercises in patients with chronic plantar fasciitis. They recruited eighty-two patients for a duration of two years. Their study showed an improvement of 37.1% in the plantar fascia stretching group and a 16.9% improvement in the Tendo Achilles stretching group, at eight weeks. Their follow-up at two years showed a 68.4% improvement in the plantar fascia stretching group, as well as a 59.2% improvement in the Tendo Achilles stretching group.<sup>12</sup>

In the randomized, single-blinded trial by Sharma et al., thirteen subjects were used to measure the use of a static progressive stretch brace as a treatment for plantar fasciitis. Based on results estimated from charts, their study shows a 33.96% improvement on VAS at twelve weeks.<sup>13</sup>

Kamonseki et al. conducted a single-blinded, randomized, controlled trial studying the effect of stretching with and without muscle strengthening exercises for the foot and hip in patients with plantar fasciitis. They studied eighty-three patients over an eight-week period. The patients were allocated to one of three treatment groups. The improvement in plantar heel pain on the VAS scale at eight weeks for the Foot Exercise Group was 46%. For the Foot and Hip Exercise group, the improvement was 39%, and for the Stretching Alone Group, the improvement on VAS was 45%.<sup>14</sup>

## ***Taping***

As previously mentioned, Hyland et al. conducted a randomized control trial, which studied the use of calcaneal taping, sham taping, and plantar fascia stretching for short-term management of plantar heel pain. Patients in the calcaneal taping group showed a 61.4% decrease in pain compared to the decrease in pain of 6.3% in the sham taping group. Hyland et al. concludes that calcaneal taping is an effective tool in managing plantar heel pain.<sup>6</sup>

A randomized, participant-blinded trial was performed over a period of one week by Radford et al. with 92 participants. Low-dye taping was compared with sham treatment consisting of an ultrasound modality that was powered off. Participants in the low-dye taping group showed a significant improvement of 42.0% in pain upon first step compared to sham ultrasound group, which had a 15.8% improvement in pain upon first step. Radford et al. concludes that low-dye taping provided a small improvement in first-step pain compared with sham intervention after a one-week period.<sup>15</sup> Another study performed by Sankhe et al. consisted of a randomized controlled trial that occurred for one week with 52 participants. This study compared low-dye taping with ultrasound and physical therapy to calcaneal taping with ultrasound and physical therapy. FFI values were obtained prior to and one week after receiving treatment. The participant group receiving calcaneal taping treatment had a 69.0% change in FFI

compared to the low-dye taping group, which had a 75.9% change in FFI. Sankhe et al. concluded that low-dye taping is significantly more effective than calcaneal taping showing an increase in FFI in patients with plantar fasciitis.<sup>16</sup>

Low-Dye taping as an adjunct to conservative treatment versus conservative treatment alone for plantar fasciitis over six weeks was evaluated by Park et al. Conservative treatment consisted of transcutaneous electrical nerve stimulation (TENS) and infra-red therapy. Using the VAS, the low-dye taping group produced an improvement of 59.14% after six weeks compared to an improvement of 20.65% in the conservative treatment group. An improvement following the “long-term” (twelve hours) use of low-dye taping is attributed to correction of the subtalar joint axis, reducing pronation. Pronation is believed to cause numerous foot deformities that contribute to the development of plantar fasciitis. Park et al. concluded that the low-dye taping in addition to conservative treatment decreased pain more significantly than conservative treatment alone.<sup>17</sup>

In the study performed by Tsai et al., 52 patients with plantar fasciitis were used to compare a traditional physical therapy program versus kinesiotaping paired with traditional physical therapy over a period of one week. The physical therapy program consisted of ultrasound thermotherapy and low frequency electrotherapy. Results were measured using the

Functional Foot Index. The group receiving traditional physical therapy had a six percent increase in FFI, while the group receiving kinesiology taping in addition to physical therapy had a 43.98% increase in FFI after one week.<sup>18</sup>

### ***Manual Therapy***

Ajimsha et al. conducted a double-blinded randomized controlled trial on the effectiveness of myofascial release in the management of plantar heel pain. Their study included 66 patients with a clinical diagnosis of plantar heel pain and were assigned into a myofascial release group or a control group. The patients were given twelve sessions of treatment over four weeks. Their results showed a significant (72.4%) improvement in FFI at four weeks compared to a 7.38% improvement in their control group.<sup>19</sup>

### ***Custom Foot Orthoses versus Prefabricated Foot Orthoses***

Baldassin et al. conducted a double-blinded randomized controlled trial to evaluate the effectiveness of prefabricated and customized foot orthoses in plantar fasciitis. One hundred forty-two adults with plantar fasciitis participated in the study and seventeen subjects were lost during follow-up. Both prefabricated and customized foot orthoses were made from ethylene vinyl acetate (EVA) foam and used for eight weeks. Outcomes were measured using a modified subscale of the Foot Function Index (mFFI). Participants were followed up in the fourth and

eight weeks. Improvement at eight weeks of mFFI was 42.12% for prefabricated orthoses and 52.98% for customized foot orthoses. Baldassin et al. concluded customized foot orthoses and prefabricated orthoses with low cost had similar effectiveness.<sup>20</sup>

### ***Extracorporeal Shock Wave Therapy (ESWT)***

Gollwitzer et al. performed a double-blind, randomized, placebo-controlled trial for FDA approval. This study consisted of 250 participants who have failed nonsurgical treatments for at least six months. They received a maximum of three sessions weekly upon which they received 2000 high-energy impulses of extracorporeal shock waves. Treatments were considered successful if there was a reduction of 60% in at least two out of the three Visual Analog Scale (VAS) scores recorded compared to baseline. At the initial follow up, the ESWT group (n=124) showed a decrease in VAS score by 69.2%, while the placebo group (n=126) showed a decrease in VAS score by 34.5%. Participants with positive outcomes following the initial ESWT sessions were revisited at twelve weeks and then allowed to continue with the trial for an additional twelve months. A second follow-up available to only those that were eligible after the initial follow-up (n=137), including some that were in the placebo group, demonstrated the stability of the treatment's success. The authors mentioned that there was an increased change on the VAS score with the one

hundred and twenty-four patients that proceeded with the trial. However, a numerical value regarding the change on their VAS score was not provided.<sup>1</sup>

A study performed by Gerdesmeyer et al. consisted of 254 patients in a double-blind, randomized, placebo-controlled trial, with the patients assigned to either the radial extracorporeal shock wave therapy or placebo treatment. Patients received three treatment sessions and had a follow-up at twelve weeks after last treatment. A second follow-up was done for those whose response showed clinical significance at the first follow-up. The treatment consisted of two thousand impulses of radial shock waves with an energy of  $0.16\text{mJ/mm}^2$  and a rate of eight impulses. At the twelve-week follow-up, the treatment group reported a decrease in composite score of heel pain in the VAS by 72.1%, while the placebo group reported a decrease of 44.7%. This was considered a significant decrease from baseline because the authors defined a greater than 60% decrease in two out of the three heel pain measurements as the therapeutic success.<sup>2</sup>

The authors of both studies stated that the ESWT would be an effective treatment for chronic plantar fasciitis.<sup>1,2</sup>

### ***Low Level Laser Therapy (LLLT)***

Macias et al. performed a double-blind, placebo-controlled, randomized multi-center study consisting of 69

subjects. The type of laser used was a divergent 635nm red light laser with a 17mW output. The subjects had a two-week wash-out period, which is defined as a period where the participants were to refrain from using any over-the-counter or prescription pain relief such as NSAIDs, topical analgesics, and corticosteroid medications. After a three-week period of six sessions, the results showed a mean reduction of 44.2% in VAS rating of heel pain in the treatment group as compared to the mean reduction of 7.5% in the placebo group. There was no statistical difference when evaluating the FFI rating reported by both groups but LLLT shows promise as a treatment for plantar fasciitis.<sup>5</sup>

In a study done by Jastifer et al., 30 of their 34 participants were recruited from a previous multicenter, prospective, double-blind, randomized control trial. A 635nm red light laser with a 17mW output was also used in this study. Sixteen out of thirty had already undergone treatment and were in the midst of reaching their twelve-month follow-up mark; the remaining fourteen began treatment since they were originally part of the original study's control group. This particular study did not have a control group of its own. These participants also received six treatments over three weeks, and were asked to halt other conservative treatments. Although VAS and FFI were a means of appraising effectiveness, the authors did not report significant outcomes in percentages. The authors reported a statistically significant decrease in



VAS score at each evaluation point from baseline. At the end of the twelve months, the VAS score had decreased by 61.0 out of 100. The changes in FFI subscales (Pain and Disability) were also reported to be statistically significant showing a 38 point and 29.2 point decrease by twelve months. The total FFI score showed a 73.9 point decrease by twelve months. Jastifer et al. reported a significant outcome from his previous study, which consisted of a control group and a treatment group, with the control group VAS score of 5.4 and the treatment group VAS score of 29.6 at a two-week follow-up. Jastifer et al. explain that although his current study did not have a placebo group, the results are consistent with the findings from his previous study. The authors concluded that LLLT could be an alternative treatment for chronic plantar fasciitis.<sup>7</sup>

A randomized, double-blind, placebo-controlled trial study consisting of thirty participants using a 904nm gallium-arsenide (GaAs) infrared laser was studied by Kiritsi et al. Ultrasonography and the VAS were employed to measure the results qualitatively and quantitatively; evaluating the outcomes in this manner accounted for objective and subjective aspects as well. This study did not discuss whether the participants had to refrain from other conservative treatments. The participants received six weeks of treatments three times a week for a total of eighteen treatments. The authors reported that six weeks after the LLLT, pain was decreased by 59%

in the treatment group while it decreased by 26% in the placebo group. The authors postulate that LLLT may contribute to healing of the fascia and pain reduction by triggering regenerative fibrous tissue and accelerating the repair process. This is demonstrated in the study with ultrasonographic evidence of a significant difference in plantar fascial thickness between the treatment and placebo groups.<sup>4</sup>

## DISCUSSION

### *NSAIDS versus LLLT*

A comparison between the studies done by Donley et al., Jastifer et al., and Macias et al. indicate that a treatment of NSAIDs combined with night splinting, heel-cord stretching, and viscoelastic heel cups showed a greater percent change in the FFI – Pain and FFI – Disability scales especially at eight weeks and six months (Table 3). However, the inclusion criteria of the Jastifer et al. and Macias et al. studies indicate that the patients in the study were unresponsive to conservative treatments (including NSAIDs). In Jastifer et al.'s study, the patients were allowed to use acetaminophen as an emergency drug at their discretion. The NSAID group in Donley et al.'s study included usage of night splinting, viscoelastic heel cups, and heel-cord stretching, which might have been a confounding variable. This is especially relevant considering that the sample size was too small for the difference between the placebo and NSAID group to be considered statistically significant.

Modality	Author of Study	VAS Group	% Change	% Change	% Change	% Change	% Change	% Change	% Change	% Change
			1 week	2 week	6 week	8 week	12 week	6 months	1 year	2 year
LLLT	Jastifer et al	VAS	*	39.68%	*	*	*	*	81.86%	89.82%
	Macias et al	VAS	*	*	*	42.92%	*	*	*	*
		VAS - Placebo	*	*	*	7.84%	*	*	*	*
	Kiritsi et al	VAS - Night rest	*	*	56.25%	*	*	*	*	*
		VAS - Placebo - Night Rest	*	*	22.45%	*	*	*	*	*
		VAS - Daily Activities	*	*	58.21%	*	*	*	*	*
VAS - Placebo - Daily Activities		*	*	25.37%	*	*	*	*	*	
Stretching	Hyland et al	VAS - Gastroc/Soleus Plantar Fascia by Therapist	26.98%	*	*	*	*	*	*	*
		VAS - Control	1.59%	*	*	*	*	*	*	*
	Sharma et al	VAS - Plantar Fascia Stretch + Massage + Tendoachilles Stretch	*	*	*	*	33.96%	*	*	*
	DiGiovanni et al	VAS - Plantar Fascia stretching	*	*	*	37.1%	*	*	*	68.4%
		VAS - Tendo Achilles stretch	*	*	*	16.9%	*	*	*	59.2%
	Radford et al	VAS - Tendo Achilles on Step	*	27.93%	*	*	*	*	*	*
		VAS - Control	*	17.55%	*	*	*	*	*	*
	Kamonseki et al	VAS - Foot Exercise Group	*	*	*	46%	*	*	*	*
		VAS - Foot and Hip Exercise Group	*	*	*	39%	*	*	*	*
			VAS - Stretching Alone Group	*	*	*	45%	*	*	*
Taping	Hyland et al	VAS - Stretching Group	26.98%	*	*	*	*	*	*	*
		VAS - Calcaneal Taping	61.43%	*	*	*	*	*	*	*
		VAS - Control Group	1.59%	*	*	*	*	*	*	*
		VAS - Sham-taping Group	6.25%	*	*	*	*	*	*	*
	Park et al	VAS - Low Dye Taping Group	*	*	59.14%	*	*	*	*	*
		VAS - Conservative Treatment Group	*	*	20.65%	*	*	*	*	*
	Radford et al	VAS - Low Dye Taping + Sham Ultrasound	42.02%	*	*	*	*	*	*	*
		VAS - Sham Ultrasound	25.00%	*	*	*	*	*	*	*
ESWT	Gollwitzer et al	VAS - ESWT	*	*	*	*	69.20%	*	*	*
		VAS - Placebo	*	*	*	*	34.50%	*	*	*
	Gerdesmeyer et al	VAS - ESWT	*	*	*	*	60.98%	*	63.41%	*
		VAS - Placebo	*	*	*	*	42.24%	*	43.97%	*

\*VAS data was not recorded in the study at this time point

**Table 2:** Percent changes in VAS score for different treatment modalities based on data collected from individual studies

Acknowledgment of these facts suggests that LLLT should be viewed as a treatment modality for plantar fasciitis resistant to conservative methods while NSAIDs coupled with other conservative measures is best suited for patients experiencing acute plantar fasciitis. Finally, increasing trends in decreasing pain and disability were seen in LLLT in studies executed by Jastifer et al. and Macias et al. indicating that LLLT could be considered a viable treatment option if NSAIDs are contraindicated. [5,7,10](#)

### **Stretching versus LLLT**

Stretching has always been considered a classical treatment for plantar

fasciitis due to the ease and usefulness of the technique in alleviating pain. This is achieved through a controlled stretch of the plantar fascia and recreating the windlass mechanism.<sup>12</sup> Stretching also increases ankle range of motion which reduces the strain that the calf muscle puts on the plantar fascia.<sup>11</sup> Studies that looked at stretching as a treatment modality for plantar fasciitis showed a significant improvement on VAS after a short follow-up.<sup>6</sup> In a comparison with respect to follow-up time, the improvement on VAS at two weeks in a LLLT study<sup>7</sup> showed greater efficacy over stretching exercises.<sup>11</sup> Compared to the stretching articles we evaluated, LLLT studies had a

Modality	Author of Study	FFI Group	% Change 1 week	% Change 2 weeks	% Change 4 weeks	% Change 8 weeks	% Change 12 weeks	% Change 6 months	% Change 1 year
LLT	Jastifer et al	FFI - Pain	*	23.29%	*	*	*	62.11%	70.24%
		FFI - Disability	*	23.33%	*	*	*	67.99%	72.46%
		Total FFI	*	23.63%	*	*	*	63.18%	69.59%
	Macias et al	FFI - Pain	*	*	*	27.01%	*	*	*
		FFI - Pain - Placebo	*	*	*	22.18%	*	*	*
		FFI - Disability	*	*	*	26.74%	*	*	*
		FFI - Disability - Placebo	*	*	*	23.34%	*	*	*
		Total FFI	*	*	*	0.98%	*	*	*
		Total FFI - Placebo	*	*	*	22.29%	*	*	*
NSAIDS	Donley et al	FFI - Pain - NSAID group	*	*	34.09%	49.87%	*	80.88%	*
		FFI - Pain - Placebo	*	*	-574.22%	-5473.77%	*	72.28%	*
		FFI - Disability - NSAID group	*	*	30.23%	44.28%	*	81.05%	*
		FFI - Disability - Placebo	*	*	16.60%	45.66%	*	71.89%	*
Manual Therapy	Ajimsha et al	Total FFI - Myofascial Release	*	*	72.40%	*	60.63%	*	*
		Total FFI - Control	*	*	7.38%	*	2.00%	*	*
Taping	Sankhe et al	FFI - UST + Calcaneal Taping + PT Treatment	69.03%	*	*	*	*	*	*
		FFI - UST + Low Dye Taping + PT Treatment	75.93%	*	*	*	*	*	*
	Tsai et al	FFI - Ultrasound Thermotherapy + Low Frequency Electrotherapy	6.00%	*	*	*	*	*	*
		FFI - Kinesiology Taping + Ultrasound Thermotherapy + Low Frequency Electrotherapy	43.98%	*	*	*	*	*	*
		Total FFI							
CFO	Baldassin et al	mFFI - Prefabricated Orthoses	*	*	36.72%	42.12%	*	*	*
		mFFI - Customized Orthoses	*	*	43.12%	52.98%	*	*	*

\* FFI was not taken at this time point in the study

Table 3. Percent changes in FFI score for different treatment modalities based on data collected from individual studies

generally longer follow-up, and showed a significant improvement in VAS at six weeks.<sup>17</sup> At eight weeks, LLLT showed a greater decrease in VAS<sup>5</sup> compared to the DiGiovanni study, and similar results to the Kamonseki study. Although no LLLT studies reported values for a follow-up at twelve weeks, they show increased efficacy at eight weeks<sup>5</sup> and six months<sup>7</sup> compared to stretching.<sup>13</sup> Similarly, at two years, stretching<sup>12</sup> showed less of a VAS decrease than LLLT at one year.<sup>7</sup> One of the limitations of the DiGiovanni study is its lack of a control group, which makes it difficult to ascertain whether their treatment has definitively resulted in the reduction of plantar heel pain. Radford’s study only measured pain on first step, which may have yielded different results than a VAS for pain at its worst. Based on these comparisons, LLLT shows

promise as having more of an efficacy than stretching in the immediate and long term treatment of plantar fasciitis.<sup>11,12,14</sup>

### Taping versus LLLT

The studies conducted by Radford et al., Hyland et al., Sankhe et al., and Tsai et al. that evaluated the efficacy of taping executed over one week. Jastifer et al. demonstrated an improvement of 39.68% in VAS at the two-week follow-up; which was less of a percent improvement compared to the studies.<sup>6,15,16,18</sup> Immediate improvement following LLLT compared to low-dye taping, calcaneal taping, and kinesiotaping was not observed. The Radford et al., Hyland et al., Sankhe et al., and Tsai et al. studies did not follow up with patients past one week. The study from Park et al. at six weeks did have a greater percent improvement compared to the



two week follow up percent change of Jastifer et al. This difference in improvement could be due to the fact that LLLT might require more time to reach its full efficacy potential. Taping displays an immediate improvement in treating plantar fasciitis while LLLT may have a lower immediate impact that increases over a year. Kiritsi et al. states that the development of plantar fasciitis is thought to have a mechanical origin, with mechanical overload as a main factor. In the Radford study it is thought that supportive taping reduces strain on the plantar fascia, a mechanical solution. Taping most likely has an immediate impact on the mechanics of the foot while the results from LLLT most likely take longer to have an effect. As both taping and LLLT are modalities that need to be applied by the practitioner, perhaps they can be used in combination for effective patient treatment.<sup>6,7,15,16,17,18</sup>

### ***Manual therapy versus LLLT***

Myofascial release as a manual therapy modality for plantar fasciitis has been shown to significantly improve plantar heel pain based on the Foot Function Index. Results reported by Ajimsha et al. confirm a greater change in FFI at four weeks following manual therapy than LLLT at two weeks<sup>7</sup> and at eight weeks.<sup>5</sup> However, the same improvement can be noted between manual therapy and LLLT at twelve weeks and six months, respectively. Manual therapy confers significant initial improvement in plantar heel pain, but for long-term management, LLLT is just as efficacious.<sup>20</sup>

### ***Custom Foot Orthoses versus LLLT***

Custom foot orthoses have been shown to reduce strain in the plantar fascia by providing medial arch support which relieves pain while standing and walking. The study conducted by Baldassin et al. on the effects of custom and prefabricated foot orthoses showed a higher percent increase in FFI at eight weeks than the LLLT used by Macias et al. at eight weeks. This suggests that foot orthoses, both custom and prefabricated, are more effective for plantar fasciitis than LLLT. Baldassin et al. included participants clinically diagnosed with plantar fasciitis while the Macias et al. study included participants with heel pain unresponsive to conservative care. As these two diagnoses can be clinically different from each other, it is difficult to directly compare the outcomes of each study.<sup>5,20</sup>

### ***ESWT versus LLLT***

It has been indicated that energy from ESWT induces hyperemia, neovascularization, and regeneration of tendon tissue which is useful in treating chronic inflammatory and degenerative processes.<sup>1</sup> A reduction in pain score for both treatment modalities showed significant changes at the follow-up visit. Higher energy ESWT requires local anesthesia due to the pain associated with the high energy shock waves<sup>21</sup>, whereas low energy ESWT does not require local anesthesia. Efficacy might be reduced following local anesthesia but it might be a positive trade off if there is an overall reduction in pain.<sup>1</sup> Gerdesmeyer et al. also highlighted

the importance of placement of the shock waves, radial versus focused. Focused shock waves being the most effective at penetrating a deeper degree of tissue. The studies implicate that treatment of plantar fasciitis should be high energy ESWT for a deeper specific target to better reduce heel pain while it was observed that LLLT did not have any pain or adverse reaction associated with treatment.<sup>2,7</sup> LLLT was recommended as an alternative or an adjunct therapy for plantar fasciitis by Jastifer et al. Although both modalities are fairly novel, neither one currently has standard of care guidelines for dose, exposure time, or number of sessions recommended. ESWT is a significant but not clinically relevant treatment. Studies associate higher energy ESWT with better outcomes despite the possibility of local anesthesia lowering the efficacy of treatment. The current studies implicate LLLT is relatively safe, does not induce pain, or have any adverse reactions.<sup>5,7</sup>

## CONCLUSION

This review finds that LLLT could be an effective treatment modality in treating acute and chronic plantar fasciitis based on the results of the studies done by Jastifer et al., Macias et al., and Kiritsi et al. Other modalities also led to a significant decrease in heel pain compared to their placebo groups. However, when comparing the percent changes of the VAS or FFI scales of each modality to LLLT, there is evidence suggesting that LLLT would only be more effective than stretching and ESWT.

This is not to say that LLLT does not have advantages over other modalities, such as low-dye taping. For example, LLLT does not require the use of local anesthesia as in ESWT due to the pain experienced from the shock waves. In addition, LLLT is not reliant on patient compliance nor have there been any known side effects to the treatment itself, including pain.<sup>7</sup> Lastly, the studies evaluating LLLT consisted of participants with chronic plantar fasciitis and heel pain greater than six months, while the studies that evaluated the other modalities did not identify the diagnosis of heel pain as acute or chronic. This could be a possible reason the results comparing LLLT and the traditional conservative treatments could not demonstrate a significant difference in decreased heel pain. Therefore, LLLT could be an effective alternative when currently accepted conservative treatment modalities are contraindicated.

This review had a few limitations worth addressing. Since ESWT and LLLT are newly emerging treatments, there are not many studies available that compare them to other accepted conservative treatments. Another limitation was that some studies did not have similar times for post treatment follow-ups. As a result, when one modality had a measurement taken at two weeks and another modality measured at six weeks, we could not definitively say if there is correlation between the studies. Although the authors of this review tried to fundamentally compare studies with similar demographics such as sample size,

similar validated tools of measurements, and post treatment follow up periods, differences were unavoidable due to the limited number of published studies. In addition, the VAS score is a subjective measure, which could result in discrepancies as participants' pain tolerance levels vary. The comparisons made in this review were abstract and more research must be done to validate the efficacy of LLLT in comparison to traditional conservative treatments.

## AUTHORS' CONTRIBUTIONS

All authors contributed equally to the literature review and editing of the final manuscript.

## STATEMENT OF COMPETING INTERESTS

The authors declare that they have no competing interest.

## REFERENCES

1. Gollwitzer H, Saxena A, DiDomenico LA, Galli L, Bouche RT, Camiear DS, Fullem B, Vester JC, Horn C, Banke IJ, Burgkart R, Gerdesmeyer L. Clinically relevant effectiveness of focused extracorporeal shock wave therapy in the treatment of chronic plantar fasciitis. *The Journal of Bone and Joint Surgery*. 2015; 97:701-708.
2. Gerdesmeyer L, Frey C, Vester J, Maier M, Weil Jr L, Weil Sr L, Russlies M, Stienstra J, Scurran B, Fedder K, Diehl P, Lohrer H, Henne M, Gollwitzer H. Radial extracorporeal shock wave therapy is safe and effective in the treatment of chronic recalcitrant plantar fasciitis: results of a confirmatory randomized placebo-controlled multicenter study. *The American Journal of Sports Medicine*. 2008; 36(11): 2100-2109.
3. Dizon JN, Gonzalez-suarez C, Zamora MT, Gambito ED. Effectiveness of extracorporeal shock wave therapy in chronic plantar fasciitis: a meta-analysis. *Am J Phys Med Rehabil*. 2013; 92(7):606-20.
4. Kiritsi O, Tsitas K, Malliaropoulos N, Mikroulis G. Ultrasonographic evaluation of plantar fasciitis after low-level laser therapy: results of a double-blind, randomized, placebo-controlled trial. *Lasers Med Sci*. 2010;25(2):275-81.
5. Macias MD, Coughlin MJ, Zang K, Stevens FR, Jastifer JR, Doty JF. Low-level laser therapy at 635 nm for treatment of chronic plantar fasciitis: a placebo-controlled, randomized study. *Journal of Foot & Ankle Surgery*. 2015; 54:768-772.
6. Hyland MR, Webber-gaffney A, Cohen L, Lichtman PT. Randomized controlled trial of calcaneal taping, sham taping, and plantar fascia stretching for the short-term management of plantar heel pain. *J Orthop Sports Phys Ther*. 2006; 36(6): 364-71.
7. Jastifer JR, Catena F, Doty JF, Stevens F, Coughlin MJ. Low-level laser therapy for the treatment of chronic plantar fasciitis: a prospective study. *Foot & Ankle International*. 2014; 35(6): 566-571.

8. Cleland JA, Abbott JH, Kidd MO, et al. Manual physical therapy and exercise versus electrophysical agents and exercise in the management of plantar heel pain: a multicenter randomized clinical trial. *J Orthop Sports Phys Ther.* 2009; 39(8):573-85.
9. Lemont H, Ammirati KM, Usen N. Plantar fasciitis: a degenerative process (fasciosis) without inflammation. *J Am Podiatr Med Assoc.* 2003;93(3):234-7.
10. Donley BG, Moore T, Sferra J, Gozdanovic J, Smith R. The efficacy of oral nonsteroidal anti-inflammatory medication (NSAID) in the treatment of plantar fasciitis: a randomized, prospective, placebo-controlled study. *Foot Ankle Int.* 2007; 28(1):20-3.
11. Radford JA, Landorf KB, Buchbinder R, Cook C. Effectiveness of calf muscle stretching for the short-term treatment of plantar heel pain: a randomised trial. *BMC Musculoskeletal Disord.* 2007; 8:36.
12. Digiovanni BF, Nawoczenski DA, Malay DP, et al. Plantar fascia-specific stretching exercise improves outcomes in patients with chronic plantar fasciitis. A prospective clinical trial with two-year follow-up. *J Bone Joint Surg Am.* 2006;88(8):1775-81.
13. Sharma NK, Loudon JK. Static progressive stretch brace as a treatment of pain and functional limitations associated with plantar fasciitis: a pilot study. *Foot Ankle Spec.* 2010; 3(3):117-24.
14. Kamonseki DH, Gonçalves GA, Yi LC, Júnior IL. Effect of stretching with and without muscle strengthening exercises for the foot and hip in patients with plantar fasciitis: a randomized controlled single-blind clinical trial. *Man Ther.* 2016; 23:76-82.
15. Radford JA, Landorf KB, Buchbinder R, Cook C. Effectiveness of low-Dye taping for the short term treatment of plantar heel pain: a randomised trial. *BMC Musculoskeletal Disorders.* 2006; 7:64
16. Sankhe AJ, Shukla G, Rathod VJ, Alagesan J, Manickavasagam I, Kamalakannan M. The effect of calcaneal taping versus low dye taping in treating patients with plantar fasciitis: randomized clinical trial. *International Journal of Therapies and Rehabilitation Research.* 2016; 5:3
17. Park C, Lee S, Lim DY, Yi CW, Kim JH, Jeon C. Effects of the application of Low-Dye taping on the pain and stability of patients with plantar fasciitis. *J Phys Ther Sci.* 2015; 27(8): 2491-3.
18. Tsai CT, Chang WD, Lee JP. Effect of short term treatment with kinesiotaping for plantar fasciitis. *Journal of Musculoskeletal Pain.* 2010; 18(1);71-80.
19. Ajimsha MS, Binsu D, Chithra S. Effectiveness of myofascial release in the management of plantar heel pain: a randomized controlled trial. *Foot (Edinb).* 2014; 24(2):66-71.

20. Baldassin V, Gomemes CR, Beraldo PS. Effectiveness of prefabricated and customized foot orthoses made from low-cost foam for noncomplicated plantar fasciitis: a randomized controlled trial. *Arch Phys Med Rehabil.* 2009; 90(4): 701-706.
21. Metzner G, Dohnalek C, Aigner E. High-energy extracorporeal shock-wave therapy (ESWT) for the treatment of chronic plantar fasciitis. *Foot & Ankle International.* 2010; 31(9):790-796.
22. Piper S, Shearer HM, Côté P, et al. The effectiveness of soft-tissue therapy for the management of musculoskeletal disorders and injuries of the upper and lower extremities: A systematic review by the Ontario Protocol for Traffic Injury management (OPTIMa) collaboration. *Man Ther.* 2016;21:18-34.

# Surgical Management of a Malignant Marjolin's Ulcer: A Case Report

*Mai T. Pham, BS, Kevin Yee, BA, Gabrielle Lee, BA, Munjed S. Salem, DPM & Sharon R. Barlizo, DPM*

## Abstract

### Introduction

Marjolin's ulcer has been reported in the literature to progress from chronic non-healing wounds to squamous cell carcinomas (SCC). The etiology of these malignant ulcers includes chronic wounds, chronic inflammation, burns, radiation, osteomyelitis, pressure sores, repetitive trauma, surgical scars, bites, chronic fistulae, and/or venous stasis. Due to the rare incidence of Marjolin's ulcer, they are often misdiagnosed as non-healing wounds or verrucae.

**Study design:** Case Report

### Methods

A detailed medical history was obtained from the patient upon his presentation to clinic, and was reviewed for additional information regarding his current condition. Current literature on pathogenesis and treatment options of Marjolin's ulcer is also discussed along with this case report.

### Results

A 70-year-old diabetic male presented with a chronic raised wound on the right foot with an exposed flexor tendon that had been present for twenty years. The ulcer was initially diagnosed and treated as a verrucous lesion without improvement. A biopsy of the wound was performed, which confirmed the diagnosis of SCC. A radical resection of the Marjolin's ulcer with a partial 2<sup>nd</sup> and 3<sup>rd</sup> ray amputation was performed, due to the depth of the lesion. Literature has shown some patients remained tumor-free, some underwent recurrence of the lesion, and others experienced metastasis to regional lymph nodes.

### Conclusion

It is important to recognize and diagnose this condition as well as identify individuals at an increased risk of developing chronic wounds to prevent associated complications. Education on the prevalence and risk of chronic wounds can prompt proper intervention.

**Key Words:** Marjolin's ulcer, Squamous cell carcinoma, chronic lesions

*Levels of Evidence:* 4

## INTRODUCTION:

Marjolin's ulcer is a rare and aggressive transformation of chronic skin wounds into malignant lesions. Chronic wounds have multiple etiologies including burns, venous stasis, arterial insufficiency, lymphedema, weight-bearing areas, trauma, and osteomyelitis. Dating back to 1828, Jean-Nicholas Marjolin described four unique types of ulcers in literature as "ulcère verruqueux" but did not associate it to the chronicity of the wound nor the potential malignancy these wounds possessed.<sup>1</sup> It wasn't until 1903, when a surgery professor at Jefferson Medical College, John Chalmers DaCosta, reported two cases of malignant changes in chronic varicose ulcers of the leg.<sup>1</sup> DaCosta accredited Marjolin for his description of the verrucous lesions, henceforth called Marjolin's ulcers, and extended the definition to include malignancy arising from sinuses, scars, and chronic ulcers.<sup>1</sup>

Clinically, Marjolin's ulcer presents as two morphological types. The most common type is flat, indurated, and ulcerative while the less common type is the exophytic papillary type.<sup>2,3</sup> Marjolin's ulcers are commonly misdiagnosed as non-healing chronic wounds, verrucous warts, chronic venous stasis, or infected ulcerative lesions.<sup>3-5</sup> The diagnosis of Marjolin's ulcer is based on the patient's history, ulcer presentation, duration of ulcer, and is ultimately confirmed with a

punch biopsy to assess potential malignancy. Literature shows that these chronic lesions have a malignant transformation rate of 71% into squamous cell carcinoma (SCC), and less frequently into basal cell carcinoma, melanoma, sarcoma, SCC-melanoma, and other rare neoplasms.<sup>2</sup> Occurrence of these lesions are commonly seen in men, with the classic triad of nodule formation, induration, and ulceration.<sup>2,3</sup> Marjolin's ulcers have a predilection for the lower extremity.<sup>1,2,4</sup>

The mainstay of treatment is surgical resection of the lesion, but alternative treatments such as amputation proximal to the ulcer, cryosurgery, Mohs surgery, carbon dioxide laser, intralesional interferon, photodynamic therapy, radiotherapy, lymph node dissection, and heat therapy have been introduced.<sup>2,3,6-9</sup> SCC is aggressive in nature and can spread to other areas such as the lymph nodes, worsening the prognosis. MRI or Positron Emission Tomography-Computed Tomography have been indicated in recent literature to evaluate regional lymph nodes for possible signs of metastasis.<sup>2,5,7</sup>

In this case report, we discuss a patient who presented to the podiatry clinic with an ulcerative lesion on the plantar aspect of the right foot, which had been present for many years and was initially diagnosed as a plantar wart.

## CASE REPORT:

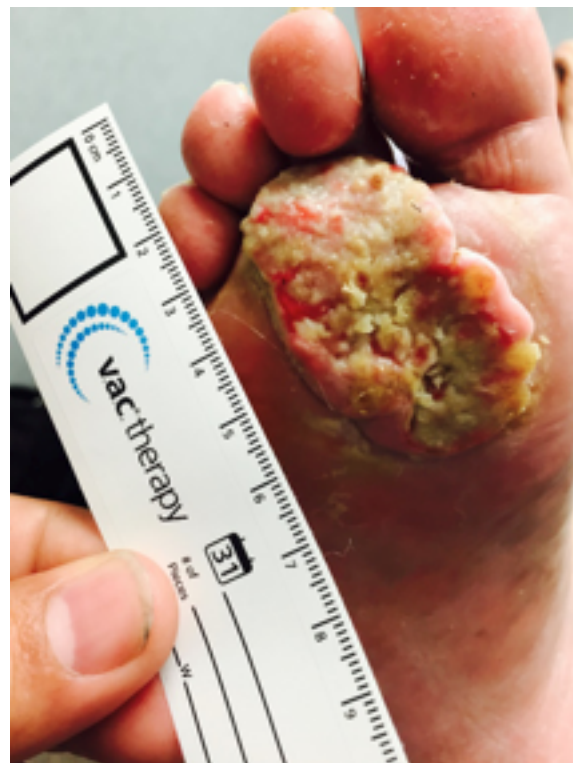A 70-year-old Caucasian diabetic male, presented to clinic with chief complaint of a non-resolving wound on the plantar aspect of his right foot that was painful upon ambulation. The patient claimed the wound has been present for twenty years and has progressively worsened over the past two years. The wound was previously diagnosed and treated as a plantar wart without any improvement. The patient cleaned the lesion daily and dressed the wound with a dry sterile dressing. Previous medical history included controlled diabetes mellitus type II, oropharyngeal cancer with no signs of recurrence, gastroesophageal reflux disease, appendicitis, and arthritis.

Notable findings on physical examination included diminished epicritic sensation, Semmes Weinstein Monofilament test 7/10 bilaterally, and diminished vibratory sensation in the forefoot/rearfoot bilaterally. Upon initial presentation, the wound was noted to be on the plantar aspect of the right foot submetatarsal 2 head extending proximally with the wound measuring approximately 6.5cm x 3.0cm x 0.5cm (Figure 1). The wound appeared to have a cauliflower appearance but did not probe, track or show signs of infection. A biopsy of the lesion was performed that day and the patient was informed that due to the suspicious nature of the wound, it might require surgical intervention but that definitive treatment would depend

upon the results of the biopsy obtained.

Ten days following the initial visit, the pathology report of the right plantar lesion biopsy indicated diagnosis of well-differentiated squamous cell carcinoma with lesional cells extending to the superficial and deep peripheral surfaces. X-rays, which were taken at the time of return visit and reviewed with patient, showed possible involvement of second metatarsophalangeal joint and metatarsal shaft.

A radical resection was performed which included full excision of the lesion with partial second and third ray amputation, leaving 1.0 cm clear skin margins. The pathology results of the flexor tendon tissue revealed



**Figure 1:** Clinical view of the patient's Marjolin's ulcer on plantar aspect of right foot.



findings of squamous cell carcinoma with tumor tissue penetrating deep to level of flexor tendon sheath of the second and third rays of the right foot. The intraoperative decision to perform a partial resection of the right second and third metatarsals was necessary to remove all signs of malignancy. Bone and soft tissue along with SCC were sent to pathology for both frozen and permanent section. Pathology results showed that the histology grading of the SCC specimen was Grade 1-2 and moderately differentiated. The surgical area was left open and allowed to heal through secondary intention.

## DISCUSSION:

Marjolin's ulcer is a rare but aggressive cutaneous malignancy that requires early detection for better prognosis. It most commonly arises from burns but could also be caused by chronic wounds, chronic inflammation, radiation, osteomyelitis, pressure sores, repetitive trauma, surgical scars, bites, chronic fistulae, and/or venous stasis.<sup>1,2,4,8</sup> The pathogenesis of Marjolin's ulcer remains under debate and more studies are needed to determine the causation of these malignant transformations. However, it is important to properly manage chronic wounds to decrease the vulnerability of the lesion site and avoid negative effects on normal daily activities. Marjolin's ulcer accounts for 0.05-2% of all SCCs in the lower extremity, with the plantar foot being the most

common site of primary skin lesion.<sup>1-3,9,10</sup> SCC are locally aggressive and can metastasize to regional lymph nodes leading to further complications.

Clinical signs that may suggest a malignant wound include; presence of a non-healing wound for greater than 3 months, rolled or pearly wound borders, bleeding on contact, increasing in size, foul-smelling pus, and pain.<sup>2-4,11</sup> Chronic ulcers should be carefully monitored for these signs to prevent the progression to a malignant lesion.

The latency period between the time of initial wound to the time of malignancy ranges from 10 and 75 years.<sup>1-4,6</sup> This latency period is inversely related to the age of the patient; younger patients tend to have a longer latency period, whereas older patients tend to progress to Marjolin's ulcer within a shorter timeframe.<sup>6,10</sup> In a recent article by Sinha et al, a study was performed to differentiate Marjolin's ulcers from typical SCCs. It was shown that genetic properties of epithelial cells and the transcriptional process in Marjolin's ulcers differed from SCCs, which suggests a possible mechanism behind these transformations.

Proper diagnostic testing is required to confirm the diagnosis of Marjolin's ulcer. Biopsies are the primary diagnostic tool, followed by PET, CT, or MRI to evaluate the extent of lymph node involvement for the presence of SCC.<sup>2</sup> Once the patient

has been diagnosed with a Marjolin’s ulcer, 20-36% of the patients have lymph node involvement.<sup>2,3</sup> As the malignancy metastasizes to regional lymph nodes, the 3-year survival rate drops significantly to 35%.<sup>2,3,7,9,11</sup> Thus it is important to recognize the manifestations of Marjolin’s ulcer arising from non-healing lesions and preventing further metastasis. The overall mortality rate was 34% with the average survival of 2 years after diagnosis, 16% showed local recurrence, and 14% manifested distant metastases.<sup>9</sup>

The prognosis of Marjolin’s ulcer can be determined based on the regional lymph node involvement of the lesion and the histological grading system.

The histology grade is categorized into Grade I: more than 75% of the cells are differentiated; Grade II: 25-75% of the cells are differentiated; Grade III: less than 25% of the cells are differentiated (Table 1).<sup>1-3</sup>

The grading system is based on the extent of cell differentiation and the more differentiated the lesions are, the better the prognosis.

The treatment modalities include extended resection with skin grafting or skin flap repair, lymph node

dissections, radiotherapy, heat therapy, and amputation as a last resort.<sup>7,9,12-14</sup> However, there is no definitive treatment protocol regarding the extensiveness and degree of resection and radiotherapy.<sup>9</sup>

## CONCLUSION:

Marjolin’s ulcer can be a life-threatening lesion that demonstrates predominance in the lower extremity. When a wound has been present for greater than 3 months remains unchanged or has become progressively worse, it should be biopsied and carefully evaluated for malignancy. If the biopsy results are positive for malignant transformation, a secondary diagnostic test such as a PET, CT, or MRI scan should be done to evaluate possible metastasis to regional lymph nodes. The standard treatment for a Marjolin’s ulcer is aggressive resection of the affected area and involved lymph nodes. Appropriate treatment and prevention of chronic lesions, especially in patients with a high risk of developing non-healing wounds, could reduce the incidence of Marjolin’s ulcer. Proper education on early detection of malignant transformation is crucial to

Grading	Degree of Cell Differentiation
Grade I	> 75%
Grade II	25-75%
Grade III	< 25%

**Table 1.** Histological Grading System.<sup>1-3</sup>

limb salvage and better prognosis. Further research on prevention strategies and treatment interventions are needed to provide effective treatment of these malignant transformations.

## AUTHORS' CONTRIBUTIONS:

All authors participated equally in the design of the study, performed literature review, and evaluated abstracts. Drs. Munjed Salem and Sharon Barlizo supplemented the research and providing information regarding the medical history of this patient. All authors drafted, edited, and agreed upon the manuscript.

## STATEMENT OF COMPETING INTERESTS:

The authors declare that they have no competing interest.

## ACKNOWLEDGEMENTS:

Special acknowledge would like to be given to Dr. Munjed Salem, DPM for giving permission to write this case report and to Dr. Sharon Barlizo, DPM for her guidance and knowledge of wound care. The authors would like to acknowledge Chesapeake General Hospital where the procedure was performed.

## REFERENCES:

1. Fazeli, M., Lebaschi, A., Hajirostam, M., Keramati, M. Marjolin's Ulcer: Clinical and pathological features of 83 cases and review of literature. *Medical Journal of the Islamic Republic of Iran* 2013; 27(4): 215-224.
2. Saaiq, M., Ashraf, B. Marjolin's ulcers in the post-burned lesions and scars. *World Journal of Clinical Cases* 2014; 2(10): 507-514.
3. Pekarek, B., Buck, S., Osher, L. A Comprehensive Review on Marjolin's Ulcers: Diagnosis and Treatment. *Journal of the American College of Certified Wound Specialists* 2011; 3: 60-64.
4. Chalya, P., Mabula, J., Rambau, P., Mchembe, M., Kahima, K., Chandika, A., Giiti, G., Masalu, N., Ssentongo, R., Gilyoma, J. Marjolin's ulcers at a university teaching hospital in Northwestern Tanzania: a retrospective review of 56 cases. *World Journal of Surgical Oncology* 2012; 10(38).
5. Berhard, K., Morgan, K., Kruse, D., Stone, P. Rare Presentation of a Marjolin's Ulcer Secondary to a Post-Traumatic Injury. *The Journal of Foot and Ankle Surgery* 2016. 55(5).
6. Yu, N., Long, X., Lujan-Hernandez, J., Hassan, K., Bai, M., Wang, Y., Wang, X., Zhao, R. Marjolin's Ulcer: A Preventable Malignancy Arising from Scars. *World Journal of Surgical Oncology* 2013; 11(313).

7. Shen, R., Zhang, F., Du, Y., Liang, W., Xu, L., Du, X., Chen, C., Chen, X. Clinical characteristics and therapeutic analysis of 51 patients with Marjolin's ulcers. *Experimental and Therapeutic medicine* 2015; 10: 1364-1374.
8. Danks, R., Schnell, L. Massive Marjolin's Ulcer in a Burn Graft Site 46 years later. *Journal of Burn Care & Research* 2009; 30(3): 533-535.
9. Bloemsma, G., Lapid, O. Marjolin's ulcer in an Amputation Stump. *Journal of Burn Care & Research* 2008; 29(6): 1001-1003.
10. Khan, K., Giannon, A., Mehrabi, E., Khan, A., Giannone, R. Marjolin's Ulcer Complicating a Pressure Sore: The Clock is Ticking. *American Journal of Case Reports* 2016; 17: 111-114
11. Sinha, S., Su, S., Workentine, M., Agabalyan, N., Cheng, M., Gabriel, V., Biernaskis, J. Transcriptional Analysis Reveals Evidence of Chronically Impeded ECM Turnover and Epithelium-to-Mesenchyme Transition in Scar Tissue Giving Rise to Marjolin's Ulcer. *Journal of Burn Care & Research* 2017; 38: e14-e22.
12. Choi, J., Bae, Y., Nam, S., Bae, S. Impact of Disturbed Wound Healing After Surgery on the Prognosis of Marjolin's Ulcer. *Archives of Plastic Surgery* 2013; 40: 198-202
13. Altunay, I., Cerman, A., Sakiz, D., Ates, B. Marjolin's Ulcer Presenting with In-Transit Metastases: A Case Report and Literature Review. *Ann Dermatol* 2015; 27(4): 442-445.
14. Olaitan, P., Ogbonnaya, I. Marjolin's Ulcer of the Thigh Two Years After Burn. *Annals of Burns and Fire Disasters* 2007; 30(3): 159-160

---

The general structure and the texts, photos, and images which comprise this journal are the property of the New York College of Podiatric Medicine PMR. Any reproduction, total or partial, and any representation of the substantial content of this journal or one or more of its components, by any process whatsoever, without the expressed authorization of the PMR editorial staff, is prohibited and constitutes an infringement sanctioned by articles L.335-2 et seq. of the Intellectual Property Code.

The information, pictograms, photographs, images, texts, graphs, and other documents in this journal are protected by the laws of industrial and/or intellectual property, whether the New York College of Podiatric Medicine PMR is their owner, or whether it has been authorized to reproduce and represent them.

Therefore, any reproduction, representation, adaptation, translation and/or modification, partial or total, or transfer of information is prohibited.

Hard copies for private use of these various items protected by law is authorized pursuant to article L122-5 of the Intellectual Property Code. Their partial or total reproduction without prior agreement in writing is strictly prohibited. To obtain clearance to reproduce, reference, or utilize any portion of this journal, image or text, please contact the Editor-in-Chiefs: [skim2018@nycpm.edu](mailto:skim2018@nycpm.edu) or [dkhakov2018@nycpm.edu](mailto:dkhakov2018@nycpm.edu)

\*The design of this journal was conceived by J. Adrian Wright, AM and modified by Diltaj Singh, BS ([DSingh2019@nycpm.edu](mailto:DSingh2019@nycpm.edu))

---